Asian Journal of Periodontics and Orthodontics
2026, Volume 6, Page No: 114-125
Copyright CC BY-NC-SA 4.0
Available online at: www.tsdp.net

ISSN: 3062-3499

Original Article

Defining Functional Success in Periodontal Regeneration: An Original Conceptual Framework Integrating Attachment Reconstruction, Tooth Maintainability, and the Biological Demands of Subsequent Rehabilitation

Helena Voss[1]*, Erik Sandberg[2], Karin Åkesson[3]

[1]Department of Periodontology, Uppsala University, Uppsala, Sweden.
[2]Department of Periodontology, Lund University, Lund, Sweden.
[3]Department of Oral Health, University of Gothenburg, Gothenburg, Sweden.

***E-mail** ✉ helena.voss@uu.se

Received: 14 July 2026; **Revised:** 17 August 2026; **Accepted:** 21 August 2026

ABSTRACT

Periodontal regenerative treatment is commonly judged through changes in probing depth, clinical attachment level, radiographic defect fill, or combinations of these endpoints. These measures are clinically important, but none alone establishes that a treated tooth has achieved a functionally successful regenerative state. A tooth may demonstrate substantial attachment improvement yet remain difficult to maintain, biomechanically unstable, poorly positioned for rehabilitation, or unsuitable for subsequent orthodontic or prosthetic demands. Conversely, a tooth that does not satisfy an idealized biological definition of complete regeneration may remain clinically stable and functionally valuable for many years. This article develops an evidence-grounded conceptual framework that distinguishes three related but non-equivalent dimensions of functional regenerative success: attachment reconstruction, tooth maintainability, and rehabilitation suitability. It further examines how defect morphology, wound stability, host characteristics, treatment strategy, mobility, loading, patient-reported outcomes, and subsequent interdisciplinary care alter interpretation of those dimensions. The framework treats discordance among biological, clinical, and rehabilitative outcomes as clinically meaningful rather than as measurement noise. Functional success is therefore proposed as a multidimensional judgment about whether regenerated periodontal support is biologically credible, maintainable over time, and sufficient for the demands that will subsequently be placed on the tooth. The framework is intended to sharpen interpretation of regenerative outcomes without converting observational associations, surrogate measures, or treatment-specific results into universal thresholds.

Keywords: Periodontal regeneration, Intrabony defects, Clinical attachment, Tooth maintainability, Rehabilitation suitability, Periodontal stability

How to Cite This Article: Voss H, Sandberg E, Åkesson K. Defining Functional Success in Periodontal Regeneration: An Original Conceptual Framework Integrating Attachment Reconstruction, Tooth Maintainability, and the Biological Demands of Subsequent Rehabilitation. Asian J Periodont Orthodont. 2026;6(1):114-125. https://doi.org/10.51847/QXfpwR7ioI

Introduction

Modern periodontal classification recognizes that disease severity cannot be represented adequately by attachment loss alone. Staging incorporates the extent of periodontal destruction together with complexity factors that may influence treatment and long-term management, including tooth loss, mobility, masticatory dysfunction, and the difficulty of rehabilitating the dentition [1]. The contemporary case definition of periodontitis similarly treats attachment destruction as part of a broader disease construct rather than as an isolated measurement [2]. These developments have important implications for regenerative therapy. If periodontal disease is understood partly through its consequences for tooth function and treatment complexity, the success of regeneration should not be reduced to the numerical improvement of a single periodontal variable.

© 2026 Asian Journal of Periodontics and Orthodontics

That problem becomes especially apparent in Stage IV periodontitis, where control of inflammation may need to be followed by tooth stabilization, orthodontic correction, reconstruction of posterior support, prosthetic rehabilitation, or combinations of these interventions. Current clinical guidance therefore places management of severe periodontitis within an explicitly interdisciplinary and function-oriented treatment pathway [3]. Regenerative procedures nevertheless remain embedded within the broader stepwise management of periodontal disease and are indicated only after appropriate control of etiologic factors and consideration of site-specific anatomy and patient-level conditions [4]. Regeneration is therefore neither an isolated surgical event nor an automatically sufficient endpoint.

The conventional regenerative literature understandably emphasizes probing-depth reduction, clinical attachment-level gain, radiographic bone change, and tooth retention. These outcomes are indispensable because they describe clinically observable consequences of therapy. Yet they answer different questions. Attachment gain may indicate improved periodontal support without identifying the exact tissue architecture responsible for that gain. Radiographic fill may indicate mineralized change without demonstrating reconstruction of the entire periodontal attachment apparatus. Tooth retention confirms that extraction was avoided, but a retained tooth may still require intensive maintenance, stabilization, positional correction, or restrictions on subsequent loading.

The central problem addressed here is consequently one of functional interpretation. A regenerated site should not be considered successful merely because one biological or clinical surrogate improves. The more demanding question is whether the resulting tooth can be maintained, integrated into the dentition, and used safely within the subsequent therapeutic plan. This article develops that argument through three linked dimensions: attachment reconstruction, tooth maintainability, and rehabilitation suitability. The dimensions are not proposed as interchangeable scores or as a new numerical index. They are analytical domains whose agreement or disagreement can clarify what a reported regenerative result actually means.

The framework is deliberately bounded. It does not assume that histologic regeneration can be inferred routinely from clinical measurements, that a specific defect morphology guarantees success, that mobility necessarily requires splinting, or that orthodontic or prosthetic treatment becomes appropriate after a fixed interval. Instead, it asks what level of biological reconstruction has been achieved or can reasonably be inferred, whether the resulting periodontal condition is maintainable over time, and whether that state is sufficient for the functional demands expected during subsequent rehabilitation.

Conceptual foundations of periodontal regenerative success

The first distinction is between periodontal repair and periodontal regeneration. Clinically favorable healing may occur through tissue arrangements that improve probing depth or attachment measurements without restoring the complete architecture of alveolar bone, periodontal ligament, and root-surface attachment characteristic of true regeneration. Root-surface biology and wound-healing conditions influence the potential for new periodontal attachment, but commonly used clinical measurements cannot identify histologic reconstruction directly [5]. Functional interpretation must therefore begin by acknowledging that an improved clinical attachment level is evidence of a favorable clinical result, not automatic proof that the original attachment apparatus has been recreated.

This distinction does not diminish the value of clinical regenerative therapy. Systematic evidence shows that regenerative approaches can provide additional attachment gain and probing-depth improvement compared with access-flap surgery in appropriately selected intrabony defects [6, 7]. The clinical significance of these gains is strengthened when they remain stable over time, but their interpretation still depends on the endpoint under consideration. A biological question asks what tissues have been reconstructed. A clinical question asks whether the periodontal condition is healthier and more stable. A functional question asks whether the treated tooth can subsequently meet the demands placed on it.

These levels can diverge. A site may show clinically meaningful attachment gain without proof of complete histologic regeneration. Conversely, a technically successful regenerative procedure can lose practical value if postoperative complications, persistent deep probing depths, inadequate plaque control, wound instability, recurrent inflammation, or other maintenance problems compromise the treated site. Complications related to regenerative periodontal surgery therefore matter not simply because they affect short-term healing but because they may interrupt the transition from an intended regenerative intervention to a maintainable periodontal condition [8].

Biologic agents add a further distinction. Growth factors and related regenerative technologies can influence cell migration, proliferation, differentiation,

angiogenesis, extracellular-matrix formation, and hard- and soft-tissue healing. Such mechanisms strengthen the biological rationale for regenerative treatment, but mechanistic plausibility alone does not establish long-term tooth function [9]. The presence of a biologically active regenerative stimulus should thus be interpreted as one component of the regenerative process rather than as a proxy for eventual functional success.

A useful hierarchy therefore begins with four different propositions. Repair indicates healing without requiring reconstruction of the original periodontal apparatus. Attachment improvement describes a clinical change detectable through periodontal measurements. Regeneration refers to reconstruction of the periodontal supporting tissues to the extent supportable by biological or histologic evidence. Functional success asks whether the resulting state is sufficiently stable, maintainable, and rehabilitation-compatible to justify retaining and using the tooth. The propositions may overlap, but none can simply substitute for another.

This hierarchy also changes how treatment failure should be understood. A small residual defect after clinically successful therapy is not automatically failure if the tooth is stable, maintainable, symptomatically acceptable, and suitable for planned rehabilitation. Conversely, impressive short-term attachment gain may represent an incomplete success if the treated site remains repeatedly inflamed, inaccessible for maintenance, mechanically unstable, or unable to tolerate the next phase of care. Functional evaluation therefore requires the biological result to be interpreted within the clinical life of the tooth rather than at the end of the surgical episode.

The distinction can be summarized without converting the framework into a numerical hierarchy.

Table 1. What favorable periodontal regenerative endpoints establish—and what remains unresolved before functional success can be inferred

Regenerative observation	What the observation can legitimately support	What remains unresolved	Functional consequence requiring separate judgment
Reduced probing depth	Improved clinical pocket condition and potentially easier maintenance	Exact nature of tissue attachment and long-term recurrence risk	Whether the site remains cleansable and stable during maintenance
Clinical attachment gain	Increased clinically measurable periodontal support	Histologic composition of the attachment and resistance to future loading	Whether regained support is sufficient for tooth retention and rehabilitation
Radiographic defect fill	Mineralized change within a previously deficient area	Complete reconstruction of periodontal ligament and cemental attachment	Whether radiographic improvement corresponds to stable functional support
Uneventful wound healing	Successful early postoperative tissue integration	Long-term stability, recurrence, and mechanical competence	Whether early healing develops into a maintainable periodontal state
Tooth retention	Avoidance of extraction during the observed interval	Maintenance burden, mobility, positional problems, restorative feasibility	Whether the retained tooth remains worth preserving as a functional unit
Biological response to regenerative material	Plausibility that regenerative mechanisms were engaged	Magnitude, durability, and patient-level functional effect	Whether biological activity translates into clinically useful support
Stable clinical result over repeated maintenance	Durability of observed periodontal improvement	Suitability for subsequent orthodontic, occlusal, or prosthetic demands	Whether the tooth can participate reliably in the planned rehabilitation

Table 1 therefore separates observations that are often treated as synonyms for success. None should be discarded, but their interpretive limits must remain visible. Functional success begins only when the biological and clinical consequences of treatment are connected to the future requirements of the tooth.

The three dimensions of functional success

Attachment reconstruction

The first dimension is the degree to which periodontal support has been reconstructed in a clinically meaningful manner. This dimension cannot be interpreted independently of baseline defect anatomy. Intrabony-defect depth, angle, number of remaining bony walls, and related morphologic characteristics influence healing after regenerative treatment [10]. Defect morphology should therefore be understood as a modifier of the probability and magnitude of response

rather than as a binary criterion separating regenerable from non-regenerable sites.

Attachment reconstruction encompasses more than change in clinical attachment level. It includes the relationship between attachment gain, residual probing depth, defect resolution, radiographic change, gingival position, and the biological credibility of the observed response. These measures should be interpreted together while respecting their different evidentiary meanings. A favorable change in one domain cannot automatically compensate for persistent weakness in another.

Tooth maintainability

The second dimension is whether the regenerated site can remain stable under realistic long-term maintenance. Pocket resolution is particularly relevant because residual deep probing depths can remain biologically and clinically consequential even when attachment gain has occurred [11]. A treatment result that produces measurable attachment improvement but leaves a site repeatedly inflamed or difficult to instrument is functionally different from one that produces comparable attachment gain within a shallow, stable, maintainable environment.

Long-term regenerative studies reinforce this distinction. Teeth treated with regenerative procedures can remain in function over very extended follow-up periods, and durability can be demonstrated not only through periodontal measurements but through tooth retention and recurrence outcomes [12, 13]. These data are important because they move evaluation beyond the conventional 6- or 12-month endpoint. They do not, however, establish that every retained tooth has identical biological or functional quality.

The stability achieved after minimally invasive regenerative procedures likewise suggests that the long-term value of treatment depends on the interaction between the regenerated site, surgical design, maintenance environment, and patient behavior rather than solely on the placement of a regenerative material [14]. Cohort evidence on enamel-matrix-derivative therapy also indicates that favorable regenerative outcomes may remain clinically stable for prolonged periods in appropriately maintained patients [15]. Functional success therefore has an inherently temporal component: an outcome can appear satisfactory at one year yet prove inadequate if recurrent periodontal instability develops later.

Maintainability also includes the practical burden of preserving the result. A tooth requiring repeated complex intervention, inaccessible hygiene procedures, or recurrent treatment may differ functionally from a similarly retained tooth that remains stable with conventional supportive periodontal care. Long-term survival is therefore necessary but not sufficient. The pathway by which survival is achieved also matters.

Rehabilitation suitability

The third dimension asks whether the treated tooth is suitable for what comes next. Rehabilitation may include restoration of occlusal support, orthodontic correction of pathological migration, splinting, fixed prosthodontics, or incorporation of the tooth into a broader multidisciplinary treatment plan. A tooth can therefore be biologically improved and clinically maintainable yet remain unsuitable for the intended rehabilitation because of mobility, unfavorable position, insufficient structural prognosis, inadequate periodontal support, or anticipated loading demands.

Patient-centered evaluation further complicates this judgment. Regenerative periodontal therapy can affect discomfort, postoperative experience, quality of life, and economic burden, and these outcomes are not perfectly represented by periodontal measurements [16]. Patient-reported outcomes and patient-reported experiences should accordingly be treated as a distinct layer of treatment appraisal [17]. They do not replace biological or clinical endpoints, but they help determine whether preservation of the tooth produces a result that is acceptable and worthwhile from the patient's perspective.

These three dimensions are related without being substitutable. Excellent attachment reconstruction cannot compensate indefinitely for recurrent periodontal instability. Easy maintainability cannot by itself establish adequate support for an intended orthodontic or prosthetic load. Rehabilitation suitability cannot convert biologically unstable tissue into a successful regenerative outcome. Functional success instead requires sufficient performance across all three dimensions for the demands relevant to that particular tooth.

The clinical tests distinguishing the three dimensions are summarized in **Table 2**.

Table 2. Clinical tests that distinguish attachment reconstruction, maintainability, and rehabilitation suitability after periodontal regeneration

Functional-success domain	Principal question	Site-specific observations that inform the judgment	Time horizon required for interpretation	Example of a discordant outcome	Consequence for interpretation
Attachment reconstruction	Has periodontal support been meaningfully re-established?	Clinical attachment change, probing depth, radiographic defect change, defect morphology, gingival position	Early healing through established periodontal stability	Marked attachment gain with uncertain tissue architecture	Favorable clinical reconstruction without claiming histologic certainty
Residual periodontal environment	Is the treated site compatible with long-term health?	Residual probing depth, bleeding/inflammation, plaque access, local anatomy	Repeated maintenance visits	Attachment gain with a persistent deep bleeding pocket	Regenerative improvement but incomplete functional success
Longitudinal stability	Does improvement persist rather than regress?	Recurrence, attachment stability, tooth retention, additional treatment need	Multi-year	Good one-year result followed by recurrent breakdown	Short-term success cannot be treated as durable success
Maintenance burden	Can the result be preserved without disproportionate intervention?	Cleansability, supportive-care demands, accessibility, recurrent surgical need	Ongoing	Retained tooth requiring repeated complex therapy	Survival alone overstates practical success
Patient-centered value	Is preservation acceptable and meaningful to the patient?	Symptoms, postoperative burden, satisfaction, quality of life, cost	Short- and long-term	Strong clinical result with unacceptable burden or dissatisfaction	Biological success and patient value must be reported separately
Rehabilitation suitability	Can the tooth safely participate in the intended next phase of treatment?	Mobility, position, periodontal support, occlusal demands, restorative feasibility, anticipated orthodontic/prosthetic loading	After periodontal stabilization and during subsequent care	Stable periodontal pocket condition but insufficient support for planned loading	Maintainable tooth may still be rehabilitation-limited

The three-dimensional interpretation avoids declaring a tooth either “regenerated” or “failed” on the basis of a single measurement. It also creates the conditions for identifying discordant success, in which one dimension is favorable while another remains unresolved.

Integrating biological and clinical evidence

The three dimensions acquire meaning only when interpreted in the biological and clinical context that produced them. Regenerative outcomes vary with defect morphology, surgical access, wound stability, host characteristics, materials, postoperative conditions, and the functional environment to which the tooth will later be exposed. These factors should not be compressed into a single prognostic score because their effects are not necessarily linear, independent, or constant across patients.

Defect morphology provides a clear example. Three-year cohort evidence suggests that the geometry of an intrabony defect can influence the incremental value of adjunctive grafting when enamel matrix derivative is used, with treatment response differing according to defect configuration [18]. Such findings are clinically useful, but a morphology-dependent interaction observed within one treatment context should not be converted into a universal decision threshold. The appropriate inference is narrower: morphology changes the biological environment within which a regenerative strategy operates.

The same principle applies to combinations of regenerative biomaterials. Randomized evidence indicates that adding platelet-rich fibrin to guided tissue regeneration with bovine porous bone mineral can modify some clinical and radiographic outcomes, while other endpoints may not differ in the same way [19]. The result argues against reducing treatment evaluation to whether a specific material was present. Functional interpretation instead requires examination of which endpoint changed, how durable that change was, and whether the change altered maintainability or rehabilitation potential.

Surgical invasiveness is likewise an independent variable. A randomized trial comparing a flapless approach with and without enamel matrix derivative illustrates that regenerative strategy can be modified while the operative access itself is kept deliberately limited [20]. Such studies are useful because they separate the biological contribution of an adjunct from the effects of surgical architecture, wound preservation, and tissue handling. A favorable clinical result after minimally invasive treatment should nevertheless remain a clinical result; it does not by itself establish the histologic pathway responsible for healing.

Host factors also modify interpretation. Prospective evidence evaluating aging in patients undergoing enamel-matrix-derivative therapy indicates that patient characteristics can influence regenerative outcomes without supporting a categorical age threshold for treatment eligibility [21]. A conceptual framework should therefore distinguish effect modification from exclusion criteria. Age, systemic condition, smoking exposure, oral hygiene, adherence, and other host factors may alter probability, magnitude, or durability of success, but they should not be transformed into absolute rules unless the evidence specifically supports such use.

Wound stability is another clinically relevant interface between biological potential and delivered outcome. Papilla-preservation approaches have been developed to maintain soft-tissue integrity and stabilize the regenerative compartment, and randomized evidence shows that favorable results can be achieved with carefully controlled surgical designs with or without additional biomaterials [22]. The resulting lesson is not that one flap design guarantees regeneration. Rather, the surgical environment can determine whether biologically plausible regenerative processes are given adequate conditions to occur.

Newer operative technologies must be evaluated through the same logic. A multicenter randomized comparison of Er,Cr laser treatment with a minimally invasive surgical technique demonstrates the importance of testing device-based approaches against active clinical alternatives rather than inferring benefit from technological novelty or proposed mechanism alone [23]. A device may change access, debridement, wound characteristics, or patient experience, but those effects must remain distinguished from proof of periodontal tissue reconstruction.

Finally, the patient's experience remains part of the clinical state in which regenerative outcomes are interpreted. Patient-reported outcomes in bone-regenerative procedures demonstrate that pain, satisfaction, treatment burden, and related experiences can diverge from clinician-reported measures [24]. The divergence is not a methodological inconvenience. It identifies another way in which a technically favorable outcome can remain only partially successful.

The evidence therefore supports a contextual rather than additive interpretation. Defect anatomy establishes biological opportunity and constraint. Surgical design influences wound stability and tissue preservation. Host characteristics modify healing and maintenance. Regenerative adjuncts may alter specific outcomes but do not substitute for appropriate case selection or surgical execution. Patient experience adds a separate appraisal of treatment burden and value. The functional meaning of the final periodontal condition emerges from the interaction of these factors with the three dimensions described above.

A clinically useful interpretation should therefore ask not merely whether a variable is favorable but where in the chain of functional success it operates. Defect morphology primarily modifies the opportunity for reconstruction. Wound stability governs whether that opportunity can be realized during healing. Residual pocket status and recurrent inflammation affect maintainability. Mobility, occlusal demands, tooth position, and restorative requirements become increasingly important as the treatment pathway moves toward rehabilitation. This multilevel organization prevents evidence obtained at one stage from being used to answer a different question at another.

Table 3. Context-sensitive assessment of a regenerated periodontal site before functional success is assigned

Determinant or observed state	Primary level affected	Why it modifies interpretation	Example of clinically discordant presentation	Functional-success response
Defect depth, angle, and remaining bony walls	Biological reconstruction opportunity	Geometry affects wound containment and regenerative response	Large attachment gain in a favorable defect versus modest gain in an unfavorable anatomy	Interpret magnitude relative to baseline anatomical opportunity rather than through one universal expectation

Root-surface and local tissue conditions	Biological interface	Attachment formation depends on a biologically compatible wound environment	Radiographic improvement without confidence in complete attachment reconstruction	Preserve distinction between clinical improvement and biological certainty
Papilla preservation and wound stability	Early healing	Tissue stability influences maturation of the regenerative compartment	Adequate material placement with postoperative wound disruption	Downgrade confidence in biological success even if some clinical gain remains
Regenerative adjunct or device	Treatment-specific modifier	Adjuncts can change selected outcomes but effects may be endpoint-specific	Improvement in one parameter without corresponding change in others	Judge the achieved endpoint rather than attributing global success to the technology
Host and behavioral context	Healing and maintenance	Patient factors modify response and durability	Good early response with later instability under unfavorable maintenance conditions	Separate initial regenerative response from durable maintainability
Residual inflammatory environment	Maintainability	Recurrent inflammation threatens persistence of reconstructed support	Attachment gain with repeated bleeding and deep residual probing	Classify as biologically improved but functionally incomplete
Patient-reported burden and value	Patient-centered function	Treatment success includes experience and long-term acceptability	Stable periodontal measurements with high treatment burden	Report clinical and patient-centered success separately
Anticipated orthodontic, occlusal, or prosthetic demands	Rehabilitation boundary	Future loading may exceed what a merely stable site can predictably tolerate	Clinically maintainable tooth whose support remains inadequate for the planned rehabilitation	Withhold full functional-success designation until rehabilitation suitability is established

The relationships summarized in **Table 3** are better represented as a multilevel landscape than as a single directional treatment pathway. Biological reconstruction, clinical maintainability, and rehabilitation readiness are sequentially related in some patients but may also constrain one another reciprocally. **Figure 1** therefore maps the principal evidence-supported relationships while keeping inference boundaries explicit.

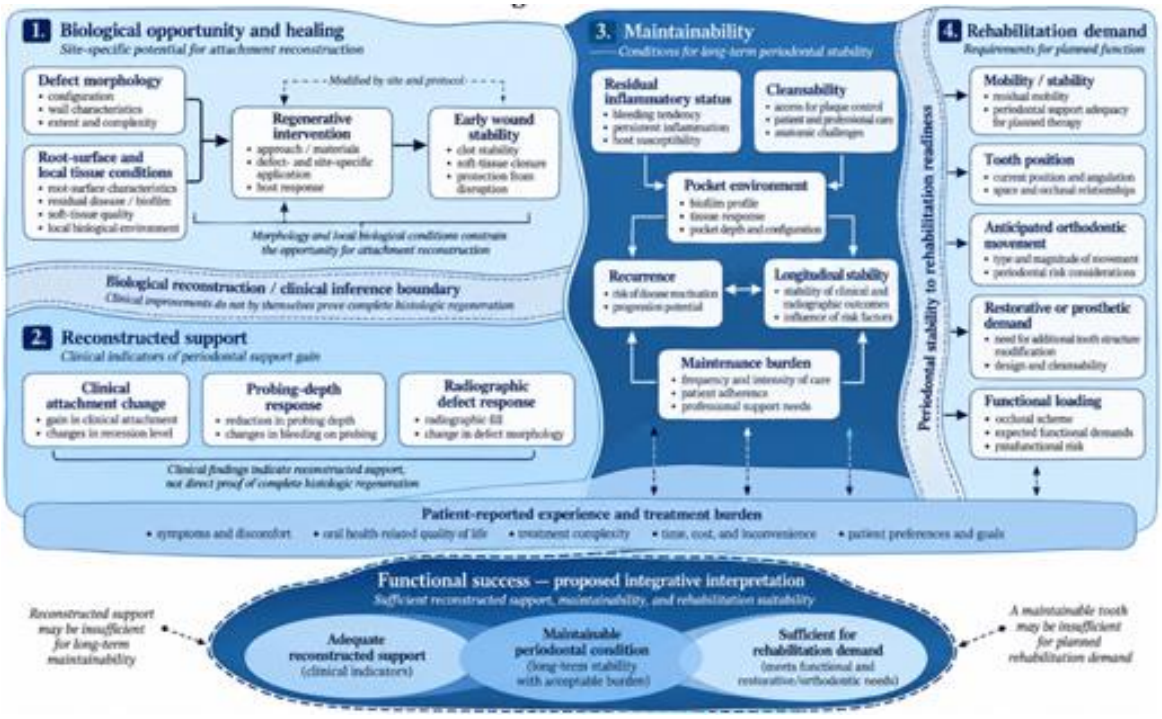

Figure 1. Where periodontal regenerative success is gained, qualified, or lost across biological and clinical levels

A multidimensional framework for evaluating regenerative success

A functionally successful regenerative result cannot be defined by maximizing a single periodontal endpoint. Its interpretation depends instead on whether reconstructed periodontal support is compatible with stability, maintenance, and the functional demands expected of the tooth. This distinction becomes particularly important when mobility and occlusal function remain clinically relevant after inflammation has been controlled. Evidence concerning splinting and occlusal adjustment in periodontitis is heterogeneous and does not support their indiscriminate use; mechanical stabilization should therefore be regarded as a context-dependent component of management rather than an obligatory consequence of mobility [25]. At the same time, mobility, loss of posterior support, impaired mastication, and poorer oral-health-related quality of life are associated with more advanced periodontal states, demonstrating that attachment measurements alone do not describe the functional burden of disease [26].

The proposed framework consequently interprets regenerative success through concordance among three dimensions. Attachment reconstruction asks whether clinically meaningful periodontal support has been restored. Maintainability asks whether that result can remain stable in an accessible, inflammation-controlled periodontal environment. Rehabilitation suitability asks whether the resulting tooth can tolerate the biological and mechanical demands of subsequent care. None is assigned a universal numerical threshold because the clinically sufficient state depends on baseline anatomy, intended treatment, time, and patient-specific conditions.

Rehabilitation suitability is especially important when tooth movement is contemplated. Systematic evidence indicates that orthodontic treatment can be incorporated into the care of appropriately treated periodontal patients, including patients with pathological migration and selected Stage IV defects, but the available evidence does not justify a single universal interval, force prescription, or readiness threshold [27-29]. Periodontal control and reassessment therefore remain conditions for interpretation rather than boxes that can be checked solely according to elapsed time.

Long-term observational evidence provides an important proof of principle. In a highly selected cohort of compliant Stage IV patients treated with regenerative surgery followed by orthodontic movement, periodontal and radiographic stability could be maintained over approximately a decade [30]. The appropriate inference is not that regenerated teeth are universally ready for orthodontic loading. Instead, the study demonstrates that biological regeneration and subsequent mechanical rehabilitation are not inherently incompatible when case selection, periodontal stability, treatment sequencing, and maintenance are favorable.

This creates several possible states of discordant **success**. A tooth may show attachment gain but retain a deep, recurrently inflamed pocket; its reconstruction is clinically favorable, but its maintainability is incomplete. Another tooth may be maintainable yet exhibit mobility, positional instability, or insufficient periodontal support for the intended prosthetic or orthodontic demand; its periodontal stability does not establish rehabilitation suitability. A third tooth may remain functional for years even though available clinical measures cannot establish complete histologic regeneration. Such cases should not be forced into a binary success/failure category.

The framework therefore rejects an additive score in which a strong result in one domain automatically cancels weakness in another. Instead, each domain functions as a clinically relevant constraint. The required level of support is treatment-dependent: a tooth expected only to remain stable within the existing dentition may face different demands from a tooth intended for orthodontic movement, abutment function, major occlusal reconstruction, or correction of pathological migration.

The resulting concept of functional success is consequently conditional**:** periodontal support must be sufficient not only to demonstrate improvement, but to remain maintainable and appropriate for the future role assigned to the tooth. **Figure 2** represents this distinction as a nonlinear constraint landscape rather than as a treatment algorithm.

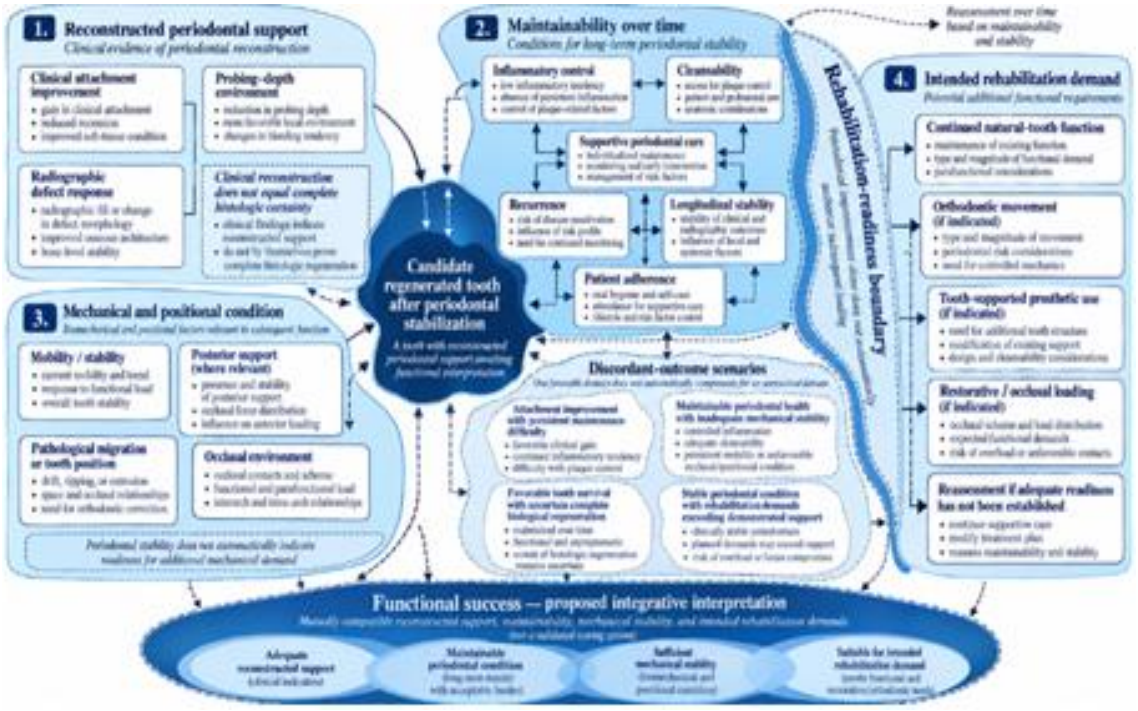

Figure 2. Rehabilitation readiness as a conditional boundary after periodontal regeneration

Clinical implications, limitations, and future validation

The principal clinical implication of the framework is that a regenerated tooth should be judged in relation to the role it is expected to perform. This is particularly relevant in advanced periodontitis, where retained teeth may later support fixed prostheses. Systematic evidence indicates that tooth-supported prosthetic rehabilitation can remain feasible after periodontal treatment in selected Stage IV patients [31]. Such findings challenge the assumption that a heavily compromised but successfully treated tooth necessarily has little subsequent restorative value.

They do not, however, justify unconditional tooth retention. Comparisons between tooth-supported and implant-supported full-arch rehabilitation remain influenced by case selection, residual dentition, prosthetic design, maintenance requirements, patient preference, and the limitations of the available comparative evidence [32]. The functional-success framework therefore does not designate either preservation or replacement as intrinsically superior. Its role is to improve the quality of the question asked before that decision: is the treated tooth biologically and clinically stable enough, maintainable enough, and mechanically appropriate enough for its proposed future role?

That distinction is supported by long-term randomized evidence involving teeth severely compromised by attachment loss extending toward the apex. Regenerative treatment allowed some such teeth to remain viable over a ten-year period when compared with extraction followed by implant or prosthetic replacement [33]. The finding demonstrates that extreme baseline attachment loss should not automatically be interpreted as proof that preservation lacks value. It does not establish that every severely compromised tooth should undergo regeneration, nor that preservation is generally superior to replacement.

The framework has several limitations. First, its three dimensions are synthesized from evidence generated for different purposes; they have not yet been validated prospectively as a unified assessment construct. Second, commonly reported regenerative endpoints are measured at different biological levels. Clinical attachment level, probing depth, radiographic change, mobility, patient experience, and tooth survival cannot be assumed to measure the same underlying state. Third, long-term regenerative and interdisciplinary studies often involve selected patients receiving specialist care and intensive maintenance, limiting transportability to less controlled settings.

A further limitation is the absence of validated universal thresholds for rehabilitation readiness. The framework intentionally does not specify a minimum attachment gain, radiographic fill percentage, mobility category, defect angle, or waiting period that converts periodontal stability into orthodontic or prosthetic readiness. Such thresholds would exceed the available evidence and would ignore differences in intended loading, tooth anatomy, baseline support, occlusal environment, and patient-level risk.

Future validation should therefore be prospective and explicitly multidimensional. Studies should collect biological and conventional periodontal endpoints together with maintenance burden, mobility, tooth retention, patient-reported outcomes, subsequent rehabilitation exposure, and longitudinal function. Particular attention should be paid to discordant cases, because those cases offer the strongest test of whether the framework adds information beyond standard regenerative measures. Validation should also determine whether individual domains predict clinically consequential events without prematurely converting them into a single composite score.

The most useful future question is consequently not whether one universal definition of regenerative success can replace all existing endpoints. It is whether a transparent multidimensional interpretation can identify when apparently successful reconstruction is insufficient for the next clinical demand and when a less-than-ideal biological result nevertheless supports durable, maintainable function.

Conclusion

Functional success after periodontal regeneration is broader than clinical attachment gain, probing-depth reduction, radiographic defect fill, or tooth retention considered individually. A defensible interpretation requires three related judgments: whether periodontal support has been meaningfully reconstructed, whether the resulting condition can be maintained over time, and whether that condition is adequate for the functional and rehabilitative demands expected of the tooth.

These dimensions may disagree, and that discordance is clinically informative. Biological improvement does not automatically establish maintainability, and periodontal stability does not automatically establish readiness for orthodontic, prosthetic, or other mechanical demands. Conversely, incomplete evidence of histologic regeneration does not necessarily eliminate the long-term functional value of a stable, maintainable tooth.

The proposed framework therefore treats functional regenerative success as a conditional relationship between reconstructed support, durability, and intended use rather than as a single endpoint or numerical score. Its clinical value now requires prospective validation using multidimensional outcomes and long-term follow-up.

Acknowledgments: None

Conflict of Interest: None

Financial Support: None

Ethics Statement: None

References

1. Tonetti MS, Greenwell H, Kornman KS. Staging and grading of periodontitis: Framework and proposal of a new classification and case definition. J Clin Periodontol. 2018;45(Suppl 20). doi:10.1111/jcpe.12945
2. Papapanou PN, Sanz M, Buduneli N, Dietrich T, Feres M, Fine DH, et al. Periodontitis: Consensus report of workgroup 2 of the 2017 World Workshop on the Classification of Periodontal and Peri-Implant Diseases and Conditions. J Clin Periodontol. 2018;45(Suppl 20). doi:10.1111/jcpe.12946
3. Herrera D, Sanz M, Kebschull M, Jepsen S, Sculean A, Berglundh T, et al. Treatment of stage IV periodontitis: The EFP S3 level clinical practice guideline. J Clin Periodontol. 2022;49(Suppl 24):4-71. doi:10.1111/jcpe.13639
4. Sanz M, Herrera D, Kebschull M, Chapple I, Jepsen S, Berglundh T, et al. Treatment of stage I-III periodontitis—the EFP S3 level clinical practice guideline. J Clin Periodontol. 2020;47(Suppl 22):4-60. doi:10.1111/jcpe.13290
5. Saleh MHA, Dias DR, Ravida A, Wang HL. Root surface biomodification in periodontal therapy: Biological rationale and clinical applications. Periodontol 2000. 2024;00:1-21. doi:10.1111/prd.12576
6. Nibali L, Koidou VP, Nieri M, Barbato L, Pagliaro U, Cairo F. Regenerative surgery versus access flap for the treatment of intra-bony periodontal defects: A systematic review and meta-analysis. J Clin Periodontol. 2020;47(Suppl 22):320-51. doi:10.1111/jcpe.13237
7. Stavropoulos A, Bertl K, Spineli LM, Sculean A, Cortellini P, Tonetti MS. Medium- and long-term clinical benefits of periodontal regenerative/reconstructive procedures in intrabony defects: Systematic review and network meta-analysis of randomized controlled clinical studies. J Clin Periodontol. 2021;48(3):410-30. doi:10.1111/jcpe.13409
8. Jepsen K, Sculean A, Jepsen S. Complications and treatment errors related to regenerative periodontal surgery. Periodontol 2000. 2023;92(1):120-34. doi:10.1111/prd.12504
9. Galarraga-Vinueza ME, Barootchi S, Nevins ML, Nevins M, Miron RJ, Tavelli L. Twenty-five years of recombinant human growth factors

rhPDGF-BB and rhBMP-2 in oral hard and soft tissue regeneration. Periodontol 2000. 2024;94(1):483-509. doi:10.1111/prd.12522
10. Nibali L, Sultan D, Arena C, Pelekos G, Lin GH, Tonetti M. Periodontal infrabony defects: Systematic review of healing by defect morphology following regenerative surgery. J Clin Periodontol. 2021;48(1):100-13. doi:10.1111/jcpe.13381
11. Aimetti M, Fratini A, Manavella V, Giraudi M, Citterio F, Ferrarotti F, et al. Pocket resolution in regenerative treatment of intrabony defects with papilla preservation techniques: A systematic review and meta-analysis of randomized clinical trials. J Clin Periodontol. 2021;48(6):843-58. doi:10.1111/jcpe.13428
12. Cortellini P, Buti J, Pini Prato G, Tonetti MS. Periodontal regeneration compared with access flap surgery in human intra-bony defects 20-year follow-up of a randomized clinical trial: Tooth retention, periodontitis recurrence and costs. J Clin Periodontol. 2017;44(1):58-66. doi:10.1111/jcpe.12638
13. Cieplik F, Ihlenfeld I, Hiller KA, Pummer A, Schmalz G, Buchalla W, et al. Tooth survival and clinical outcomes up to 26 years after guided tissue regeneration therapy in deep intra-bony defects: Follow-up investigation of three randomized clinical trials. J Clin Periodontol. 2020;47(7):863-74. doi:10.1111/jcpe.13302
14. Cortellini P, Cortellini S, Bonaccini D, Tonetti MS. Modified minimally invasive surgical technique in human intrabony defects with or without regenerative materials—10-year follow-up of a randomized clinical trial: Tooth retention, periodontitis recurrence, and costs. J Clin Periodontol. 2022;49(6):528-36. doi:10.1111/jcpe.13627
15. Koronna I, Schacher B, Dahmer I, Nickles K, Sonnenschein SK, Kim TS, et al. Long-term stability of infrabony defects treated with enamel matrix derivative alone: A retrospective two-centre cohort study. J Clin Periodontol. 2023;50(7):996-1009. doi:10.1111/jcpe.13814
16. Chen Z, Lin CY, Wang HL. Patient-reported outcome measures and health economics in regenerative periodontal therapy: A systematic review and meta-analysis. Periodontol 2000. 2024;00:1-21. doi:10.1111/prd.12601
17. Arunyanak SP, Kungsadalpipob K, Wright KE, Subbalekha K, Dragan I, Mattheos N. The use of patient-related outcomes (PRO) and experience (PRE) in assessing the periodontal and implant patient. Periodontol 2000. 2024;95(1):40-50. doi:10.1111/prd.12589
18. Matsuura T, Mikami R, Mizutani K, Shioyama H, Aoyama N, Suda T, et al. Assessment of bone defect morphology for the adjunctive use of bone grafting combined with enamel matrix derivative: A 3-year cohort study. J Periodontol. 2024;95(9):809-20. doi:10.1002/JPER.23-0538
19. Liu K, Huang Z, Chen Z, Han B, Ouyang X. Treatment of periodontal intrabony defects using bovine porous bone mineral and guided tissue regeneration with/without platelet-rich fibrin: A randomized controlled clinical trial. J Periodontol. 2021;92(11):1546-53. doi:10.1002/JPER.20-0860
20. Aimetti M, Stasikelyte M, Mariani GM, Cricenti L, Baima G, Romano F. The flapless approach with and without enamel matrix derivatives for the treatment of intrabony defects: A randomized controlled clinical trial. J Clin Periodontol. 2024;51(9):1112-21. doi:10.1111/jcpe.14028
21. Mikami R, Mizutani K, Shioyama H, Matsuura T, Aoyama N, Suda T, et al. Influence of aging on periodontal regenerative therapy using enamel matrix derivative: A 3-year prospective cohort study. J Clin Periodontol. 2022;49(2):123-33. doi:10.1111/jcpe.13552
22. Aslan S, Buduneli N, Cortellini P. Clinical outcomes of the entire papilla preservation technique with and without biomaterials in the treatment of isolated intrabony defects: A randomized controlled clinical trial. J Clin Periodontol. 2020;47(4):470-8. doi:10.1111/jcpe.13255
23. Clem D, Heard R, McGuire M, Scheyer ET, Richardson C, Toback G, et al. A comparison of Er,Cr laser to minimally invasive surgical technique in the treatment of intrabony defects: Twelve-month results of a multicenter, randomized, controlled study. J Periodontol. 2024;95(7):621-31. doi:10.1002/JPER.23-0286
24. Gotfredsen K. Patient-reported outcomes for bone regenerative procedures. Periodontol 2000. 2023;93(1):270-6. doi:10.1111/prd.12500
25. Dommisch H, Walter C, Difloe-Geisert JC, Gintaute A, Jepsen S, Zitzmann NU. Efficacy of tooth splinting and occlusal adjustment in patients with periodontitis exhibiting masticatory dysfunction: A systematic review. J Clin Periodontol. 2022;49(Suppl 24):149-66. doi:10.1111/jcpe.13563
26. Uy SNMR, Deng K, Fok CTC, Fok MR, Pelekos G, Tonetti MS. Food intake, masticatory

function, tooth mobility, loss of posterior support, and diminished quality of life are associated with more advanced periodontitis stage diagnosis. J Clin Periodontol. 2022;49(3):240-50. doi:10.1111/jcpe.13588

27. Martin C, Celis B, Ambrosio N, Bollain J, Antonoglou GN, Figuero E. Effect of orthodontic therapy in periodontitis and non-periodontitis patients: A systematic review with meta-analysis. J Clin Periodontol. 2022;49(Suppl 24):72-101. doi:10.1111/jcpe.13487
28. Papageorgiou SN, Antonoglou GN, Michelogiannakis D, Kakali L, Eliades T, Madianos P. Effect of periodontal-orthodontic treatment of teeth with pathological tooth flaring, drifting, and elongation in patients with severe periodontitis: A systematic review with meta-analysis. J Clin Periodontol. 2022;49(Suppl 24):102-20. doi:10.1111/jcpe.13529
29. Kloukos D, Roccuzzo A, Stähli A, Sculean A, Katsaros C, Salvi GE. Effect of combined periodontal and orthodontic treatment of tilted molars and of teeth with intra-bony and furcation defects in stage-IV periodontitis patients: A systematic review. J Clin Periodontol. 2022;49(Suppl 24):121-48. doi:10.1111/jcpe.13509
30. Tietmann C, Jepsen S, Heibrok H, Wenzel S, Jepsen K. Long-term stability of regenerative periodontal surgery and orthodontic tooth movement in stage IV periodontitis: 10-year data of a retrospective study. J Periodontol. 2023;94(10):1176-86. doi:10.1002/JPER.23-0081
31. Montero E, Molina A, Palombo D, Morón B, Pradíes G, Sanz-Sánchez I. Efficacy and risks of tooth-supported prostheses in the treatment of partially edentulous patients with stage IV periodontitis. A systematic review and meta-analysis. J Clin Periodontol. 2022;49(Suppl 24):182-207. doi:10.1111/jcpe.13482
32. Tomasi C, Albouy JP, Schaller D, Camino Navarro R, Derks J. Efficacy of rehabilitation of stage IV periodontitis patients with full-arch fixed prostheses: Tooth-supported versus implant-supported—A systematic review. J Clin Periodontol. 2022;49(Suppl 24):248-71. doi:10.1111/jcpe.13511
33. Cortellini P, Stalpers G, Mollo A, Tonetti MS. Periodontal regeneration versus extraction and dental implant or prosthetic replacement of teeth severely compromised by attachment loss to the apex: A randomized controlled clinical trial reporting 10-year outcomes, survival analysis and mean cumulative cost of recurrence. J Clin Periodontol. 2020;47(6):768-76. doi:10.1111/jcpe.13289