

Original Article

Orofacial Findings in Moderate-to-Severe COVID-19: Loss of Taste, Xerostomia, and High Prevalence of Opportunistic Candidiasis

Sven L. Eriksson^{1*}, Nur S. Ismail¹, Marco R. Bianchi¹

¹Department of Oral and Maxillofacial Surgery, Institute of Odontology, Karolinska Institute, Stockholm, Sweden.

*E-mail ✉ sven.eriksson@outlook.se

Received: 19 September 2023; Revised: 29 November 2023; Accepted: 05 December 2023

ABSTRACT

The oral cavity can reflect early indicators of various systemic conditions. Since the start of the COVID-19 outbreak, numerous publications have highlighted the virus's direct impact on oral and facial tissues. In this investigation, oral symptoms and clinical findings of 22 hospitalized individuals with COVID-19 were assessed and contrasted with a comparable control sample. Disturbances in taste and smell were the most frequently reported complaints (65%), followed by xerostomia (45%) and bad breath (30%). Candidiasis represented the most frequent oral pathology (68%). Less frequent changes included ulcerative lesions (36%) and white mucosal patches (27.3%). A significant correlation was detected between fungal infections and patient age, with a p-value of 0.008. In this cohort, 80% of those diagnosed with candidal lesions were 60 years or older. No significant relationship was noted with chronic conditions such as hypertension or diabetes.

Keywords: Orofacial, COVID-19, Taste, Xerostomia, Candidiasis

How to Cite This Article: Eriksson SL, Ismail NS, Bianchi MR. Orofacial Findings in Moderate-to-Severe COVID-19: Loss of Taste, Xerostomia, and High Prevalence of Opportunistic Candidiasis. *J Curr Res Oral Surg.* 2023;3:135-41. <https://doi.org/10.51847/erItkNqzQe>

Introduction

Severe acute respiratory syndrome coronavirus 2 (SARS-CoV-2), the causative agent of the COVID-19 pandemic, is a highly transmissible single-stranded RNA virus with a 1–14-day incubation interval [1–4]. Clinical presentation ranges from mild influenza-like illness to advanced respiratory compromise. Early manifestations—weakness, fever, cephalalgia, pharyngitis, coughing, rhinorrhea, gastrointestinal pain, vomiting, and diarrhea—typically develop within 4–5 days [5]. Reported skin-related findings include petechial eruptions, vesiculobullous changes, erythematous lesions, and urticarial patterns [2, 6]. Orofacial signs may begin with anosmia or other olfactory disturbances [7]. Viral entry into oral epithelial tissue occurs through angiotensin-converting enzyme 2 receptors, enabling viral multiplication and subsequent mucosal inflammation [4]. A wide variety of oral mucosal alterations has been documented, such

as erosions, ulcers, vesicles, pustules, depapillated or fissured tongue, maculopapular lesions, plaques [8–13], pigmentation, malodor, white plaques, hemorrhagic crusting, necrotic areas, erythema, and spontaneous bleeding [14–19]. The tongue [4, 14] was the most frequently affected site, followed by the lips and palate. Proposed diagnoses have included aphthous ulceration, herpetiform lesions, fungal infections, and vasculitic processes.**

Since the onset of the pandemic, more than 603,711,760 confirmed cases and 6,484,136 deaths have been reported globally according to the WHO [5]. The first confirmed SARS-CoV-2 infection in Saudi Arabia occurred on 2 March 2020 [20–23]. Case numbers increased rapidly thereafter, reaching 813,986 documented infections by 8 September 2022, with 801,254 recoveries. Mortality was 2%, with 9,309 recorded deaths [24].

Hospital admission criteria for moderate or severe cases in Saudi Arabia are based on respiratory involvement and additional conditions such as cancer, obesity, diabetes, or immune suppression [25]. Prior descriptive analyses of COVID-19 cases in Saudi Arabia have shown that age and comorbid diseases significantly influence presenting symptoms [23]. However, no research had examined oral findings in hospitalized COVID-19 patients within the country. Because oral changes may support early detection, the purpose of this study was to document oral manifestations among admitted COVID-19 cases and compare their prevalence with an age-, gender-, and comorbidity-matched control group.

Materials and Methods

Study design

A two-center case-control investigation was carried out among hospitalized COVID-19 patients at King Fahad General Hospital and East Jeddah General Hospital, Jeddah, Saudi Arabia, from 1 September to 30 October 2021. Ethical approval was granted by the Ministry of Health's Research and Studies Department (KACST, KSA: H-02-J-002).

Study subjects

Inclusion criteria

Patients of any age admitted due to COVID-19.

Exclusion criteria

- COVID-19 patients not requiring hospital admission.
- Hospitalized individuals on ventilatory support at the time of clinical evaluation, making oral assessment impossible.

The control cohort was selected from dental clinics in the same institutions and matched for age, sex, and associated medical conditions. All participants were interviewed and assessed intraorally by two oral medicine specialists (SA and SJ) to detect any relevant mucosal changes. Written informed consent was obtained from each patient or legal guardian. Demographic and clinical variables—including age, sex, existing medical conditions, medications, interval

since symptom onset, vaccination status, and number of vaccine doses—were documented. Each participant underwent two levels of screening recorded on a standardized data form.

Patients were initially interviewed regarding the presence and intensity of the following complaints after developing COVID-19:

1. Altered perception of taste or smell.
2. Pain in the orofacial region.
3. Bad breath.
4. Sensation of oral dryness.
5. Any ulcers, vesicles, or bullous lesions in the mouth.

Symptom intensity was assessed through the validated visual analog scale (VAS) [26]. Next, two primary examiners carried out oral mucosal inspections using disposable tongue depressors and a flashlight to identify all intraoral abnormalities with precise site documentation. Any white lesion was gently scraped with gauze. Identical examination procedures were followed for the control participants.

Data analysis

Data were processed using the Statistical Package for Social Sciences (SPSS for Mac, Version 28.0; IBM, 2019). Descriptive analyses—means (\bar{x}), standard deviations (SD), frequencies, and percentages—were computed for all relevant variables. Associations between qualitative variables or comparisons across proportions were determined using the chi-square test (χ^2) or Fisher's exact test when applicable. Statistical significance was set at $p = 0.05$, and all p -values were derived from two-tailed tests.

Results and Discussion

Patients

A total of 22 individuals participated: 16 males (72.7%) and six females (27.3%), with an average age of 57.9 ± 16.1 years. Eighteen patients (82%) had underlying health conditions; among them, 16 (88.9%) had diabetes, and 11 (61.1%) had hypertension. The control sample had the same sex distribution and was matched for age and medical history (**Table 1**).

Table 1. Patients' characteristics.

Variable	Study Group (Hospitalized COVID-19) (n = 22)		Control Group (n = 22)	
	n	%	n	%
Age distribution (years)				
< 20	1	4.5	1	4.5
20 – < 30	1	4.5	1	4.5
40 – < 50	4	18.2	4	18.2
50 – < 60	3	13.6	3	13.6

≥ 60	13	59.1	13	59.1
Mean age ± SD	57.9 ± 16.1 years		57.9 ± 16.1 years	
Sex				
Male	16	72.7	16	72.7
Female	6	27.3	6	27.3
Presence of systemic comorbidities				
Absent	4	18.2	4	18.2
Present	18	81.8	18	81.8
Specific comorbidities (among patients with comorbidities, n = 18 per group)				
Diabetes mellitus	16	88.9	16	88.9
Hypertension	11	61.1	11	61.1
Immunosuppression	3	16.7	3	16.7
Asthma	1	5.6	1	5.6
Cardiac disease	1	5.6	1	5.6
Kidney transplant	1	5.6	0	0.0

The mean duration to a confirmed COVID-19 diagnosis was 11.0 ± 6.3 days. Overall, 20 individuals (90.1%) in the COVID-19 group experienced at least one orofacial complaint. About 65% reported diminished taste and smell, and 45% indicated dry mouth (**Table 2**). Additionally, 27.3% were unvaccinated, whereas 72.8% had received one or two vaccine doses (equal proportion). **Figure 1** illustrates the timing of symptom onset following diagnosis.

Table 2. Distribution of the study group based on orofacial symptoms.

Orofacial Symptoms in Hospitalized COVID-19 Patients (n = 22)	n	%
Presence of any orofacial symptom		
Yes	20	90.9
No	2	9.1
Specific symptoms (multiple responses possible)		
Loss of taste and/or smell	13	65.0
Oral dryness (xerostomia)	9	45.0
Halitosis (bad breath)	6	30.0
Pain due to oral ulceration	2	10.0
Facial pain	2	10.0

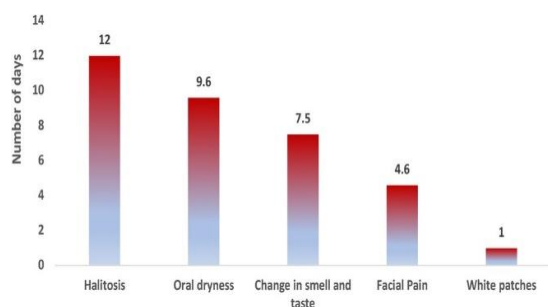


Figure 1. Mean onset time for orofacial symptoms: halitosis appeared at 12.0 ± 12.7 days, oral dryness at 9.6 ± 5.2 days, smell/taste alteration at 7.5 ± 5.3 days, facial pain at 4.6 ± 2.0 days, and white patches at 1 ± 0.0 day after symptom onset.

Regarding symptom severity, altered taste and smell ranked highest with a mean VAS score of 8.9 ± 2.0/10, followed by halitosis and facial pain, both averaging 4.6 ± 2.3.

Oral lesions

Roughly 36.4% of participants exhibited oral ulcerations during admission. Palatal petechiae appeared in one individual. White mucosal patches were observed in 27.3% of the group, and 68.2% had candidal lesions. **Table 3** summarizes lesion distribution by site.

Table 3. Distribution of oral manifestations in the study and control groups.

Condition / Location	Study group N (%)	Control group N (%)
Oral ulceration (total)	8 (36.4)	2 (15.4)
- Buccal mucosa	5 (62.5)	1 (50.0)
- Tongue	2 (25.0)	1 (50.0)
- Gingiva	1 (12.5)	0
White patches (total)	6 (27.3)	2 (15.4)
- Buccal mucosa	6 (100.0)	2 (100.0)
- Lips	1 (16.7)	0
Candidiasis (any site)	15 (68.2)	4 (30.8)
- Tongue	9 (60.0)	3 (75.0)
- Palatal mucosa	6 (40.0)	1 (25.0)

Among the controls, oral mucosal changes were documented in 59.1% of individuals; candida accounted for 30.8%, followed by tongue depapillation, white patches, ulcers, and petechiae (23.1%, 15.4%, 15.4%, and 15.4%, respectively).

Comparison of *Candida* prevalence between groups revealed a significant difference ($p = 0.001$): 68.2% in the COVID-19 group vs. 18.2% in controls. No meaningful differences were found between groups for other lesion types.

There was no notable association between comorbidities and oral lesions in either group except for hypertension and ulcer presence among controls ($p = 0.013$). In contrast, a significant relationship was observed between age and candidiasis in the study group ($p = 0.008$). In this cohort, 80% of individuals with candidal lesions were 60 years or older. No links were detected between candidiasis and sex or comorbidities in the study or control groups.

A statistically significant association was found between immunosuppression and the presence of white patches in the study group ($p = 0.049$), but this did not appear in controls.

Candidal infections were also related to the time interval to COVID-19 diagnosis ($p = 0.006$). More than half (53.3%) of those with candidiasis had been diagnosed with COVID-19 at least one week earlier. Nonetheless, orofacial findings showed no association with COVID-19 vaccination status in the study sample. COVID-19 can present with manifestations across several organ systems, including the respiratory and gastrointestinal tracts, the skin, and the oral cavity. In this investigation, we documented oral findings among hospitalized individuals with COVID-19. The most frequent observations were alterations in taste and the presence of candidal lesions. Less frequently, patients experienced xerostomia and oral mucosal ulcers. These outcomes align with the most recent living systematic review by dos Santos *et al.*, which highlighted xerostomia and taste changes as the leading symptoms, and ulcerations as the predominant oral lesions, followed by herpes-like eruptions, candidiasis, and angular cheilitis [27].

Disturbances in taste and smell are recognized early indicators of SARS-CoV-2 infection. Research shows that such sensory changes are common in European populations but reported less in Asian cohorts, with an overall occurrence of about 38% [27]. These alterations tend to appear in mild to moderate cases. In the present cohort, 65% of patients with severe disease described diminished taste and smell, scoring a mean severity of 8.9 ± 2 . This complaint typically began 7.5 ± 5.3 days after symptoms started. Giacomelli *et al.* noted that 34% of hospitalized individuals reported smell or taste dysfunction, with 20.3% experiencing it prior to admission and 13.5% developing it during hospitalization, at an average of 6 days after COVID-19 onset [28].

Oral dryness is another complaint possibly linked to viral involvement of salivary glands [29]. Long-term use of medications—such as antihypertensives or oral hypoglycemics—can further influence salivary flow. Among our study and control participants, 89% were

diabetic and 61% were hypertensive. Here, 45% of the affected patients experienced dryness of the mouth, which appeared around 9.6 days after diagnosis. None of the controls reported this symptom. Still, no significant association emerged between xerostomia and either of the two comorbidities within the study sample. This frequency parallels the 43% prevalence reported in the meta-analysis by dos Santos *et al.* [27]. The link between COVID-19 and oral ulceration was initially noted by Carreras-Presas *et al.* [30]. Damage to oral tissues may arise either from direct viral activity or secondary factors—disease complications, systemic inflammation, or treatment regimens. The SARS-CoV-2 virus binds to ACE2 receptors, which are abundantly present in oral tissues such as the tongue and the palate [1, 31–33]. Another proposed mechanism is viral infection of oral keratinocytes and fibroblasts, potentially leading to necrosis and ulceration [3]. Anemia caused by hemolytic effects of the virus may also contribute to ulcer formation [34]. In our study, about one-third of patients developed oral ulcers during their hospital stay, a pattern consistent with several case reports [8, 30, 35]. Only two individuals in the control group exhibited ulcerations.

Pseudomembranous candidiasis was the predominant oral lesion among our COVID-19 cohort (68%), whereas only 18% of controls showed candidal involvement. Previous work from tertiary hospitals in Saudi Arabia [36] also found candidiasis to be the most frequent opportunistic infection in COVID-19 cases, likely influenced by chronic illnesses and extended hospitalization. SARS-CoV-2 infection is known to predispose patients to secondary fungal infections, and treatments such as azithromycin may disrupt microbial balance, increasing susceptibility [3]. We also observed significant relationships between candidiasis and both age and the time elapsed before COVID-19 diagnosis (p -values = 0.008 and 0.006). As expected, older adults—especially those aged 60 years and above—were more prone to candidal lesions. Comorbidities showed no association with candidal infection in this sample, likely because nearly 90% of the participants were diabetic.

There was no statistically significant link between comorbid conditions and other oral lesions in either group, with the exception of hypertension in the controls. This may be connected to side effects of antihypertensive drugs, which can cause oral reactions such as lichenoid inflammation or ulceration.

A primary limitation of this investigation is the small sample size. Many hospitalized COVID-19 patients could not be included due to critical illness or intubation, precluding interviews or examinations.

Also, blinding was not feasible given the nature of the study. Nevertheless, the findings emphasize the value of performing oral examinations in hospitalized COVID-19 patients to detect, treat, and alleviate oral symptoms, thereby improving comfort and quality of life.

Conclusion

Taste alteration and candidal infection were the most frequently observed oral findings in hospitalized COVID-19 patients. Xerostomia and oral ulcerations were also noted but occurred less often. The precise mechanism behind these symptoms remains uncertain. Taste changes are likely due to viral effects on epithelial tissues, whereas other lesions may arise from secondary infections related to compromised systemic health or medication use, including antibiotics. Conducting intraoral assessments for hospitalized COVID-19 patients is advisable to address any accompanying oral signs and symptoms.

Acknowledgments: We would like to thank the Ministry of Health in Saudi Arabia for their support during the study.

Conflict of Interest: The authors declare that the research was conducted in the absence of any commercial or financial relationships that could be construed as a potential conflict of interest.

Financial Support: None

Ethics Statement: The studies involving human participants were reviewed and approved by Research and Studies department, Ministry of Health, Saudi Arabia (KACST, KSA: H-02-J-002). The patients/participants provided their written informed consent to participate in this study.

References

1. Anaya-Saavedra G. Oral manifestations accompanying and related to COVID-19: overlooking the obvious. *Oral Dis.* 2021;28:2530–2. doi:10.1111/odi.13857
2. Bardellini E, Bondioni MP, Amadori F, Veneri F, Lougaris V, Meini A, et al. Non-specific oral and cutaneous manifestations of coronavirus disease 2019 in children. *Med Oral Patol Oral Cir Bucal.* 2021;26:549–53. doi:10.4317/medoral.24461
3. Brandão TB, Gueiros LA, Melo TS, Prado-Ribeiro AC, Nesrallah ACFA, Prado G, et al. Oral lesions in patients with SARS-CoV-2 infection: could the oral cavity be a target organ? *Oral Surg Oral Med*

4. Brandini DA, Takamiya AS, Thakkar P, Schaller S, Rahat R, Naqvi AR. COVID-19 and oral diseases: crosstalk, synergy or association? *Rev Med Virol.* 2021;3:e2226. doi:10.1002/rmv.2226
5. Organization WH. Health emergency dashboard WHO (COVID-19) homepage; 2021. Available from: <https://covid19.who.int/> (Accessed April 26, 2021).
6. Bemquerer LM, de Arruda JAA, Soares MPD, Mesquita RA, Silva TA. The oral cavity cannot be forgotten in the COVID-19 era: is there a connection between dermatologic and oral manifestations? *J Am Acad Dermatol.* 2021;84(3):e143–5. doi:10.1016/j.jaad.2020.11.034
7. Biadsee A, Biadsee A, Kassem F, Dagan O, Masarwa S, Ormianer Z. Olfactory and oral manifestations of COVID-19: sex-related symptoms-A potential pathway to early diagnosis. *Otolaryngol Head Neck Surg.* 2020;163(4):722–8. doi:10.1177/0194599820934380
8. Cruz Tapia RO, Peraza Labrador AJ, Guimaraes DM, Matos Valdez LH. Oral mucosal lesions in patients with SARS-CoV-2 infection. Report of four cases. Are they a true sign of COVID-19 disease? *Spec Care Dentist.* 2020;40(6):555–60. doi:10.1111/scd.12520
9. de Sousa F, Paradella TC. Considerations on oral manifestations of COVID-19. *J Med Virol.* 2021;93(2):667–8. doi:10.1002/jmv.26451
10. Di Spirito F, Pelella S, Argentino S, Sisalli L, Sbordone L. Oral manifestations and the role of the oral healthcare workers in COVID-19. *Oral Dis.* 2020;28:1003–4. doi:10.1111/odi.13688
11. Díaz Rodríguez M, Jimenez Romera A, Villarroel M. Oral manifestations associated with COVID-19. *Oral Dis.* 2020;1:960–2. doi:10.1111/odi.13555
12. Eghbali Zarch R, Hosseinzadeh P. COVID-19 from the perspective of dentists: a case report and brief review of more than 170 cases. *Dermatol Ther.* 2021;34(1): e14717. doi:10.1111/dth.14717
13. Egido-Moreno S, Valls-Roca-Umbert J, Jané-Salas E, López-López J, Estrugo-Devesa A. COVID-19 and oral lesions, short communication and review. *J Clin Exp Dent.* 2021;13(3):e287–94. doi:10.4317/jced.57981
14. Halepas S, Lee KC, Myers A, Yoon RK, Chung W, Peters SM. Oral manifestations of COVID-2019-related multisystem inflammatory syndrome in children: a review of 47 pediatric patients. *J Am*

- Dent Assoc (1939). 2021;152 (3):202–8. doi:10.1016/j.adaj.2020.11.014
15. Jimenez-Cauhe J, Ortega-Quijano D, Carretero-Barrio I, Suarez-Valle A, Saceda-Corralo D, Moreno-Garcia Del Real C, et al. Erythema multiforme-like eruption in patients with COVID-19 infection: clinical and histological findings. *Clin Exp Dermatol.* 2020;45(7):892–5. doi:10.1111/ced.14281
 16. Kitakawa D, Oliveira FE, Neves de Castro P, Carvalho L. Short report—herpes simplex lesion in the lip semimucosa in a COVID-19 patient. *Eur Rev Med Pharmacol Sci.* 2020;24(17):9151–3. doi:10.26355/eurrev_202009_22863
 17. La Rosa GRM, Libra M, De Pasquale R, Ferlito S, Pedullà E. Association of viral infections with oral cavity lesions: role of SARS-CoV-2 infection. *Front Med (Lausanne).* 2020;7:571214. doi:10.3389/fmed.2020.571214
 18. Maia CMF, Marques NP, de Lucena EHG, de Rezende LF, Martelli DRB, Martelli- Júnior H. Increased number of herpes zoster cases in Brazil related to the COVID-19 pandemic. *Int J Infect Dis.* 2021;104:732–3. doi:10.1016/j.ijid.2021.02.033
 19. Maniaci A, Iannella G, Vicini C, Pavone P, Nunnari G, Falsaperla R, et al. A case of COVID-19 with late-onset rash and transient loss of taste and smell in a 15-year-old boy. *Am J Case Rep.* 2020;21:e925813. doi:10.12659/AJCR.925813
 20. Alsofayan YM, Althunayyan SM, Khan AA, Hakawi AM, Assiri AM. Clinical characteristics of COVID-19 in Saudi Arabia: a national retrospective study. *J Infect Public Health.* 2020;13(7):920–5. doi:10.1016/j.jiph.2020.05.026
 21. Abubakr N, Salem ZA, Kamel AHM. Oral manifestations in mild-to-moderate cases of COVID-19 viral infection in the adult population. *Dent Med Probl.* 2021;58(1):7–15. doi:10.17219/dmp/130814
 22. Al-Khatib A. Oral manifestations in COVID-19 patients. *Oral Dis.* 2021;27 (Suppl 3):779–80. doi:10.1111/odi.13477
 23. Al-Omari A, Alhuqbani WN, Zaidi ARZ, Al-Subaie MF, AlHindi AM, Abogosh AK, et al. Clinical characteristics of non-intensive care unit COVID-19 patients in Saudi Arabia: a descriptive cross-sectional study. *J Infect Public Health.* 2020;13(11):1639–44. doi:10.1016/j.jiph.2020.09.003
 24. Riad A, Gomaa E, Hockova B, Klugar M. Oral candidiasis of COVID-19 patients: case report and review of evidence. *J Cosmet Dermatol.* 2021;20:1580–4. doi:10.1111/jocd.14066
 25. Aziz S, Arabi YM, Alhazzani W, Evans L, Citerio G, Fischkoff K, et al. Managing ICU surge during the COVID-19 crisis: rapid guidelines. *Intensive Care Med.* 2020;46(7):1303–25. doi:10.1007/s00134-020-06092-5
 26. Couper MP, Tourangeau R, Conrad FG, Singer E. Evaluating the effectiveness of visual analog scales: a web experiment. *Soc Sci Comput Rev.* 2006;24(2):227–45. doi:10.1177/0894439305281503
 27. Amorim dos Santos J, Normando AGC, Carvalho da Silva RL, Acevedo AC, De Luca Canto G, Sugaya N, et al. Oral manifestations in patients with COVID-19: a 6-month update. *J Dent Res.* 2021;100(12):1321–9. doi:10.1177/00220345211029637
 28. Giacomelli A, Pezzati L, Conti F, Bernacchia D, Siano M, Oreni L, et al. Self-reported olfactory and taste disorders in patients with severe acute respiratory coronavirus 2 infection: a cross-sectional study. *Clin Infect Dis.* 2020;71(15):889–90. doi:10.1093/cid/ciaa330
 29. Farook FF, Mohamed Nuzaim MN, Taha Ababneh K, Alshammari A, Alkadi L. COVID-19 pandemic: oral health challenges and recommendations. *Eur J Dent.* 2020;14(S01):S165–70. doi:10.1055/s-0040-1718641
 30. Martín Carreras-Presas C, Amaro Sánchez J, López-Sánchez AF, Jané-Salas E, Somacarrera Pérez ML. Oral vesiculobullous lesions associated with SARS-CoV-2 infection. *Oral Dis.* 2021;27(Suppl 3):710–2. doi:10.1111/odi.13382
 31. Amorim Dos Santos J, Normando AGC, Carvalho da Silva RL, Acevedo AC, De Luca Canto G, Sugaya N, et al. Oral manifestations in patients with COVID-19: a living systematic review. *J Dent Res.* 2021;100(2):141–54. doi:10.1177/0022034520957289
 32. Vieira AR. Oral manifestations in coronavirus disease 2019 (COVID-19). *Oral Dis.* 2021;27(Suppl 3):770. doi:10.1111/odi.13463
 33. Xu H, Zhong L, Deng J, Peng J, Dan H, Zeng X, et al. High expression of ACE2 receptor of 2019-nCoV on the epithelial cells of oral mucosa. *Int J Oral Sci.* 2020;12(01):8. doi:10.1038/s41368-020-0074-x
 34. Sarode GS, Sarode SC, Gadbail AR, Gondivkar S, Sharma NK, Patil S. Are oral manifestations related to SARS-CoV-2 mediated hemolysis and

- anemia? *Med Hypotheses*. 2021;146:110413. doi:10.1016/j.mehy.2020.110413
35. Sinadinos A, Shelswell J. Oral ulceration and blistering in patients with COVID-19. *Evid Based Dent*. 2020;21(2):49. doi:10.1038/s41432-020-0100-z
36. Elsayy A, Al-Quthami K, Al-Said HM, Allam R, Al-Qarni A, Shaikh M, et al. Fungal coinfections in COVID-19-positive patients at a tertiary care hospital in Saudi Arabia. *Egypt J Med Microbiol*. 2022;31(3):91–7. doi:10.21608/ejmm.2022.24926