

Review Article

Exploring Therapeutic Outcomes of Photodynamic Therapy: A Case Series Review

Alexander Dushkin^{1*}, Maxim Afanasiev², Tatyana Grishacheva³, Andrey Pylev⁴, Mikhail Burdykov⁴, Irina Dushkina⁵, Alexander Karaulov²

¹The Second Oncology Department, Moscow City Oncology Hospital 62, Moscow, Russian Federation.

²Department of Clinical Immunology and Allergology, Sechenov University, Moscow, Russian Federation.

³Laser Medicine Center, Pavlov University, Saint-Petersburg, Russian Federation.

⁴Centre for Innovative Medical Technologies “European Clinic”, Moscow, Russian Federation.

⁵Surgery Department, “Guta Clinic”, Moscow, Russian Federation.

*E-mail ✉ alex@drdushkin.ru.

Received: 27 April 2021; Revised: 10 September 2021; Accepted: 19 September 2021

ABSTRACT

A contemporary and rapidly developing field for the treatment of a wide range of diseases and ailments is photodynamic therapy. Cytotoxic reactive oxygen species are produced because of a light-mediated photochemical process that activates photosensitizing substances. It is used to treat a variety of oral potentially malignant disorders (OPMDs) as well as periodontal and peri-implant diseases by providing light-activated microbial killing. Photodynamic therapy is a non-invasive, non-toxic, and repeatable procedure that causes no collateral damage. Photodynamic therapy was performed using a low-level diode laser (660 nm at 50 mW) and a photosensitizing dye (1% methylene blue) for one minute. PDT was successful in improving the clinical parameters of cases of periodontitis and peri-implantitis, as well as the overall clinical improvement of symptoms in oral lichen planus cases. These three modalities—management of periodontitis, peri-implantitis, and oral lichen planus—are highlighted in this case series. Therefore, the potential of PDT as a therapy adjunct has been demonstrated.

Keywords: Photodynamic therapy, aPDT, Oral lichen planus, Peri-implantitis, Photosensitizers, Methylene blue

How to Cite This Article: Dushkin A, Afanasiev M, Grishacheva T, Pylev A, Burdykov M, Dushkina I, et al. Exploring Therapeutic Outcomes of Photodynamic Therapy: A Case Series Review. Asian J Periodont Orthodont. 2021;1:27-32.

Introduction

From ancient times to the present, light has been used as a therapeutic tool in the fields of medicine and surgery. A potent medical tool, photodynamic treatment (PDT) is currently widely utilized in several clinical dental specialties.

A medical student from Munich, Germany, named Oscar Raab, observed in 1900 that paramecium was killed by the combination of visible light and acridine dye when oxygen was present [1]. A few years later, in 1904, Munich dermatologists Jesionek and von Tappeiner used the foundation of this therapy to treat a

case of basal cell carcinoma by activating it with light and employing the acidic xanthene dye Eosin as a photosensitizer [2]. By using light sources as a treatment method, Nobel Prize-winning Danish physician Dr. Neil Rayberg Finsen created a new path in the medical sciences. Thomas Dougherty established the International Photodynamic Association in 1986 after conducting fruitful clinical studies for the treatment of cancer in 1978 [3]. In 1999, the Food and Drug Administration authorized PDT's use to treat precancerous lesions.

Since then, PDT has been widely utilized to treat a variety of illnesses, including cancer. When a

particular wavelength of light activates the photosensitizer, photodynamic treatment works selectively [4]. “Light-mediated photochemical reaction involving activation of photosensitizing compound leading to generation of cytotoxic reactive oxygen species” is how Ochsner described photodynamic treatment [5]. Two types of reactions are produced when photosensitizers are activated: type I reactions result in highly reactive oxygen species, whereas type II reactions yield singlet oxygen ($^1\text{O}_2$), which has potent antimicrobial properties and serves as the foundation for antibacterial photodynamic treatment. Because singlet oxygen has a limited radius of action and a brief half-life, it causes oxidative damage to microorganism cells locally [6].

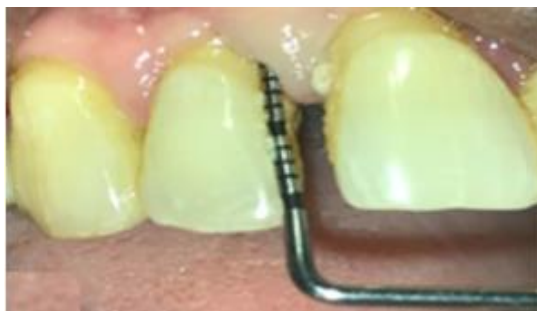The use of aPDT in dentistry began as a method to locally distribute antimicrobial agents to sick periodontal areas when Wilson *et al.* [7] examined the bactericidal impact of photosensitizers. Since then, successful outcomes have been obtained [8]. The literature has extensively demonstrated the use of photodynamic therapy as a beneficial supplement to several mechanical techniques in the treatment of periodontal infections.

Case presentation

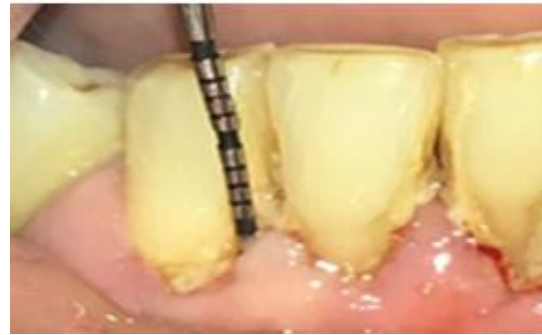Photodynamic treatment has gained a lot of scope as a treatment modality in periodontology. This clinical case presentation provides three distinct disorders that are effectively treated with PDT.

Case 1: PDT as an adjunct to SRP

A 49-year-old man's primary complaints when he first arrived at the periodontology department were bleeding gums and food particles lodged in his teeth for six months. Upon a clinical test, the patient was diagnosed with stage 2 grade B periodontitis after showing positive scores for supragingival plaque, bleeding on probing, suppuration, and CAL of 6 mm in the upper anterior teeth and 5 mm in the lower front teeth (**Figure 1**).



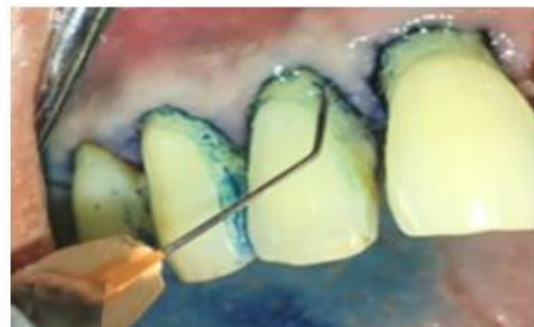
a)



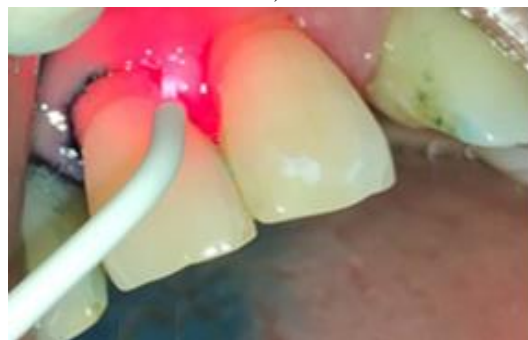b)

Figure 1. a) Pre-op probing depth 6 mm in 12, and b) Pre-op probing depth 5 mm in 43

To reduce the microbial infection load, PDT was used following the first mechanical debridement. Using a blunt needle, 1% methylene blue dye was injected into the sulcus (**Figure 2a**) as a photosensitizer dye. The dye was left there for five minutes to allow the sick tissue to absorb it [9]. The site is irradiated using Helbo®, a low-level diode laser of 660 nm at 50 mW and 100 mV for one minute individually on all six surfaces around each tooth, after being washed with regular saline to remove excess dye (**Figure 2b**).



a)



b)

Figure 2. a) Photosensitizer dye application, and b) Light activation of dye using diode laser

Clinical parameters improved after the patient was recalled every two weeks and underwent a similar procedure with five cycles of PDT, reducing the probing depth from baseline by 5 mm to 3 mm in the upper anterior teeth and by 6 mm to 3 mm in the lower

anterior teeth six months after surgery (**Figure 3**).

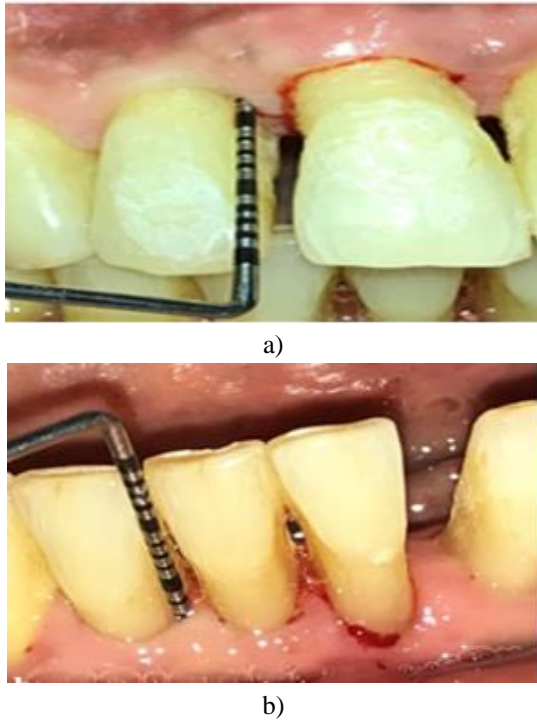


Figure 3. a) Post-op pocket depth reduced to 3 mm in 12, and b) Post-op pocket depth reduced to 3 mm in 43

Case 2: PDT in management of oral lichen planus

For three months, a 31-year-old woman's main complaint was a burning feeling in her mouth that made it impossible for her to eat hot, spicy meals. No pertinent medical or drug history was provided by the patient. During the intraoral clinical presentation, the patient's right cheek mucosa had ulcerated lesions and mild erythema, accompanied by white lacy lines known as Wickham's striae (**Figure 4a**). Histological confirmation was obtained after the case was initially identified as a unilateral atrophic type of oral lichen planus.

PDT was scheduled to manage the lesion. It was possible to accomplish selective absorption by lesion tissue by applying 1% methylene blue to the lesion and 1 cm of the perilesional region, followed by washing to remove excess dye (**Figure 4b**). For 60 seconds, the dye was activated using a diode laser (**Figure 4c**). The third, fifth, seventh, and fourteenth days saw a recurrence of the cycle. After a month, the patient's symptoms significantly decreased, and at the 6-month follow-up, the lesion had significantly resolved (**Figure 4d**).

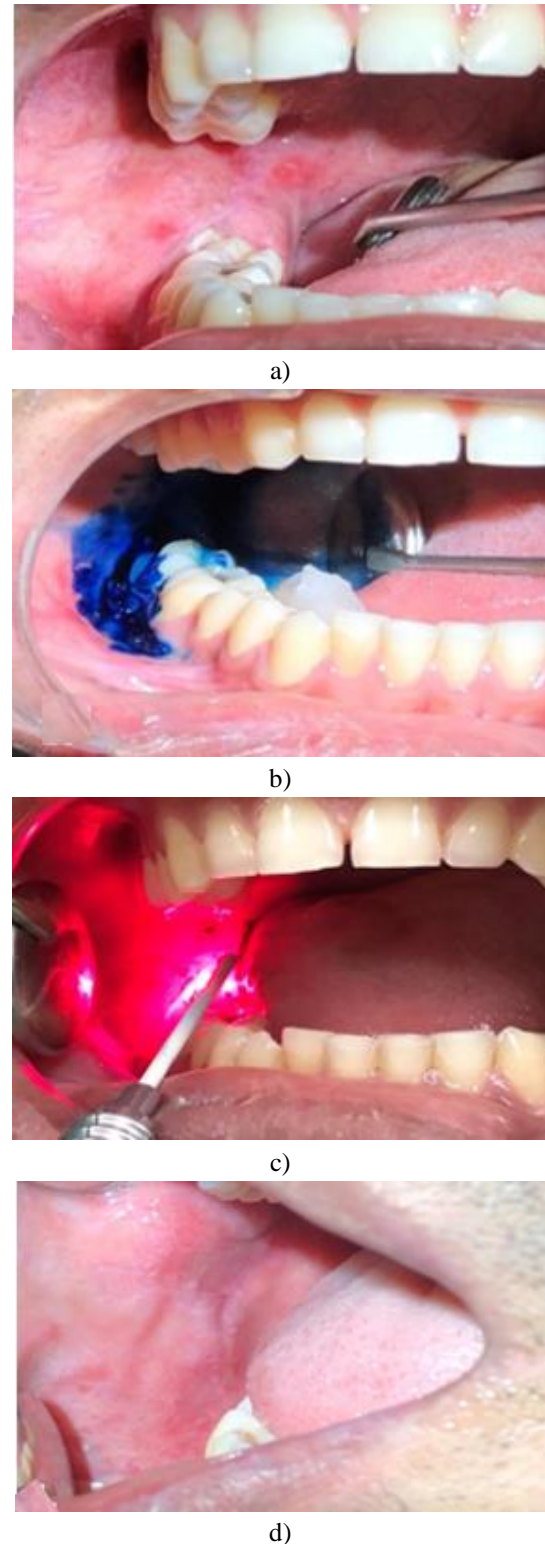


Figure 4. a) Wickham's striae with ulcerated lesions, b) Methylene blue dye application, c) Diode laser activation of dye, and d) Complete resolution of lesion 6 months post-op

Case 3: PDT in management of peri-implantitis

For one month, a 28-year-old man complained of minor discomfort, bleeding gums, and an awful odor coming from his mouth. The patient did not smoke and was in general good health. The dental implant was

placed in the same spot seven months prior, according to the clinical history. Clinical examination revealed irritation, and probing revealed suppuration at the implant site 35i. A 6 mm pocket on the distal side of the implant was discovered by peri-implant probing (**Figure 5a**). The mesial and distal radiolucency on the periapical radiograph indicated peri-implant bone loss that extended to the middle third of the implantation (**Figure 5b**). The diagnosis of moderate peri-implantitis 35i was made according to radiological and clinical results [10].

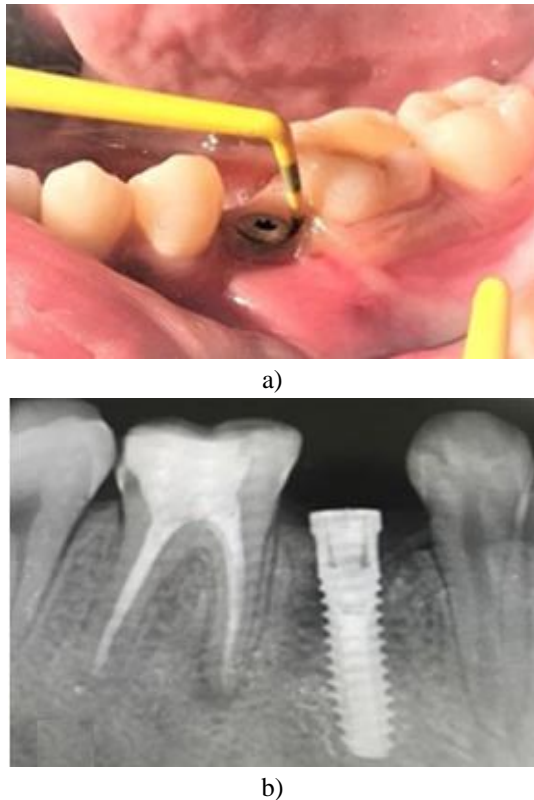


Figure 5. a) Peri-implant probing showing 6 mm of pocket, and b) Peri-implant radiolucency in IOPA

By lifting the full-thickness flap, the defect was surgically explored, and titanium curettes were used to debride the surgical site. Following debridement and before graft implantation, aPDT was applied to the peri-implant region using methylene blue dye, which provided anti-infective treatment and decontaminated the implant surface (**Figure 6a**). Particulate xenograft and resorbable membrane regeneration treatment came next, and 5-0 polypropylene sutures were used to reapproximate the flap. To remove the sutures, the patient was prescribed analgesics and antibiotics, which were recalled after ten days. An intraoral radiograph taken six months after surgery showed peri-implant bone fill, indicating that photodynamic antimicrobial treatment had been successful (**Figure 6b**). After six months, the implant was repaired with a

cement-retained PFM crown after a temporary crown was positioned and maintained under occlusion.

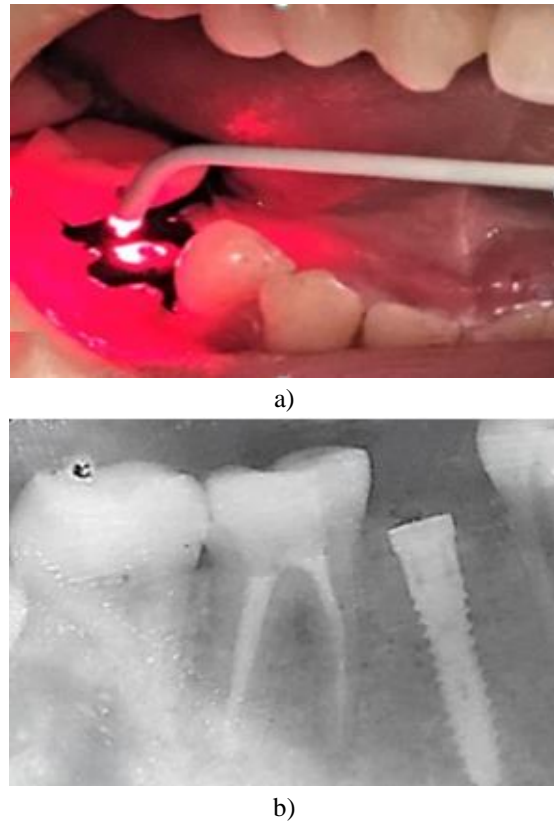


Figure 6. a) PDT on peri-implant surgical site, and b) 6-month post-op IOPA

Results and Discussion

As a groundbreaking therapeutic approach, photodynamic therapy has been used in dentistry and other medical specialties. It is now used to treat premalignant disorders such as peri-implantitis, endodontic lesions, periodontal diseases, and oral submucous fibrosis.

The current case series presents three distinct instances that demonstrate the therapeutic value of photodynamic treatment. Based on photodynamic antimicrobial chemotherapy, or PACT, PDT is used as an adjuvant technique to treat periodontitis. The core of treating periodontal disease is removing the biofilms of dental plaque that cause it. Photosensitizer-activated low-level lasers that employ singlet oxygen to produce antibacterial activity can kill periodontopathic bacteria. PDT offers the additional benefits of improved local effectiveness and avoidance of the emergence of antibiotic resistance. According to several systematic evaluations, there are therapeutic advantages to using aPDT in addition to nonsurgical periodontal therapy [11]. Though it is not advised to employ PDT as a mainstay in the clinical care of periodontitis and cannot

replace SRP, the evidence does support its use as an adjuvant therapy [12].

PDT has demonstrated therapeutic efficacy in treating potentially cancerous conditions of the mouth, such as oral lichen planus [13]. PDT's ability to treat oral lichen planus has been the subject of several investigations in recent years. PDT was proposed by Aghahosseini *et al.* [14] as an alternate therapy approach in 13 patients, and lesions were shown to resolve. In some atrophic types of oral lichen planus, PDT has been shown to provide superior outcomes in reducing the clinical sensations of burning and even discomfort. PDT is just as effective as topical corticosteroids, which are the gold standard for treating OLP's painful lesions. It also has the added advantage of preventing the negative consequences of long-term steroid usage [15]. Again, using a diode laser to treat OLP produced a greater clinical response in terms of VAS. Low-level laser treatment provides a dependable substitute for corticosteroids, according to a 2015 systematic review and meta-analysis by Jajarm *et al.*

Because peri-implantitis is a condition linked to the risk of dental implant failures, it is also a clinical problem. Peri-implantitis is mostly caused by the buildup of biofilm around the mucosal edges of implants. The problem is made considerably more difficult by the presence of gram-negative anaerobic bacteria in and around the implant in peri-implantitis. Nonetheless, several clinical trials were conducted to determine if antibiotic photodynamic treatment (aPDT) is efficient in reducing the bioburden and, consequently, in accomplishing successful implant surface cleansing [16]. A photosensitizer, like methylene blue, can attach itself to the cells it is intended to target and, when activated, combine with the substrate to generate highly reactive singlet oxygen that is poisonous to microbes. When treating peri-implantitis and periodontitis, PDT is a good substitute for antibiotics because it is highly unlikely to cause any type of bacterial resistance [17].

Conclusion

Numerous therapeutic applications of photodynamic therapy have been demonstrated in this case series. PDT worked well as a stand-alone treatment for oral lichen planus, and it can be used as a supplement to scaling and root planning in periodontitis patients. PDT is a targeted, noninvasive therapy approach that produces the intended outcomes without triggering negative side effects. Systemic toxicity and, more crucially, the development of antibiotic resistance are avoided by the localization of the medication and the selective absorption of photosensitizer. Because of this,

PDT is the way of the future for periodontal treatment. However, cost and photosensitivity limitations continue to restrict its usage, necessitating extensive clinical trials to make PDT a cornerstone in the management of periodontal disorders.

Acknowledgments: Our acknowledgment extends to the Department of Dental Surgery, Armed Forces Medical College, Pune.

Conflict of Interest: None

Financial Support: None

Ethics Statement: All the treatment performed was following the principles embodied in the Declaration of Helsinki and under local statutory requirements as per department protocol and written consent was obtained from each patient.

References

1. Hamblin MR, Huang Y. Handbook of photomedicine. Boca Raton FL: Taylor & Francis; 2013. 6 p. Available from: https://books.google.co.in/books?id=kBDSBQA AQBAJ&printsec=frontcover&source=gbs_ge_summary_r&cad=0#v=onepage&q&f=false
2. Von Tappeiner H, Jesionek A. Therapeutische versuche mit fluoreszierenden stoffen. Munch Med Wochenschr. 1903;(47):2042-4.
3. Dougherty TJ, Marcus SL. Photodynamic therapy. Eur J Cancer. 1992;28A(10):1734-42.
4. López-Marín N, Mulet R. In silico modelling of apoptosis induced by photodynamic therapy. J Theor Biol. 2018;436:8-17.
5. Ochsner M. Photophysical and photobiological processes in the photodynamic therapy of tumours. J Photochem Photobiol B. 1997;39(1):1-8.
6. Rajesh S, Koshi E, Philip K, Mohan A. Antimicrobial photodynamic therapy: an overview. J Indian Soc Periodontol. 2011;15(4):323.
7. Wilson M, Dobson J, Harvey W. Sensitization of oral bacteria to killing by low-power laser radiation. Curr Microbiol. 1992;25(2):77-81.
8. Matevski D, Weersink R, Tenenbaum HC, Wilson B, Ellen RP, Lepine G. Lethal photosensitization of periodontal pathogens by a red-filtered xenon lamp in vitro. J Periodontal Res. 2003;38(4):428-35.
9. Seal GJ, Ng YL, Spratt D, Bhatti M, Gulabivala K. An in vitro comparison of the bactericidal efficacy of lethal photosensitization or sodium

- hypochlorite irrigation on streptococcus intermedius biofilms in root canals. *Int Endod J*. 2002;35(3):268-74.
10. Froum SJ, Rosen PS. A proposed classification for peri-implantitis. *Int J Periodontics Restorative Dent*. 2012;32(5):533.
11. Kikuchi T, Mogi M, Okabe I, Okada K, Goto H, Sasaki Y, et al. Adjunctive application of antimicrobial photodynamic therapy in nonsurgical periodontal treatment: a review of literature. *Int J Mol Sci*. 2015;16(10):24111-26.
12. Azarpazhooh A, Shah PS, Tenenbaum HC, Goldberg MB. The effect of photodynamic therapy for periodontitis: a systematic review and meta-analysis. *J Periodontol*. 2010;81(1):4-14.
13. Jin X, Xu H, Deng J, Dan H, Ji P, Chen Q, et al. Photodynamic therapy for oral potentially malignant disorders. *Photodiagnosis Photodyn Ther*. 2019;28:146-52.
14. Aghahosseini F, Arbabi-Kalati F, Fashtami LA, Djavid GE, Fateh M, Beitollahi JM. Methylene blue-mediated photodynamic therapy: a possible alternative treatment for oral lichen planus. *Lasers Surg Med*. 2006;38(1):33-8. doi:10.1002/lsm.20278
15. He Y, Deng J, Zhao Y, Tao H, Dan H, Xu H, et al. Efficacy evaluation of photodynamic therapy for oral lichen planus: a systematic review and meta-analysis. *BMC Oral Health*. 2020;20(1):1-0.
16. Fraga RS, Antunes LA, Fontes KB, Küchler EC, Iorio NL, Antunes LS. Is antimicrobial photodynamic therapy effective for microbial load reduction in peri-implantitis treatment? A systematic review and meta-analysis. *Photochem Photobiol*. 2018;94(4):752-9.
17. Zhao Y, Pu R, Qian Y, Shi J, Si M. Antimicrobial photodynamic therapy versus antibiotics as an adjunct in the treatment of periodontitis and peri-implantitis: a systematic review and meta-analysis. *Photodiagnosis Photodyn Ther*. 2021;34(Suppl. 1):102231.