

Original Article

## Morphology and Classification of Lingual Foramina in Human Mandibles: Observational Insights for Surgery

Emma Bernard<sup>1\*</sup>, Louis Dubois<sup>2</sup>

<sup>1</sup>Department of Prosthesis and Implantology, School of Dental Medicine, Aix-Marseille University, 13005 Marseille, France.

<sup>2</sup>Institut de Recherche de Chimie Paris, Chimie ParisTech—CNRS, PSL Research University, 75005 Paris, France.

\*E-mail ✉ [emmabernard88@gmail.com](mailto:emmabernard88@gmail.com)

Received: 17 December 2024; Revised: 28 February 2025; Accepted: 03 March 2025

### ABSTRACT

The mandible contains lingual foramina through which small arterial branches pass, making them vulnerable to injury during surgical procedures and potentially causing bleeding complications. This study aimed to map and categorize lingual foramina in dry cadaveric mandibles to provide practical anatomical information for minimizing perioperative hemorrhage. One hundred dry mandibles were examined to determine the number, size, and location of lingual foramina in relation to key landmarks: the genial tubercle, alveolar ridge, and alveolar process. Measurements were obtained using stainless steel wires and digital calipers. Cluster analysis grouped the foramina according to spatial patterns, while one-way ANOVA assessed differences in size across groups.

Lingual foramina with a diameter of  $\geq 2$  mm were observed in 96 mandibles, totaling 387 foramina (average 4.03 per mandible), while four mandibles had smaller foramina. Single foramina were rare (4.2%), and most mandibles had multiple openings (up to nine). The average diameter was  $0.44 \pm 0.02$  mm. Distances from the genial tubercle, alveolar crest, and inferior mandibular border were  $8.74 \pm 0.54$  mm,  $14.19 \pm 0.87$  mm, and  $14.53 \pm 0.84$  mm, respectively. Foramina were classified relative to the genial tubercle as right (7%), proximal (66%), superior (21%), or left (6%), with the superior group showing the largest mean diameter ( $0.52 \pm 0.22$  mm,  $p < 0.001$ ). The lowest probability of encountering a foramen occurred at  $13.0 \pm 0.5$  mm from the genial tubercle, indicating a safer region for surgical intervention. This detailed anatomical mapping of lingual foramina provides valuable information for preoperative planning and surgical safety in mandibular procedures, helping to reduce the risk of intraoperative bleeding.

**Keywords:** Mandible, Lingual foramen, Genial tubercle, Alveolar ridge, Alveolar process

**How to Cite This Article:** Bernard E, Dubois L. Morphology and Classification of Lingual Foramina in Human Mandibles: Observational Insights for Surgery. *Int J Dent Res Allied Sci.* 2025;5(1):97-104. <https://doi.org/10.51847/Dq1ARVF12Z>

### Introduction

The internal anatomy of the mandible is highly complex, featuring a network of canals that transmit arteries, veins, and nerves essential for the vascular and neural support of the jaw and dentition. Major arterial branches, including those from the sublingual, subgenial, and mylohyoid arteries, access the mandible through small openings on its posterior aspect, typically located near the first premolars. These

openings are collectively referred to as the lingual foramina.

Lingual foramina are commonly divided into two categories based on their anatomical position: median lingual foramina (MLF) and lateral lingual foramina (LLF). The median foramina can be further classified as superior (s-MLF) or inferior (i-MLF) relative to the genial tubercle. Each foramen is associated with a vascular canal, known as a lingual vascular canal (LC), which may also be categorized as median (MVC) or lateral (LVC) [1].

The superior median lingual foramen has been the focus of most clinical studies due to its frequent involvement in surgical complications. In contrast, smaller foramina located in the interpremolar region have often been overlooked, likely because their small size complicates detection on imaging modalities such as cone-beam computed tomography (CBCT). As a result, these foramina are often underestimated in both prevalence and clinical importance [1–3].

Vascular branches passing through lingual foramina are typically 0.2–1 mm in diameter. These vessels are at risk during surgical interventions in the floor of the mouth or anterior mandible. Injuries can result in hemorrhage ranging from minor bleeding to significant hematomas capable of airway obstruction. Even minor bleeding may compress adjacent nerves, leading to ischemia and sensory disturbances in teeth and gingival tissue [1].

The present study aimed to provide a detailed anatomical assessment of lingual foramina in dry mandibles. Objectives included quantifying the foramina, classifying them based on anatomical relationships, mapping their positions relative to landmarks such as the genial tubercle, alveolar ridge, and alveolar process, and identifying regions associated with lower bleeding risk. These data are intended to guide surgeons in preoperative planning and reduce intraoperative complications.

## Materials and Methods

### *Specimens*

This study examined 100 dry human mandibles curated in the Laboratory of Anatomy, Department of Medicine, Democritus University of Thrace, Greece. The specimens originated from an unspecified Greek population, and no information regarding age or sex was available. Dentate mandibles were required to retain at least one intact alveolus. Mandibles with structural damage, erosion, or deformities were excluded to ensure accuracy in anatomical assessment. The analysis focused on the number, size, and spatial relationships of lingual foramina with respect to the genial tubercle and alveolar process. Additionally, the position of the genial tubercle on the posterior mandibular surface was recorded.

Methodological quality and the risk of bias were evaluated using the Anatomical Quality Assessment (AQUA) tool [4]. Ethical approval was not necessary, as only cadaveric specimens were utilized.

### *Measurement protocol*

The study focused on evaluating the presence, size, and precise positioning of lingual foramina in dry

mandibles, as well as their spatial relationships with key anatomical landmarks: the genial tubercle, the alveolar ridge, and the inferior border of the mandible. Only foramina situated on the posterior region of the mandible, between the first premolars, were considered for inclusion.

Foramina were identified through direct visual inspection of the lingual surface under natural lighting conditions. The diameter of each foramen was measured using a series of flexible stainless-steel wires with incremental diameters ranging from 0.2 mm to 1.2 mm (increments of 0.1 mm; UA218893, Zhejiang, China), following established measurement methods [5]. Foramina smaller than 0.2 mm were excluded from the analysis. When a wire could not pass fully through a foramen, the closest smaller diameter was recorded, resulting in a maximum possible measurement error of 0.1 mm. The mean relative error was determined by averaging the ratio of measurement error to measured diameter across all foramina.

All linear distances were measured with a Digimatic caliper (Mitutoyo Co., Kawasaki, Kanagawa, Japan) accurate to 0.01 mm. Foramina positions were determined relative to the genial tubercle, which served as the origin of two imaginary perpendicular axes dividing the lingual surface into four quadrants: anterior superior, anterior inferior, posterior superior, and posterior inferior.

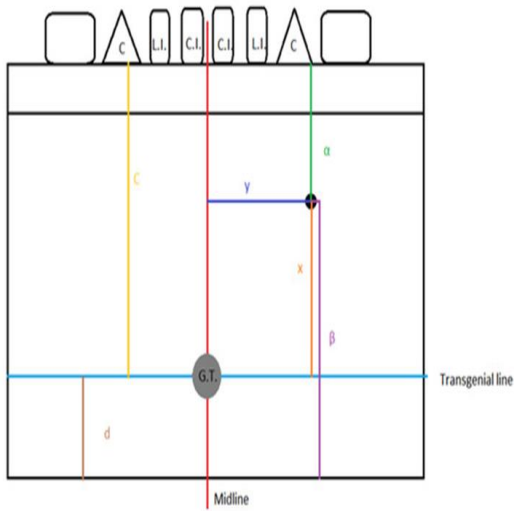
The following parameters were recorded for each foramen:

- *Vertical distance (x)*: from the genial tubercle to the foramen.
- *Horizontal distance (y)*: from the genial tubercle to the foramen.
- *Radial distance (r)*: calculated as  $\sqrt{(x^2 + y^2)}$ , representing the straight-line distance from the genial tubercle.
- Distance to alveolar ridge/superior border ( $\alpha$ ).
- Distance to inferior border of the mandible ( $\beta$ ).

The location of the genial tubercle itself was also assessed by measuring:

- Distance to the alveolar ridge/superior border (c).
- Distance to the inferior mandibular border (d) (**Figure 1**).

This methodology allowed a detailed mapping of lingual foramina in relation to key landmarks, facilitating surgical planning and identifying regions with higher risk for intraoperative bleeding.



**Figure 1.** Measurements protocol; x: height; y: length;  $\alpha$ : foramen–alveolar ridge/superior border distance;  $\beta$ : foramen–inferior border distance; c: genial tubercle–alveolar ridge/superior border distance; d: genial tubercle–inferior border distance.

We established the *transgenial line* as a horizontal reference passing through the midpoint of the genial tubercle, independent of its shape or morphology. For mandibles with remaining teeth, the top edge of the alveolar process was utilized as a landmark. In edentulous specimens, the superior border of the mandible served as the reference for locating both the lingual foramina and the genial tubercle. Comparative analyses were performed to examine potential differences between dentate and edentulous mandibles.

#### Study quality assessment

The study's methodological quality was evaluated using the Anatomical Quality Assessment (AQUA) tool. Domain 1, concerning the objectives and characteristics of the specimens, was classified as high risk due to the absence of cadaveric information such as age, sex, and medical history. All other domains—study design, methodological description, anatomical observations, and reporting of results—were judged as low risk, suggesting reliable data collection and analysis.

#### Statistical approach

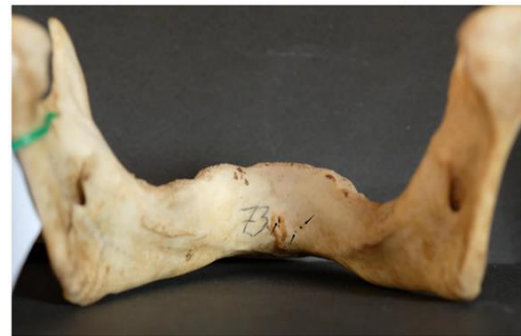Continuous measurements were reported as means with standard errors and compared using Student's t-test for equal variances or Welch's t-test when variances were unequal. Categorical variables were expressed as percentages and evaluated using chi-square tests, with Fisher's exact test applied where expected frequencies were low. Chi-square analysis was additionally used to examine the distribution of

foramina across designated quadrants. Cluster comparisons were conducted using one-way ANOVA followed by Tukey's HSD post hoc test. To categorize lingual foramina according to their orientation and proximity to the genial tubercle, a two-step cluster analysis was implemented. Statistical significance was defined as  $p < 0.05$ , and all analyses were two-tailed, conducted using SPSS version 26.0.

## Results and Discussion

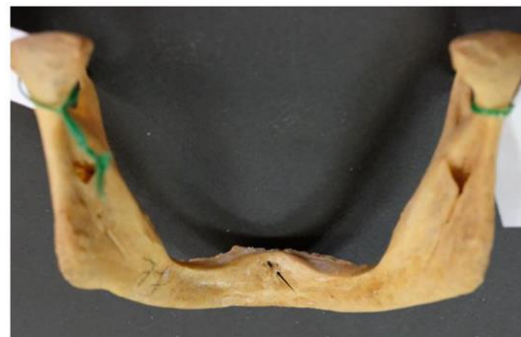### Overview of observations

Among the 100 mandibles examined, four specimens had lingual foramina smaller than 2 mm in diameter and were excluded from detailed analysis. The remaining 96 mandibles, consisting of 50 dentate and 46 edentulous specimens, contained a total of 387 lingual foramina, with an average of 4.03 per mandible. Measurements indicated that the genial tubercle was located at a mean distance of  $15.27 \pm 1.11$  mm from the alveolar ridge and  $14.42 \pm 0.37$  mm from the inferior border of the mandible (**Figure 2**).



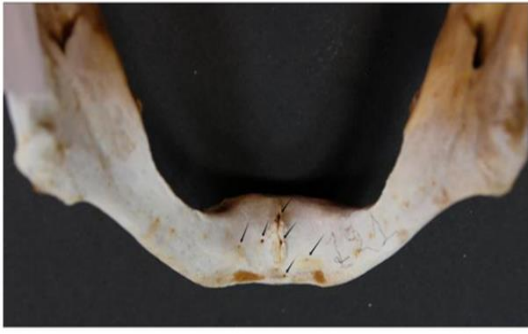**Figure 2.** A typical dry mandible; lingual foramina are indicated by arrows.

Out of the 96 mandibles analyzed, 4 (4.2%) had a single lingual foramen (**Figure 3**).

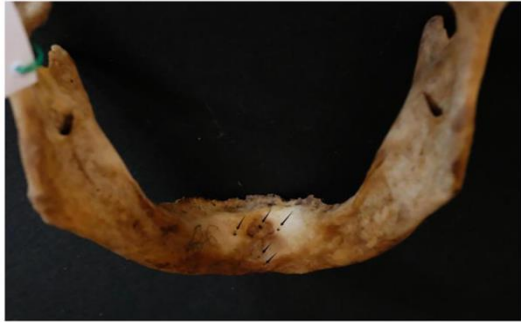

**Figure 3.** Single lingual foramen (arrow).

The majority of the mandibles examined (92; 95.8% of the sample) had multiple lingual foramina (up to nine) (**Figures 4 and 5**).

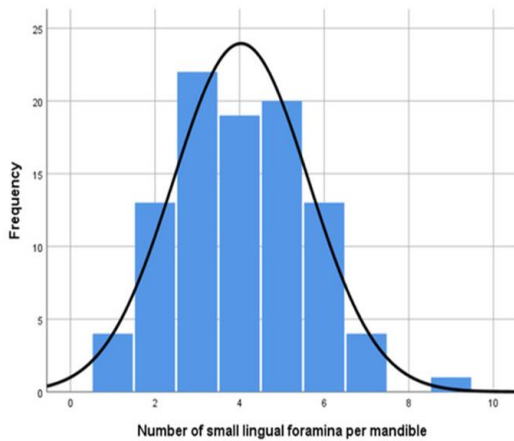


**Figure 4.** Multiple (six) lingual foramina indicated by arrows.



**Figure 5.** Multiple (five) lingual foramina indicated by arrows.

The distribution of the number of lingual foramina among the mandibles examined is depicted in **Figure 6**.



**Figure 6.** Histogram depicting the number of lingual foramina per mandible in the study sample; the y-axis represents count.

The lingual foramina displayed considerable variability in size, ranging from 0.2 mm up to 1.5 mm, with an overall mean diameter of  $0.44 \pm 0.02$  mm. The calculated mean relative measurement error was approximately 21% (95% CI: 20.2–21.8%), indicating a moderate level of uncertainty in the precision of these measurements.

Regarding their anatomical positioning, the foramina were situated on average  $8.74 \pm 0.54$  mm from the genial tubercle, with vertical and horizontal components of  $7.57 \pm 0.56$  mm and  $4.24 \pm 0.54$  mm, respectively. Their mean distances from the alveolar ridge and the inferior mandibular border were  $14.19 \pm 0.87$  mm and  $14.53 \pm 0.84$  mm.

Distribution patterns revealed a higher number of foramina on the left side of the mandible compared to the right (218 vs. 169;  $p = 0.013$ ). When examining vertical placement relative to the genial tubercle, no significant difference was observed between superior and inferior locations (196 vs. 191;  $p = 0.799$ ). Overall, smaller foramina were most commonly located in the upper-left quadrant in reference to the genial tubercle ( $p = 0.043$ ) (**Table 1**).

**Table 1.** Goodness-of-fit chi-square test between frequencies in quadrants.

Foramina Location	n (%)	p-Value
Left superior quadrant	117 (30.2)	0.043
Right superior quadrant	79 (20.4)	
Left inferior quadrant	101 (26.1)	
Right inferior quadrant	90 (23.3)	

Overall, the 25%, 50%, 75%, and 90% of lingual foramina could be traced at distances of 4.56, 9.03, 16.56, and 20.86 mm, respectively; these distances vary according to the quadrant (**Table 2**).

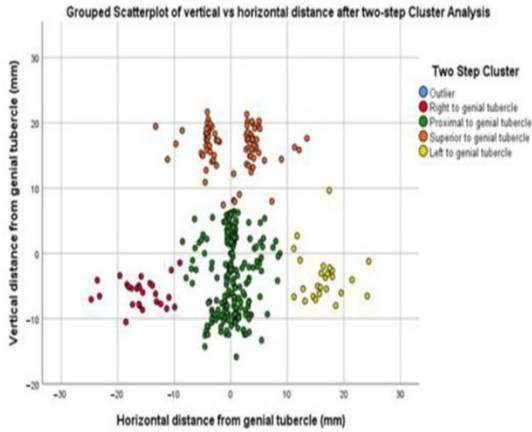
**Table 2.** Distances in mm from genial tubercle that contain lingual foramina at a given probability/odds ratio; data for all (2nd column), above genial tubercle (3rd column), and below genial tubercle (4th column).

Probability/OR for a Foramen to Be Included in the Zone	All Lingual Foramina; mm (n = 387)	Lingual Foramina Above Genial Tubercle; mm (n = 196)	Lingual Foramina Below Genial Tubercle; mm (n = 191)
25%/0.33	4.56	5.45	3.69
50%/1.00	9.03	8.20	5.93
75%/3.00	16.56	10.03	17.22
95%/19.00	20.86	12.73	20.56

*Clustering of small lingual foramina identifies a safer zone for surgery*

Given the observed differences in foramina distribution across mandibular quadrants, we conducted a more detailed analysis to explore potential subgroups within both median and lateral lingual foramina and to characterize their spatial patterns.

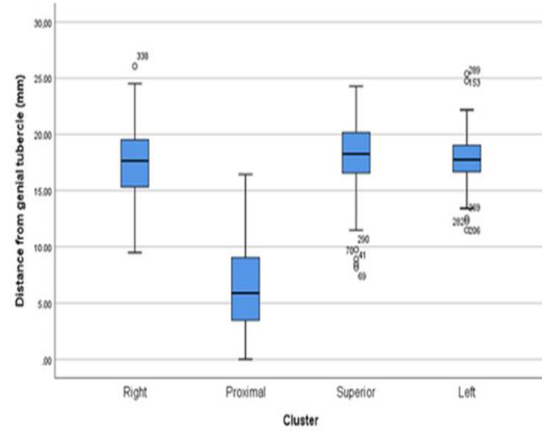
A scatterplot was generated illustrating the vertical and horizontal distances of the small lingual foramina relative to the genial tubercle (**Figure 7**). Using two-step cluster analysis, four distinct clusters emerged from the 387 small foramina examined. These clusters were categorized as follows: (i) lateral foramina on the right side of the genial tubercle (R-LLF), (ii) median foramina located near the genial tubercle (P-MLF), (iii) median foramina positioned superiorly above the genial tubercle (S-MLF), and (iv) lateral foramina on the left side of the genial tubercle (L-LLF).



**Figure 7.** Grouped scattergram depicting vertical vs. horizontal distance of small lingual foramina

from genial tubercle after two-step cluster analysis: four discrete clusters determine a relatively safe, lower “bleeding risk zone” amongst them.

Distances from the genial tubercle are provided in **Figure 8**.



**Figure 8.** Distance from genial tubercle per cluster.

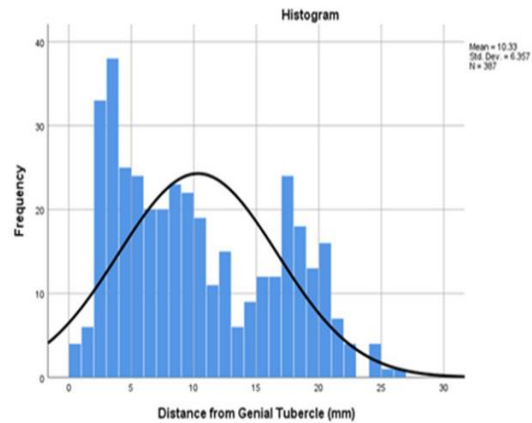
**Table 3** summarizes the specific features of the small lingual foramina within each cluster. Notably, foramina in the superior cluster exhibited significantly larger diameters compared with those in the right ( $p = 0.008$ ), proximal ( $p < 0.001$ ), and left ( $p = 0.022$ ) clusters.

**Table 3.** Small lingual foramina characteristics per cluster.

Measurement	Right (R-LLF) (n = 27)	Proximal (P-MLF) (n = 254)	Superior (S-MLF) (n = 81)	Left (L-LLF) (n = 25)	p-Value
Width (mm)	0.39 ± 0.10	0.42 ± 0.19	0.52 ± 0.22	0.40 ± 0.16	<0.001
Vertical Height (mm)	6.41 ± 2.10	5.61 ± 3.52	16.97 ± 3.12	5.01 ± 2.39	<0.001
Length (mm)	16.26 ± 3.99	2.18 ± 2.02	4.89 ± 2.55	16.82 ± 3.52	<0.001
Distance to Genial Tubercle (mm)	17.64 ± 3.81	6.43 ± 3.67	17.83 ± 3.24	17.72 ± 3.48	<0.001
Distance to Alveolar Ridge (mm)	22.88 ± 5.70	16.62 ± 7.13	4.12 ± 4.61	19.50 ± 6.37	<0.001
Distance to Inferior Border (mm)	9.71 ± 2.37	11.90 ± 5.39	27.79 ± 5.35	10.21 ± 3.84	<0.001

Of note, 6/387 (1.8 %) foramina presented a diameter  $\geq 1.0$  mm (3 proximal; 3 superior).

Of note, a bimodal distribution of foramen distances from the genial tubercle is observed. The first mode is between 3.00–4.00 mm, corresponding to the proximal cluster. The second mode is between 17.00–18.00 mm, corresponding to the right, superior, and left clusters. An interstitial, relatively safe “bleeding risk zone” lies between  $13.00 \pm 0.50$  mm (**Figure 9**).



**Figure 9.** Histogram depicting bimodal distribution of foramen distances from genial tubercle; the y-axis represents count.

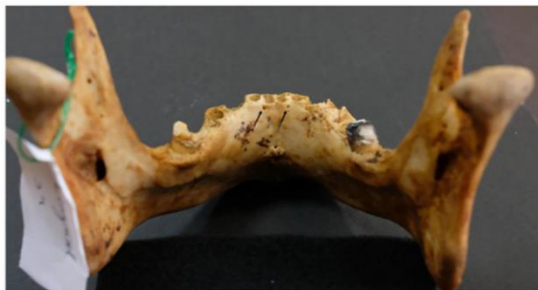*Differences between dentate and edentulous mandibles*  
A detailed comparison between dentate and edentulous mandibles is provided in **Table 4**.

Here is the paraphrased table with the same structure and data, reworded for clarity while preserving the original values and format:

**Table 4.** Descriptive statistics and comparison between dentate and edentulous mandibles; values are expressed in mm.

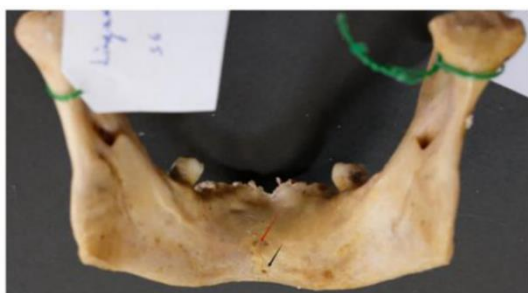Parameter	All Mandibles (n = 96)	Dentate Mandibles (n = 50)	Edentulous Mandibles (n = 46)	p-Value
<b>Foramina Number</b>				
Per mandible (mean ± SE)	4.03 ± 0.16	4.54 ± 0.23	3.48 ± 0.20	0.001
<b>Foramina Location (n)</b>				
Right cluster (R-LLF)	27	20	7	<0.001
Proximal cluster (P-MLF)	254	122	132	
Superior cluster (S-MLF)	81	69	12	
Left cluster (L-LLF)	25	16	9	
<b>Foramina Characteristics (mean ± SE)</b>				
Width (mm)	0.44 ± 0.02	0.45 ± 0.01	0.43 ± 0.02	0.094
Vertical Height (mm)	7.57 ± 0.56	8.81 ± 0.42	5.80 ± 0.30	<0.001
Length (mm)	4.24 ± 0.54	5.03 ± 0.39	3.11 ± 0.34	0.002
Distance to Genial Tubercle (mm)	8.74 ± 0.54	12.02 ± 0.46	7.93 ± 0.36	<0.001
Distance to Alveolar Ridge (mm)	14.19 ± 0.87	15.46 ± 0.64	12.38 ± 0.53	<0.001
Distance to Inferior Border (mm)	14.53 ± 0.84	16.79 ± 0.59	11.31 ± 0.48	<0.001

Lingual foramina that were close to the alveolar ridge (**Figure 10**) were usually more detected in dentate mandibles, when compared to edentulous ones.



**Figure 10.** Lingual foramen detected in alveolar position (arrows).

Interestingly, only one mandible had no central genial lingual foramen (**Figure 11**).



**Figure 11.** Mandible lacking central genial lingual foramina (arrows).

This observational study offers a comprehensive evaluation of all lingual foramina measuring  $\geq 0.2$  mm in dry mandibles, using stainless-steel wires—a method not previously reported in cadaveric investigations. Our focus on cadaveric specimens, rather than relying on CBCT imaging, was motivated by two considerations: CBCT tends to have limited sensitivity in detecting small lingual foramina, and the associated lingual ducts may be larger than the bony openings, making them clinically more relevant. Interestingly, our findings regarding the mean number of lingual foramina per mandible (4.03) align with recently reported CBCT data [6].

Bernardi *et al.*, in their meta-analysis, indicated that diameters obtained from cadaveric specimens and CBCT are comparable; however, the pooled mean diameter from previous reports (0.84 mm) was nearly double that observed in this study (0.44 mm), likely reflecting methodological differences [7]. Small foramina ( $< 3$  mm) are difficult to visualize on CBCT but are readily assessed in dry mandibles, highlighting the potential for preoperative imaging to underestimate bleeding risk.

Contrary to prior studies suggesting that edentulism does not alter foramina morphology, we observed significant differences between dentate and edentulous mandibles regarding distances from key landmarks, including the genial tubercle, alveolar ridge, and inferior mandibular border [3]. While large lingual

foramina ( $\geq 1.0$  mm) are uncommon, their proximity to the midline poses a tangible risk of vascular and neural injury during anterior mandibular surgery. These foramina contain neurovascular bundles that, if damaged, can result in bleeding or neurosensory disturbances affecting mandibular teeth and gingivae [8].

An understanding of lingual foramina anatomy is critical for a range of anterior mandibular procedures, including periapical surgery, genioplasty, implant placement, treatment of symphyseal fractures, preprosthetic surgeries, grafting, and cyst or lesion removal [1, 9, 10]. These accessory foramina have also been implicated in regional tumor spread [11, 12].

Despite the routine placement of implants in the symphyseal region, severe complications—including sublingual hematoma formation—have been documented due to injury to branches of the sublingual and submental arteries, which connect to the central inferior alveolar vessels [13–21]. Such events may necessitate hospitalization and emergency airway management (e.g., intubation or tracheostomy) [16–21].

Preoperative imaging, particularly CBCT, remains crucial for identifying the size and location of lingual foramina, facilitating surgical planning and minimizing intraoperative risks. In our study, distances from the foramina to the alveolar crest and inferior border were recorded, with the latter considered more reliable due to its stability irrespective of edentulism or alveolar resorption [22–24]. Alveolar bone resorption can shift the relative position of medial lingual foramina, heightening the risk of vascular injury during implant placement, even with short implants [23, 24]. CBCT imaging offers superior accuracy in identifying small accessory foramina, underscoring its value in preoperative planning [25].

A key strength of this study is the use of cluster analysis to categorize lingual foramina and explore their characteristics—a novel approach in the field. While the use of stainless-steel wires may introduce a minor bias, with measured diameters slightly underestimated (absolute error  $< 0.1$  mm), the intraclass correlation coefficient between observers was exceptionally high (0.987–1.000) [5]. Limitations include potential reporting bias for rare anatomical variants, such as multiple ( $> 8$ ) foramina or absence of a central foramen [26], as well as the lack of age- and sex-specific data [27], although CBCT studies suggest minimal sex- or age-based differences in foramina number [3]. The absence of a direct comparison with CBCT data on the same specimens represents another limitation,

warranting further research to validate the clinical implications of these findings.

## Conclusion

This study enhances understanding of lingual foramina anatomy, providing critical data for preoperative planning and strategies to reduce complications during mandibular surgery. The findings underscore the importance of careful anatomical assessment, particularly in anterior mandibular procedures, to mitigate risks of vascular injury and postoperative hemorrhage.

**Acknowledgments:** None

**Conflict of Interest:** None

**Financial Support:** None

**Ethics Statement:** None

## References

1. He P, Truong MK, Adeeb N, Tubbs RS, Iwanaga J. Clinical anatomy and surgical significance of the lingual foramina and their canals. *Clin Anat.* 2017;30(2):194–204.
2. Murlimanju BV, Prakash KG, Samiullah D, Prabhu LV, Pai MM, Vadgaonkar R, et al. Accessory neurovascular foramina on the lingual surface of mandible: Incidence, topography, and clinical implications. *Indian J Dent Res.* 2012;23(3):433–7.
3. Silvestri F, Nguyen JF, He O, Mense C. Lingual foramina of the anterior mandible in edentulous patients: CBCT analysis and surgical risk assessment. *Ann Anat.* 2022;244(1):151982.
4. Henry BM, Tomaszewski KA, Ramakrishnan PK, Roy J, Vikse J, Loukas M, et al. Development of the anatomical quality assessment (AQUA) tool for the quality assessment of anatomical studies included in meta-analyses and systematic reviews. *Clin Anat.* 2017;30(1):6–13.
5. Thomaidi ZM, Tsatsarelis C, Papadopoulos V. Accessory mental foramina in dry mandibles: An observational study along with systematic review and meta-analysis. *Dent J.* 2025;13(4):94.
6. Thambi TJRD, Aswath N. Evaluation of lingual foramen in the South Indian population using cone-beam computed tomography: A prospective cross-sectional study. *J Pharm Bioallied Sci.* 2024;16(Suppl S2):S1140–6.

7. Bernardi S, Bianchi S, Continenza MA, Macchiarelli G. Frequency and anatomical features of the mandibular lingual foramina: Systematic review and meta-analysis. *Surg Radiol Anat.* 2017;39(12):1349–57.
8. Przystanska A, Bruska M. Foramina on the internal aspect of the alveolar part of the mandible. *Folia Morphol (Warsz).* 2005;64(2):89–91.
9. Liang X, Jacobs R, Lambrechts I, Vandewalle G. Lingual foramina on the mandibular midline revisited: A macroanatomical study. *Clin Anat.* 2007;20(3):246–51.
10. Sanchez-Perez A, Boix-Garcia P, Lopez-Jornet P. Cone-beam CT assessment of the position of the medial lingual foramen for dental implant placement in the anterior symphysis. *Implant Dent.* 2018;27(1):43–8.
11. McGregor JA, MacDonald DG. Patterns of spread of squamous carcinoma within the mandible. *Head Neck Surg.* 1989;11(6):457–61.
12. Fanibunda K, Matthews JN. The relationship between accessory foramina and tumour spread on the medial mandibular surface. *J Anat.* 2000;196(1):23–9.
13. Dubois L, de Lange J, Baas E, van Ingen J. Excessive bleeding in the floor of the mouth after endosseous implant placement: A report of two cases. *Int J Oral Maxillofac Surg.* 2010;39(4):412–5.
14. Jo J, Kim S, Oh J. Hemorrhage related to implant placement in the anterior mandible. *Implant Dent.* 2011;20(2):e33–7.
15. Kalpidis CDR, Setayesh RM. Hemorrhaging associated with endosseous implant placement in the anterior mandible: A review of the literature. *J Periodontol.* 2004;75(5):631–45.
16. Givol N, Chaushu G, Halamish-Shani T, Taicher S. Emergency tracheostomy following life-threatening hemorrhage in the floor of the mouth during immediate implant placement in the mandibular canine region. *J Periodontol.* 2000;71(11):1893–5.
17. Babiuc I, Tarlungeanu I, Pauna M. Cone beam computed tomography observations of the lingual foramina and their bony canals in the median region of the mandible. *Rom J Morphol Embryol.* 2011;52(3 Suppl):827–9.
18. Tomljenovic B, Herrmann S, Filippi A, Kühl S. Life-threatening hemorrhage associated with dental implant surgery: A review of the literature. *Clin Oral Implants Res.* 2015;27(9):1079–84.
19. Schiegnitz E, Moergel M, Wagner W. Vital life-threatening hematoma after implant insertion in the anterior mandible: A case report and review of the literature. *Case Rep Dent.* 2015;2015(1):531865.
20. Peñarrocha-Diago M, Balaguer-Martí JC, Peñarrocha-Oltra D, Bagán J, Peñarrocha-Diago M, Flanagan D. Floor of the mouth hemorrhage subsequent to dental implant placement in the anterior mandible. *Clin Cosmet Investig Dent.* 2019;11(1):235–42.
21. Blanc O, Krasovsky A, Shilo D, Capucha T, Rachmiel A. A life-threatening floor of the mouth hematoma secondary to explantation attempt in the anterior mandible. *Quintessence Int.* 2021;52(1):66–71.
22. Charalampakis A, Kourkoumelis G, Psari C, Antoniou V, Piagkou M, Demesticha T, et al. The position of the mental foramen in dentate and edentulous mandibles: Clinical and surgical relevance. *Folia Morphol (Warsz).* 2017;76(4):709–14.
23. Lautner NV, Bernauer E, Krenkel C, Gaggl A. Altered position of the medial lingual nutritional foramina at different stages of alveolar ridge atrophy. *J Oral Implantol.* 2014;40(1):19–24.
24. Natsis K, Repousi E, Asouhidou I, Siskos C, Ioannidi A, Piagkou M. Foramina of the anterior mandible in dentate and edentulous mandibles. *Folia Morphol (Warsz).* 2016;75(2):204–10.
25. Lam M, Koong C, Kruger E, Tennant M. Prevalence of accessory mental foramina: A study of 4000 CBCT scans. *Clin Anat.* 2019;32(8):1048–52.
26. Papadopoulos V, Filippou D, Fiska A. Prevalence of rare anatomic variants—Publication bias due to selective reporting in meta-analyses studies. *Folia Med (Plovdiv).* 2024;66(5):795–817.
27. Sayahpour B, Nucci L, Eslami S, Talaeipour A, Ahmadi Ranani S, Mafi R, et al. Three-dimensional evaluation of mandibular lingula: Comparisons of skeletal angle classifications and growth patterns. *Orthod Craniofac Res.* 2024;27(4):494–503.