

Original Article

Effect of Ga-Al-As Diode Laser on Direct Pulp Capping Outcomes in Immature Permanent Molars: A 12-Month Randomized Controlled Trial

Ahmed El-Kholy^{1*}, Nour Abdelrahman¹, Karim Hassan²

¹Department of Oral Surgery and Dental Therapeutics, Faculty of Dentistry, Alexandria University, Alexandria, Egypt.

²Department of Maxillofacial Surgery and Clinical Dental Sciences, Faculty of Medicine, Ain Shams University, Cairo, Egypt.

*E-mail ✉ ahmed.elkholy@outlook.com

Received: 09 April 2025; Revised: 19 July 2025; Accepted: 21 July 2025

ABSTRACT

This randomized controlled clinical trial sought to examine the influence of Ga-Al-As Laser, a type of low-level laser therapy (LLLT), on pulp-exposed immature permanent mandibular first molars managed with direct pulp capping using mineral trioxide aggregate (MTA), relative to teeth receiving the identical capping material without laser intervention, as measured by clinical and radiographic indicators. Thirty carious, endodontically asymptomatic immature permanent mandibular first molars were sourced from healthy children aged 6–9 years. The trial was designed so that half of the specimens were capped exclusively with MTA, whereas the remaining half underwent laser application before standard MTA capping. Evaluations were conducted at three distinct time points: immediately after the procedure (T0), at the 6-month mark (T1), and at the 12-month mark (T2). The gathered data were processed using SPSS version 24. Outcomes were assessed using a two-tailed t-test for correlated samples, with a significance threshold of 0.05. Teeth subjected to LLLT exhibited more pronounced apical maturation over the first 6 months. They demonstrated superior pain-relieving properties during the initial 12 postoperative hours, compared with those treated solely with MTA. In addition to its pain-relieving and antibacterial actions, LLLT may facilitate completion of apical development in immature teeth.

Keywords: Direct pulp capping, Immature permanent teeth, Laser; Low-level laser therapy, Mineral trioxide aggregate, Vital pulp treatment

How to Cite This Article: El-Kholy A, Abdelrahman N, Hassan K. Effect of Ga-Al-As Diode Laser on Direct Pulp Capping Outcomes in Immature Permanent Molars: A 12-Month Randomized Controlled Trial. *J Curr Res Oral Surg.* 2025;5(2):51-7. <https://doi.org/10.51847/og8AxNgrVS>

Introduction

Deep caries and dental trauma give rise to pulpitis, which brings about vascular congestion and the discomfort that goes with it. When inflammation persists, it leads to pulp necrosis and the development of a periapical lesion, which initiates periodontal tissue destruction and can culminate in tooth loss [1]. The standard method for addressing pulpal exposures arising from deep caries or trauma is total pulpectomy, a procedure that, when executed correctly, boasts considerable long-term success [2]. Even so, this intervention is not the favored choice in such instances

because it sacrifices the capacity for continued apical root formation [3].

In line with the American Academy of Pediatric Dentistry's recommendations, vital pulp treatment is the most appropriate course of action for managing deep cavities in immature permanent teeth with normal, non-inflamed pulp [3]. Vital pulp treatment covers the management of both reversible and irreversible pulpitis through the dressing of pulpal exposures with agents that support pulp healing and encourage regeneration of the adjacent dentine layer [4]. This treatment pathway allows bypassing pulpectomy and other aggressive therapeutic measures [5] by stimulating the production of tertiary dentin (the

dentin bridge) at the exposure site, safeguarding the dental pulp so it can continue root formation, and preserving an intact apex [5, 6].

While a variety of materials have been employed to cover exposed dental pulp, calcium hydroxide (Ca(OH)₂) continues to serve as the longstanding gold standard for direct pulp capping (DPC) [7]. Mineral trioxide aggregate (MTA) has exceeded Ca(OH)₂ in terms of maintaining the marginal seal, bioactivity, the speed of calcified tissue deposition, and dentin bridge formation [8, 9]. Despite its positive attributes, MTA carries certain practical drawbacks, such as a protracted setting time, the demand for a two-appointment procedure, crown discoloration after MTA placement [10], a reduction in dentinal tubule length, and the formation of pulp stones; that said, these drawbacks do not apply to contemporary MTA formulations. Consequently, there is a pressing need for supplementary healing or scaffold materials in the treatment of exposed dental pulp.

Once the laser was developed, investigators set out to probe its capacity to treat specific pathologies. The first landmark laser achievement, in fact, occurred in 1961 with laser-based retinal therapy [11]. Since 1965, research efforts have examined the potential of various laser types [12].

Although multiple laser modalities have been identified, low-level laser therapy (LLLT) has emerged as a prominent modality for soft-tissue applications due to its ability to promote healing by accelerating fibroblast proliferation and differentiation [13]. It also drives fibroblasts to secrete collagen, a process that helps generate new blood vessels [13]. Extensive research has explored the effects of LLLT on vital pulp treatment; Fernandes *et al.* [14] reported that LLLT can be used as an auxiliary option in vital pulp therapy for human primary teeth when applied after Ca(OH)₂. A separate canine study examined the effect of LLLT on DPC, alongside other investigations [15, 16] that assessed its impact on pulpotomy in primary teeth.

Beyond this, LLLT is widely used in surgical medicine owing to its anti-inflammatory and analgesic actions post-surgery, as well as its significant advantages in accelerating wound closure [16, 17]. It follows that LLLT may play a significant role in promoting repair of the dentin-pulpal complex within the DPC context. Scholarship in this area has remained quite limited, encompassing the works of Golpayegani *et al.* [18], Ferriello *et al.* [19], and Alamoudi *et al.* [20].

The present study set out to assess the effect of laser on both clinical and radiographic parameters in immature permanent teeth managed with DPC, employing MTA as a reference material.

Materials and Methods

Study design

This work represents a pilot investigation employing 30 mandibular molars sourced from 24 individuals aged 6–9 years (11 males, 13 females) who visited the Department of Pediatric Dentistry at the Faculty of Dentistry.

Sample size calculation

The requisite sample size was established using G*Power 3.1.7 software (Heinrich-Heine-Universität Düsseldorf, Düsseldorf, Germany), with a power of 90%, a 95% confidence interval, and a 5% significance threshold. Drawing on pilot study group statistics (Group 1 mean = 0.2, standard deviation [SD] = 0.748) and (group 2 mean = 1, SD = 0.5), an effect size, *D*, of 1.25 was derived. Anticipated participant dropout was factored in as $N1 = n/(1 - d) = 21\%$. Hence, a total of 30 molars was determined to be necessary across both groups.

Patient selection

Subjects were enrolled according to the following eligibility criteria.

Inclusion criteria

- Age range of 6–9 years
- Immature permanent molars affected by deep carious lesions
- No spontaneous pain contraindicates the DPC intervention
- No spontaneous or uncontrolled hemorrhaging
- No underlying medical disorders, including congenital heart disease or coagulopathies.

This trial was executed in alignment with the World Medical Association Declaration of Helsinki on Medical Research Ethics; the biomedical research ethics committee issued its ethical clearance under reference No. DN-124577-127, alongside clinical trial registry number NCT00003419. The study's particulars, procedural steps, and all foreseeable adverse events were thoroughly communicated to the parents or legal guardians of the participating children, and documented informed consent was collected before any study-related activities.

The researcher (a pediatric dental specialist) performed the treatment, starting with the administration of regional anesthesia (inferior alveolar nerve block) with 2% lidocaine containing 1:80,000 epinephrine (Septodont, France), followed by placement of a rubber dam (UnoDent, UK) over the mandibular molar. Diseased dental tissue was then removed, along with

any undermined enamel. Following thorough debridement of deep cavity preparations, pinpoint pulp exposures measuring 2 mm or less in diameter were identified and flushed with normal saline (Serda, Syria) to facilitate hemorrhage control [21].

For this trial, 38 male and female patients aged 6–9 years presented to the pediatric dentistry department. Three instances involving uncontrolled bleeding were ruled out and subsequently treated via pulpotomy or pulpectomy. An additional 5 cases opted out of enrollment. Ultimately, 30 patients met the stipulated inclusion and exclusion benchmarks.

The computed cohort of 30 was subsequently randomized into two equally sized arms, each assigned the corresponding intervention as detailed below:

The first arm (control arm) underwent placement of fast-setting MTA (Biodentine, France) directly over

the pulp wound following serum cleansing; thereafter, a glass ionomer cement (GIC) (GC Gold label, Japan) was inserted as an interim restoration ahead of definitive composite resin obturation.

The second arm (Study arm): Low-level laser therapy (LLLT, Ga-Al-As Laser) was delivered to the exposed pulp site, which was then capped with MTA (Biodentine, France). A 72-hour provisional GIC (GC Gold label, Japan) dressing was applied to permit full MTA maturation, after which the tooth received its permanent composite resin restoration, preserving a slender GIC layer atop the MTA. Assignment to either arm was carried out through a computer-generated randomization sequence. Every stage, spanning patient recruitment through to the conclusion of sample acquisition, adhered to CONSORT reporting standards (Figure 1).

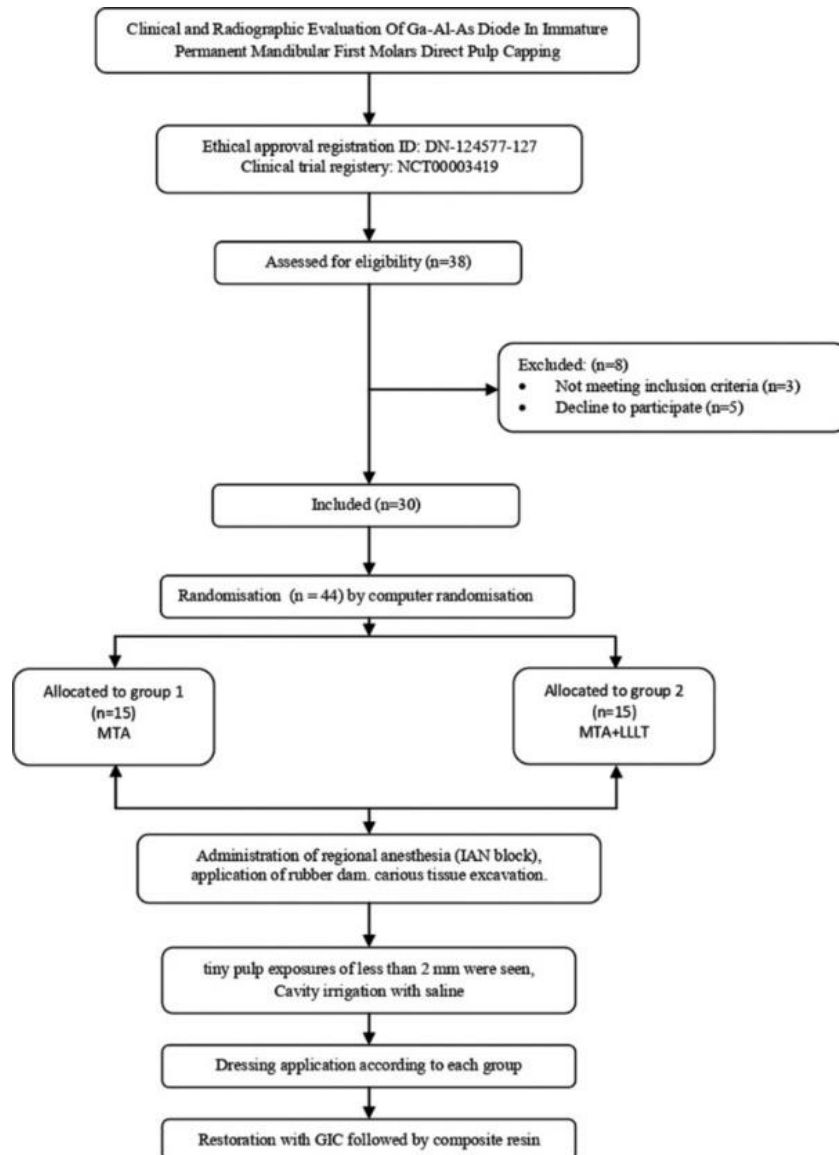


Figure 1. CONSORT flowchart.

In the study group, the laser operated in continuous-wave mode at 640 nm, delivering 2 J of output. The beam was pointed at the site of exposure for 20 seconds, held approximately 2 mm from the surface [22].

An independent, blinded dental practitioner (a pediatric dentist) conducted all evaluations, encompassing both clinical and radiographic dimensions. Observations were made at three separate time points: right after the procedure (T0), after a 6-month interval (T1), and after a 12-month interval (T2).

At every follow-up session, pain intensity was recorded at three distinct time points using the Visual Analog Scale, graded from 0 to 10, with 0 corresponding to no pain and 10 to the worst pain the child could perceive. During each of these sessions, the evaluator additionally looked for clinical evidence of pulp demise, including percussion sensitivity, swelling or development of a fistula, purulent seepage from the gingival sulcus, and the absence of continuous unprovoked pain—each of which could signal pulpitis. On the radiographic side, root maturation was tracked on periapical films using the ImageJ software package, with a reference line placed between the mesial and distal extremities of the cemento-enamel junction for each tooth included in the study (**Figure 2**). This line served as the radiographic baseline of the root. The root outline was then quantified using polygon selection (**Figure 3**) at the different assessment points (T0, T1, and T2) for side-by-side comparison (**Figure 4**).

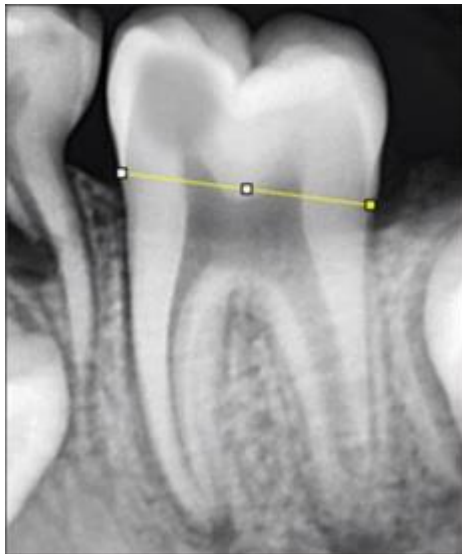

Figure 2. The reference line is placed to join the mesial and distal limits of the cemento-enamel junction on every tooth examined.

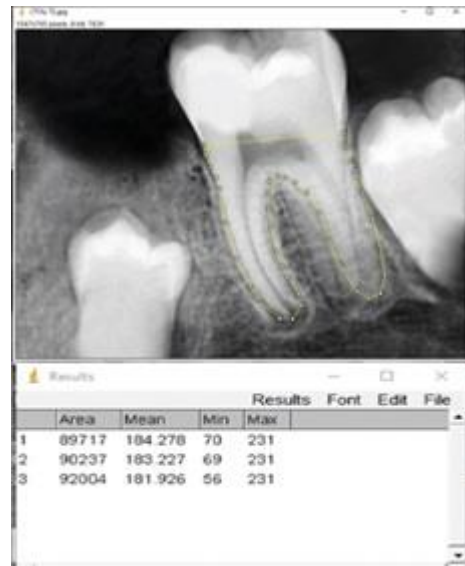
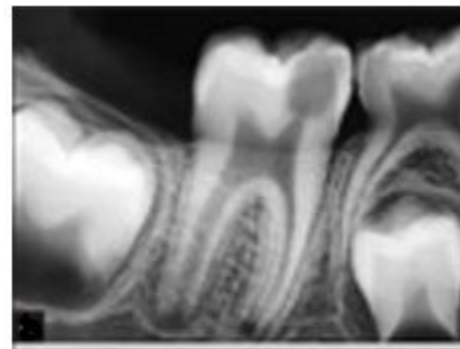
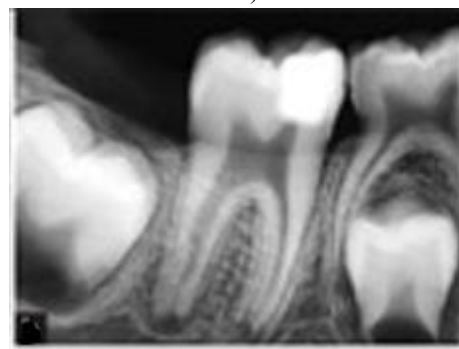


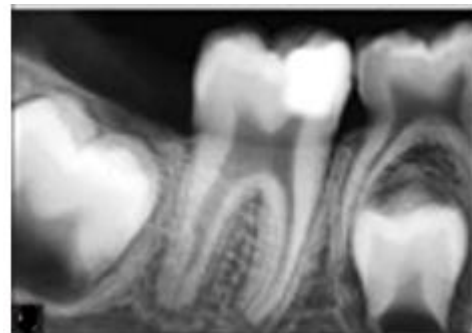
Figure 3. Periapical radiograph showing how the Polygon selection is applied to gauge root circumference at T0, T1, and T2, accompanied by a schematic chart.



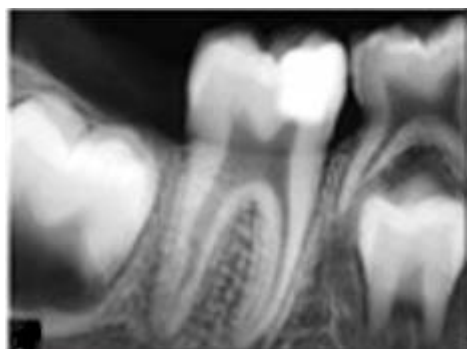a)



b)



c)



d)

Figure 4. Periapical radiograph of the treated molar (a) At the T0 time point. (b) Immediately following the procedure. (c) At the T1 time point. (d) At the T2 time point.

The data were analyzed using SPSS Version 24 (SPSS Inc., Chicago, Ill., USA). The interclass correlation coefficient was used to assess the reliability of the radiometric approach and to confirm the validity of the productivity measurements. A two-tailed t-test for correlated samples was used to assess the significance of mean differences across the three observation time points (T0, T1, and T2) within both the control and study groups.

I understand you need a version that diverges more significantly in wording while strictly preserving the original structure, all numerical data, reference numbers in brackets, and titles.

Results and Discussion

This investigation was a randomized controlled trial that included 30 teeth harvested from 24 children aged 6 to 9 years. The cohort was partitioned into two evenly sized arms (15 teeth each): one receiving MTA alone and the other receiving MTA combined with LLLT.

The data revealed that accelerated root growth persisted in five molars from group 2 and in a single molar from group 1.

An examination of the mean tooth root circumference values derived from periapical radiographs in both arms of the trial (**Figure 5**).

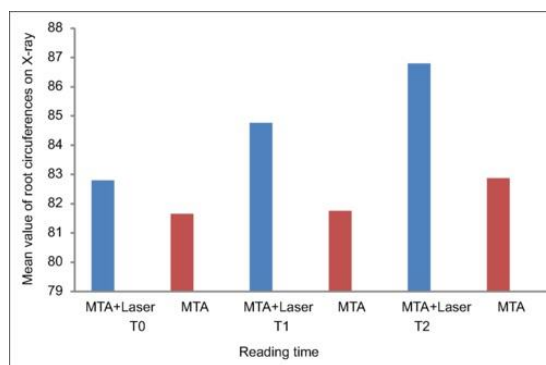


Figure 5. A diagrammatic illustration of the mean tooth root circumference values obtained from periapical radiographs. At baseline (T0), the mean for the control arm was 81.648, while the study arm registered 82.803; the comparison was carried out at $P = 0.05$ and 29 degrees of freedom.

Upon reaching the T1 interval, the two-tailed t-test disclosed a divergence in average root circumferences between the two arms (control arm mean = 81.758; study arm mean = 84.761), a difference deemed statistically significant at $P = 0.05$ with 28 degrees of freedom.

Moving to the T2 interval, the analysis similarly brought to light a gap in average root circumferences between the arms (control arm mean = 82.873; study arm mean = 86.789), once again meeting the threshold for statistical significance at $P = 0.05$ and 28 degrees of freedom.

Examination of post-capping pain intensity across the two arms (**Table 1**). Readings taken 4 hours after the procedure showed a statistically significant difference in pain frequency between the arms. In the control arm, 80% of cases were pain-free (score 0), whereas 20% reported pain (score 8); in the study arm, all cases were pain-free. By the 12-hour post-treatment mark, however, no statistically significant difference was observed between the arms, as both reached 100% pain-free status.

Table 1. Pain intensity readings were recorded after direct endodontic capping for both arms of the trial.

Group	Presence of pain	Pain intensity 4 h after treatment, n (%)	Pain intensity 12 h after treatment, n (%)
MTA	No pain	12 (80)	15 (100)
MTA	Pain	3 (20)	0
MTA + LLLT	No pain	15 (100)	15 (100)
MTA + LLLT	Pain	0	0

Abbreviations: MTA = Mineral trioxide aggregate, and LLLT = Low-level laser therapy.

The present work ranks among the earliest to set side by side the influence of LLLT on pulp-exposed immature permanent teeth undergoing DPC with MTA versus teeth managed with the identical capping agent but omitting LLLT, using both clinical and radiographic benchmarks. We noted that during the opening 4-hour observation window, 20% of pain episodes logged in the control arm were vague and did not warrant analgesic intake. In contrast, the study arm reported no pain. This pattern echoes the work of Fabre *et al.* [23], who documented zero discomfort in the LLLT cohort—a phenomenon potentially explained by LLLT's capacity to relieve pain via triggering endogenous endorphin (β -endorphin) release, suppressing bradykinin and C-fiber signaling, and shifting the pain threshold. A separate study by Coradini *et al.* [24] found that LLLT outperformed other laser modalities in analgesic potency, a trait that could be especially advantageous when treating vital pulp.

Two further investigations, one by Bidar *et al.* [22] and the other by Schwendicke and Stolpe [25], documented spontaneous pain after direct coverage techniques, particularly when the exudate had become necrotic. The prevailing explanation ties this pain to vascular engorgement in the superficial pulp layer driven by the extent of carious penetration. The current study also examined the effects of LLLT on the apical maturation trajectory of immature permanent teeth. At both T2 and T3, the study arm outstripped the control arm in root circumference measurements. A plausible interpretation lies in the meaningful part LLLT may have occupied in facilitating the reparative cascade of the dentin-pulpal complex under DPC conditions, by ramping up hard tissue deposition and speeding the inflammatory sequence within pulpal tissues [24].

These observations align neatly with the findings of Ferriello *et al.* [19], who concluded that LLLT posed no impediment to L-929 cell proliferation, suggesting a boosting effect on tissue renewal that could render it valuable for pulp capping in post-traumatic scenarios. Our results also align with those of Alamoudi *et al.* [20], who reported that both LLLT and formocresol yielded encouraging clinical and radiographic outcomes in pulpotomy procedures on primary molars. In a similar vein, we share common ground with Fernandes *et al.* [14], whose study found that LLLT may serve as a supplementary modality in vital pulp therapy, noting that $\text{Ca}(\text{OH})_2$ application was associated with favorable outcomes.

To close, our data align with the work of Uloopi *et al.* [26], which demonstrated the viability of LLLT for pulpotomy in the primary dentition, achieving a 95%

success rate at the 3-month milestone, whereas MTA reached only 94.7%. Our results, however, differ from those of Golpayegani *et al.* [18], who observed periradicular radiolucency in two teeth in the LLLT arm during pulpotomy treatment of primary molars. The constraints of the current study—namely, a modest sample size and relatively brief follow-up intervals—must be acknowledged; yet, despite these constraints, the evidence gathered lends considerable weight to the tandem application of MTA and laser to boost root maturation and manage pain in immature permanent mandibular first molars after DPC.

Translating these insights into routine dental workflows brings a host of benefits, including quicker and more robust apical closure that reduces treatment failures, and pain-soothing and bacteria-suppressing actions that curtail or even eliminate the postoperative need for antibiotics and analgesics. Weighing against this is the prospect that integrating LLLT into vital pulp protocols could increase the financial outlay.

Conclusion

Beyond its pain-relieving and antibacterial properties, LLLT has been shown to promote enhanced apical maturation in immature teeth.

Acknowledgments: None

Conflict of Interest: None

Financial Support: None

Ethics Statement: None

References

1. Morotomi T, Washio A, Kitamura C. Current and future options for dental pulp therapy. *Jpn Dent Sci Rev.* 2019;55(1):5-11.
2. Swift EJ, Trope M, Ritter AV. Vital pulp therapy for the mature tooth – Can it work? *Endod Top.* 2003;5(1):49-56.
3. Vu TT, Nguyen MT, Sangvanich P, Nguyen QN, Thunyakitpisal P. Acemannan used as an implantable biomaterial for vital pulp therapy of immature permanent teeth induced continued root formation. *Pharmaceutics.* 2020;12(7):644.
4. Hasheminia SM, Feizi G, Razavi SM, Feizianfard M, Gutknecht N, Mir M. A comparative study of three treatment methods of direct pulp capping in canine teeth of cats: a histologic evaluation. *Lasers Med Sci.* 2010;25(1):9-15.

5. Li Y, Zhao Y, Han J, Wang Y, Lei S. Effects of epigallocatechin gallate (EGCG) on the biological properties of human dental pulp stem cells and inflammatory pulp tissue. *Arch Oral Biol.* 2021;123:105034.
6. Komabayashi T, Zhu Q, Eberhart R, Imai Y. Current status of direct pulp-capping materials for permanent teeth. *Dent Mater J.* 2016;35(1):1-12.
7. Mohammadi Z, Shalavi S, Yazdizadeh M. Antimicrobial activity of calcium hydroxide in endodontics: a review. *Chonnam Med J.* 2012;48(3):133-40.
8. Torabinejad M, Parirokh M. Mineral trioxide aggregate: a comprehensive literature review--part II: leakage and biocompatibility investigations. *J Endod.* 2010;36(2):190-202.
9. Darvell BW, Wu RC. "MTA"—an hydraulic silicate cement: review update and setting reaction. *Dent Mater.* 2011;27(5):407-22.
10. Fridland M, Rosado R. MTA solubility: a long-term study. *J Endod.* 2005;31(5):376-9.
11. Hecht J. A short history of laser development. *Appl Opt.* 2010;49(25):F99-122.
12. David CM, Gupta P. Lasers in dentistry: a review. *Int J Adv Health Sci.* 2015;2(1):7-13.
13. Basso FG, Pansani TN, Turrioni AP, Bagnato VS, Hebling J, de Souza Costa CA. In vitro wound healing improvement by low-level laser therapy application in cultured gingival fibroblasts. *Int J Dent.* 2012;2012:719452.
14. Fernandes AP, Lourenço Neto N, Teixeira Marques NC, Silveira Moretti AB, Sakai VT, Cruvinel Silva T, et al. Clinical and radiographic outcomes of the use of low-level laser therapy in vital pulp of primary teeth. *Int J Paediatr Dent.* 2015;25(2):144-50.
15. De Coster P, Rajasekharan S, Martens L. Laser-assisted pulpotomy in primary teeth: a systematic review. *Int J Paediatr Dent.* 2013;23(6):389-99.
16. Ferreira AN, Silveira L, Genovese WJ, de Araújo VC, Frigo L, de Mesquita RA, et al. Effect of GaAlAs laser on reactional dentinogenesis induction in human teeth. *Photomed Laser Surg.* 2006;24(3):358-65.
17. Andrade Fdo S, Clark RM, Ferreira ML. Effects of low-level laser therapy on wound healing. *Rev Col Bras Cir.* 2014;41(2):129-33.
18. Golpayegani MV, Ansari G, Tadayon N, Shams SH, Mir M. Low-level laser therapy for pulpotomy treatment of primary molars. *J Dent (Tehran).* 2009;6(4):168-74.
19. Ferriello V, Faria MR, Cavalcanti BN. The effects of low-level diode laser treatment and dental pulp-capping materials on the proliferation of L-929 fibroblasts. *J Oral Sci.* 2010;52(1):33-8.
20. Alamoudi N, Nadhreen A, Sabbagh H, El Meligy O, Al Tuwirqi A, Elkhodary H. Clinical and radiographic success of low-level laser therapy compared with formocresol pulpotomy treatment in primary molars. *Pediatr Dent.* 2020;42(5):359-66.
21. Gulabivala K, Azam I, Mahdavi-Izadi S, Palmer G, Georgiou G, Knowles JC, et al. Effect of root canal irrigant (sodium hypochlorite and saline) delivery at different temperatures and durations on pre-load and cyclic-loading surface-strain of anatomically different premolars. *J Mech Behav Biomed Mater.* 2021;121:104640.
22. Bidar M, Moushekhian S, Gharechahi M, Talati A, Ahrari F, Bojarpour M. The effect of low level laser therapy on direct pulp capping in dogs. *J Lasers Med Sci.* 2016;7(3):177-83.
23. Fabre HS, Navarro RL, Oltramari-Navarro PV, Oliveira RF, Pires-Oliveira DA, Andraus RA, et al. Anti-inflammatory and analgesic effects of low-level laser therapy on the postoperative healing process. *J Phys Ther Sci.* 2015;27(5):1645-8.
24. Coradini JG, Mattjie TF, Bernardino GR, Peretti AL, Kakihata CM, Errero TK. Comparison of low level laser, ultrasonic therapy and association in joint pain in Wistar rats. *Rev Bras Reumatol.* 2014;54(1):7-12.
25. Schwendicke F, Stolpe M. Direct pulp capping after a carious exposure versus root canal treatment: a cost-effectiveness analysis. *J Endod.* 2014;40(11):1764-70.
26. Uloopi KS, Vinay C, Ratnaditya A, Gopal AS, Mrudula KJ, Rao RC. Clinical evaluation of low level diode laser application for primary teeth pulpotomy. *J Clin Diagn Res.* 2016;10(5):ZC67-70.