

Original Article

## Morphological Variations of the Mandibular Lingula: Impact on Its Position in the Ramus for Sagittal Split and Vertical Ramus Osteotomies

András T. Kovács<sup>1\*</sup>, Zoltán Varga<sup>1</sup>, Márta Szabó<sup>1</sup>

<sup>1</sup>Department of Oral and Maxillofacial Surgery, Faculty of Dentistry, Semmelweis University, Budapest, Hungary.

\*E-mail ✉ [andras.kovacs@outlook.com](mailto:andras.kovacs@outlook.com)

Received: 23 January 2022; Revised: 17 April 2022; Accepted: 18 April 2022

### ABSTRACT

The lingula serves as a key skeletal reference during mandibular operations such as sagittal split ramus osteotomy (SSRO) and intraoral vertical ramus osteotomy (IVRO). This research aimed to map the lingula's position in both horizontal and vertical orientations across four distinct ramus-shape categories. Cone beam computed tomography was performed on 90 individuals (60 women and 30 men) to determine how far the lingula tip (Li) lies from the anterior border (AB), posterior border (PB), sigmoid notch (SN), and inferior border (IB) of the ramus. Its proportional placement was expressed by the Li-AB/AB-PB and Li-SN/SN-IB ratios. Lingula configurations were sorted into triangular, truncated, nodular, and assimilated types. Statistical testing was used to assess shape-related and sex-related variations. The average Li-AB measurement was 18.88 mm, and this value was significantly larger in the truncated form than in the remaining three shapes. The Li-PB distance averaged 15.23 mm, showing no shape-based differences. The mean Li-AB/AB-PB proportion was 55.3%, with the truncated type reaching 57.2%, exceeding both the nodular (54%) and assimilated (50.4%) patterns. The Li-SN and Li-IB values were 19.95 mm and 31.34 mm, respectively, without meaningful variation among the 4 lingula types. The Li-SN/SN-IB proportion averaged 38.5%. No measurements differed between male and female participants. The four lingula forms showed significant variation in the location of the Li, which tended to lie superior and posterior to the ramus midpoint. Awareness of these shape-dependent differences is essential when performing SSRO or IVRO.

**Keywords:** Morphological variations, Mandibular, Lingula, Ramus, Sagittal split

**How to Cite This Article:** Kovács AT, Varga Z, Szabó M. Morphological Variations of the Mandibular Lingula: Impact on Its Position in the Ramus for Sagittal Split and Vertical Ramus Osteotomies. *J Curr Res Oral Surg.* 2022;2:85-92. <https://doi.org/10.51847/eAmneFuAMK>

### Introduction

Located on the medial aspect of the mandibular ramus, the lingula is a small bony projection positioned above the mandibular foramen. Tuli *et al.* [1] described four identifiable shapes: triangular, truncated, nodular, and assimilated. The sphenomandibular ligament (SML), a thin fibrous structure derived from Meckel's cartilage [2], attaches superiorly to the sphenoid spine and inferiorly to the lingula and the lower portion of the mandibular foramen (MF). Through the MF, the inferior alveolar nerve (IAN) and its vessels enter the mandibular canal. Precise awareness of the lingula relative to the MF and IAN is important because it influences the reliability of IAN anesthesia and many dental or surgical procedures.

A review by Hsu *et al.* [3] summarized lingula traits in different populations. In Indian groups, the triangular version was most frequent in both sexes, whereas in Thai and Brazilian groups, the truncated type appeared more often. For dry mandibles, the triangular shape dominated, followed by truncated, nodular, and assimilated forms. In contrast, CBCT studies most commonly identified the nodular type, then truncated, triangular, and assimilated shapes. Variability in dry mandible findings may relate to differences in sample ethnicity, dental condition, skeletal attributes, age distribution, or specimen handling, while CBCT analyses may be affected by image quality and the way software renders morphological features.

For treating mandibular prognathism, surgeons typically choose between SSRO and IVRO. These methods differ in technique:

(1) SSRO requires careful soft-tissue elevation above the MF to avoid damaging the inferior neurovascular components before dividing the ramus into medial and lateral parts.

(2) IVRO involves making a vertical cut behind the lingula and MF from the outer surface of the ramus, producing proximal and distal segments.

Both procedures depend on accurately locating the lingula and MF to prevent harm to the IAN or associated vessels, as such injury may lead to postoperative lower-lip sensory loss [4]. Consequently, evaluating lingula shape and related distances is essential. This study aimed to document the horizontal and vertical dimensions associated with the four lingula types and to determine whether statistically significant differences exist among them.

## Materials and Methods

CBCT scans were obtained at the Density Department of Kaohsiung Medical University Chung-Ho Memorial Hospital. Imaging was carried out with the patient maintaining a natural head posture and in maximum intercuspation. Individuals were excluded if they presented with: (1) craniofacial neoplasms or other pathologic conditions, (2) congenital anomalies affecting craniofacial structures, or (3) previous injuries or surgical interventions involving the craniofacial region. The CBCT DICOM datasets were then transferred into RadiAnt DICOM Viewer version 4.6.9 (Medixant, Poznan, Poland) to reconstruct three-dimensional models. All linear measurements were taken using the program's integrated ruler tool.

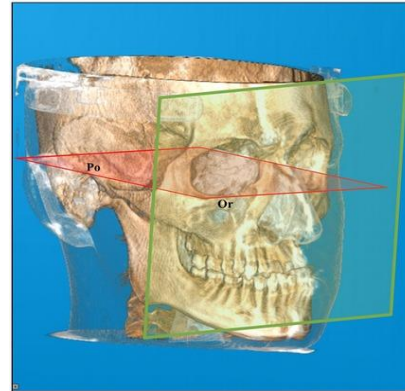
The Frankfort horizontal plane (**Figure 1**), defined by the line passing through the inferior orbital rim (Or: orbitale) and the upper margin of the external auditory meatus (Po: porion), served as the horizontal reference. Lingula morphology was categorized into four patterns—triangular, truncated, nodular, and assimilated—following Tuli *et al.* (**Figure 2**). In **Figure 3**, vertical and horizontal axes intersecting at the lingula tip (Li) were used for all measurements.

Horizontal parameters included:

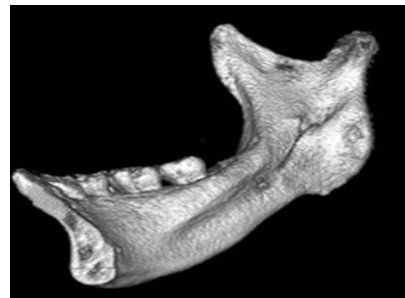- (1) Li–AB, the distance from Li to the ramus' anterior border;
- (2) Li–PB, the distance between Li and the posterior border;
- (3) AB–PB, the anteroposterior width of the ramus;
- (4) Li–AB/AB–PB, representing the proportional anterior–posterior placement of Li.

Vertical parameters consisted of:

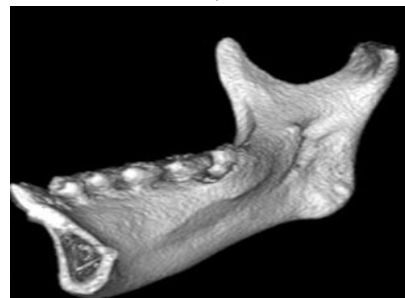
- (1) Li–SN, the distance from Li to the sigmoid notch (SN);
- (2) Li–IB, the distance from Li to the inferior border (IB);
- (3) SN–IB, the vertical height of the ramus;
- (4) Li–SN/SN–IB, indicating the relative vertical position of Li between SN and IB.



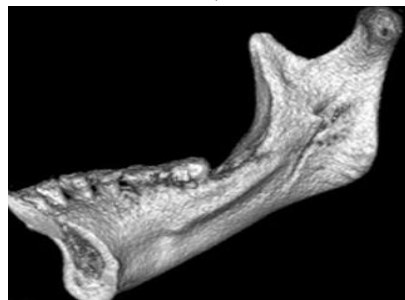
**Figure 1.** Frankfort horizontal plane (red): reference line through Or and Po. Vertical reference plane (green): perpendicular to the Frankfort plane.



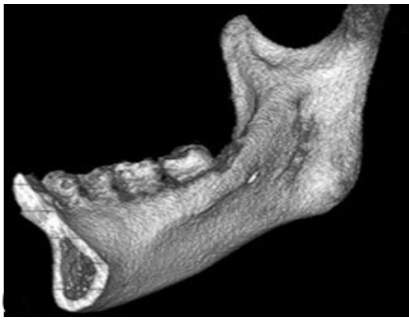
a)



b)

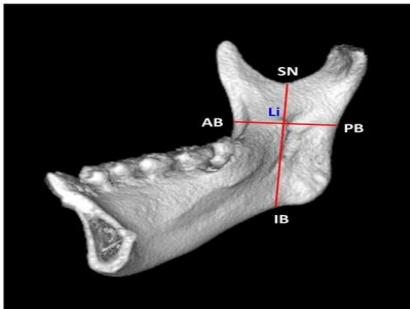


c)



d)

**Figure 2.** Lingula shape categories: (a) triangular, (b) truncated, (c) nodular, (d) assimilated.



**Figure 3.** Measurement landmarks in the horizontal and vertical reference planes: Li, AB, PB, SN, IB.

Statistical assessments were performed using IBM SPSS 20 (SPSS, Chicago, IL, USA) to compare

measurements across the four lingula types. Differences among the four groups were evaluated with ANOVA, and the Scheffe post hoc test was applied when the ANOVA showed significance. A p-value <0.05 indicated statistical significance. Comparisons between male and female participants were also conducted. Institutional review board approval was granted by Kaohsiung Medical University (IRB No. KMH-IRB-20160066).

## Results and Discussion

CBCT data from 90 patients (a total of 180 sides) were analyzed (**Table 1**). Among all sides, the triangular type appeared 44 times, the truncated 59 times, the nodular 68 times, and the assimilated 9 times [5]. Of the patient group, 60 females contributed 120 sides, whereas 30 males contributed 60 sides.

In females, the lingula shapes were distributed as follows: triangular (31 sides), truncated (37 sides), nodular (48 sides), and assimilated (4 sides).

In males, the frequencies were triangular (13 sides), truncated (22 sides), nodular (20 sides), and assimilated (5 sides).

**Table 1.** Horizontal distances (mm) and ratios for each lingula shape.

Lingula Shape	n	Li–PB (mm)	Li–AB (mm)	Li–AB/AB–PB Ratio	AB–PB (mm)
		Mean ± SD	Mean ± SD	Mean	Mean ± SD
Triangular	44	14.73 ± 1.92	18.64 ± 2.47	0.558	33.37 ± 2.67
Truncated	59	15.23 ± 2.26	20.30 ± 2.59	0.572	35.53 ± 3.55
Nodular	68	15.39 ± 1.81	18.08 ± 2.40	0.540	33.47 ± 3.09
Assimilated	9	16.57 ± 1.95	16.83 ± 1.72	0.504	33.40 ± 3.27
<b>Total</b>	<b>180</b>	<b>15.23 ± 2.02</b>	<b>18.88 ± 2.66</b>	<b>0.553</b>	<b>34.12 ± 3.29</b>
Inter-shape comparison (ANOVA + post-hoc)					
Parameter	p-value	Significant pairwise differences			
Li–AB	<0.001*	Truncated > Triangular, Nodular, Assimilated			
Li–PB	0.071 (NS)	No significant differences			
AB–PB	0.001*	Truncated > Triangular, Nodular			
Li–AB/AB–PB ratio	<0.001*	Truncated > Nodular, Assimilated; Triangular > Assimilated			

n, number of sides; Li, lingula; AB, anterior border; PB, posterior border.

Lingula types: (1) Triangular; (2) Truncated; (3) Nodular; (4) Assimilated.

\*Significant at p < 0.05; NS: Not significant.

Across all subjects (**Table 1**), the overall mean separation between Li and AB measured 18.88 mm. When analyzed by morphology, the triangular, truncated, nodular, and assimilated forms measured 18.64, 20.30, 18.08, and 16.83 mm, respectively. The truncated variant demonstrated a significantly larger Li–AB value than the other three configurations. The group mean for the Li–PB interval was 15.23 mm, with no meaningful variation between the four patterns. The

ramus width (AB–PB) averaged 34.12 mm among all participants, and the truncated type showed significantly greater values compared with both the triangular and nodular shapes.

The mean Li–AB/AB–PB proportion was 55.3% overall. The truncated form presented a significantly elevated value of 57.2%, exceeding the nodular (54%) and assimilated (50.4%) patterns.

For vertical parameters (**Table 2**), the group mean for Li–SN was 19.59 mm, with subtype averages of 19.03, 19.97, 19.76, and 18.61 mm for the triangular, truncated, nodular, and assimilated shapes. No statistically meaningful differences were found among these categories. The mean Li–IB and SN–IB values

were 31.34 mm and 50.94 mm, respectively, again without significant differences among the four forms. The average Li–SN/SN–IB ratio across all sides was 38.5%. The truncated configuration reached 39.4%, significantly exceeding the triangular (37.3%) and assimilated (35.1%) shapes. The nodular type (38.8%) was also significantly greater than the assimilated one.

**Table 2.** Vertical distances (mm) and ratios

Shape Category	Li–SNMean	Li–SNSD	Li–IBSD	Li–IBMean	SN–IBMean	Li–SN / SN–IBRatio	SN–IBSD
Triangular (n = 44)	19.03	3.54	3.51	31.80	50.83	0.373	4.67
Truncated (n = 59)	19.97	2.90	4.07	30.76	50.73	0.394	4.88
Nodular (n = 68)	19.76	3.17	3.88	31.15	50.92	0.388	5.05
Assimilated (n = 9)	18.61	3.23	4.25	34.39	53.00	0.351	6.04
<b>Overall (n = 180)</b>	<b>19.59</b>	<b>3.19</b>	<b>3.92</b>	<b>31.34</b>		<b>50.94</b>	<b>0.385</b>
<b>Parameter</b>	<b>p-value</b>		<b>Significance</b>		<b>Notes</b>		
Li–SN	0.357		NS		—		
Li–IB	0.058		NS		—		
SN–IB	0.641		NS		—		
Ratio (Li–SN/SN–IB)	0.026*		Significant		Group 2 > Groups 1 & 4; Group 3 > Group 4		

n = number of sides; Li = lingula; SN = sigmoid notch; IB = inferior border; shapes: 1 = triangular, 2 = truncated, 3 = nodular, 4 = assimilated.

\*Significant at p < 0.05; NS = not significant.

Among females (**Tables 3 and 4**), the truncated morphology showed a significantly larger Li–AB distance (19.52 mm) compared with the nodular (18.12 mm) and assimilated (16.15 mm) types. For the Li–AB/AB–PB ratio, the truncated form reached 56.9%, exceeding the nodular (54.7%) and assimilated (50.1%) patterns. The triangular type (56.1%) was also significantly greater than the assimilated type.

Vertical measures—Li–SN, Li–IB, and SN–IB—revealed no significant differences across the four shapes. However, the Li–SN/SN–IB ratios were significantly higher in the nodular (39.9%) and truncated (39.6%) forms compared with the assimilated (34.5%) subtype.

**Table 3.** Horizontal distances (mm) and ratios in females

Shape Type	Li–ABMean	Li–ABSD	Li–PBMean	Li–PBSD	AB–PBMean	AB–PBSD	Li–AB / AB–PBRatio
Triangular (n = 31)	18.48	2.22	14.45	1.95	32.94	2.54	0.561
Truncated (n = 37)	19.52	2.35	14.84	2.26	34.36	3.06	0.569
Nodular (n = 48)	18.12	2.40	14.98	1.85	33.10	3.21	0.547
Assimilated (n = 4)	16.15	2.34	16.05	2.29	32.20	4.22	0.501
<b>Overall (n = 120)</b>	<b>18.58</b>	<b>2.43</b>	<b>14.84</b>	<b>2.02</b>	<b>33.42</b>	<b>3.06</b>	<b>0.556</b>
<b>Variable</b>	<b>p-value</b>		<b>Interpretation</b>				
Li–AB	0.009*		2 > 3,4				
Li–PB	0.424		NS				
AB–PB	0.143		NS				
Ratio	0.019*		2 > 3,4; 1 > 4				

n = number of sides; Li = lingula; AB = anterior border; PB = posterior border.

\*Significant at p < 0.05; NS = not significant.

**Table 4.** Vertical distances (mm) and ratios in females

Shape Category	Li–SNMean	Li–SNSD	Li–IBMean	Li–IBSD	SN–IBMean	SN–IBSD	Li–SN / SN–IBRatio
Triangular (n = 31)	19.14	3.30	31.20	3.44	50.34	4.75	0.379
Truncated (n = 37)	19.44	2.73	29.74	3.50	49.19	4.50	0.396
Nodular (n = 48)	19.96	3.30	29.96	3.54	49.92	5.26	0.399
Assimilated (n = 4)	16.73	1.51	31.68	0.82	48.40	1.53	0.345

Overall (n = 120)	19.48	3.12	30.27	3.47	49.75	4.80	0.391
Measurement	p-value	Significance	Notes				
Li–SN	0.200	NS	—				
Li–IB	0.253	NS	—				
SN–IB	0.722	NS	—				
Ratio (Li–SN/SN–IB)	0.043*	Significant	Group 2 > Group 4; Group 3 > Group 4				

n = number of sides; Li = lingula; SN = sigmoid notch; IB = inferior border.

\*Significant at p < 0.05; NS = not significant.

For males (Tables 5 and 6), the truncated form showed a significantly larger Li–AB interval (21.62 mm) than the triangular (19.02 mm), nodular (17.99 mm), and assimilated (17.38 mm) types. The AB–PB value for the truncated group (37.50 mm) also surpassed the triangular (34.42 mm) and nodular (34.35 mm) shapes. The truncated type exhibited the highest Li–AB/AB–

PB ratio (57.7%), significantly above the triangular (55%) and nodular (52.2%) types.

Vertical metrics—Li–SN, Li–IB, SN–IB, and the Li–SN/SN–IB ratio—did not show any significant differences among the four shapes in males. Furthermore, comparisons between men and women revealed no significant differences in horizontal measurements, vertical distances, or either ratio.

**Table 5.** Horizontal distances (mm) and ratios in males

Shape Type	Li–ABMean	Li–ABSD	Li–PBMean	Li–PBSD	AB–PBMean	AB–PBSD	Li–AB / AB–PBRatio
Triangular (n = 13)	19.02	3.04	15.40	1.74	34.42	2.79	0.550
Truncated (n = 22)	21.62	2.49	15.88	2.16	37.50	3.50	0.577
Nodular (n = 20)	17.99	2.45	16.37	1.32	34.35	2.65	0.522
Assimilated (n = 5)	17.38	0.99	16.98	1.79	34.36	2.34	0.507
<b>Overall (n = 60)</b>	<b>19.49</b>	<b>3.00</b>	<b>16.03</b>	<b>1.80</b>	<b>35.52</b>	<b>3.30</b>	<b>0.547</b>
Variable	p-value		Significance		Interpretation		
Li–AB	<0.001*		Significant		Group 2 > Groups 1, 3, and 4		
Li–PB	0.287		NS		—		
AB–PB	0.004*		Significant		Group 2 > Groups 1 and 3		
Li–AB/AB–PB ratio	0.001*		Significant		Group 2 > Groups 3 and 4		

n = number of sides; Li = lingula; AB = anterior border; PB = posterior border.

\*Significant at p < 0.05; NS = not significant.

**Table 6.** Vertical distances (mm) and ratios in males

Shape Type	Li–SNMean	Li–SNSD	Li–IBMean	Li–IBSD	SN–IBMean	SN–IBSD	Li–SN / SN–IBRatio
Triangular (n = 13)	18.77	4.19	33.22	3.37	51.99	4.43	0.359
Truncated (n = 22)	20.85	3.02	32.48	4.45	53.33	4.45	0.392
Nodular (n = 20)	19.29	2.87	34.02	3.14	53.31	3.59	0.361
Assimilated (n = 5)	20.12	3.57	36.56	4.73	56.68	5.76	0.355
<b>Overall (n = 60)</b>	<b>19.82</b>	<b>3.33</b>	<b>33.49</b>	<b>3.92</b>	<b>53.31</b>	<b>4.34</b>	<b>0.372</b>
Measurement	p-value		Significance				
Li–SN	0.271		NS				
Li–IB	0.175		NS				
SN–IB	0.241		NS				
Ratio	0.174		NS				

n = number of sides; Li = lingula; SN = sigmoid notch; IB = inferior border.

NS = not significant.

Operations performed in proximity to the lingula, MF, or the mandibular canal within the ramus may endanger the inferior alveolar neurovascular bundle. Such complications can cause notable intraoperative hemorrhage and postoperative sensory loss in the lower lip. Therefore, precise localization of the lingula, MF, the occlusal plane (OP), and the distances connecting

these structures remains essential during ramus-related procedures.

*Distances from anterior and posterior borders of the ramus to the lingula tip (Li–AB and Li–PB)*

Multiple investigations [6–8] using dry mandibles have been documented. Jansisyanont *et al.* [6] identified an average Li–AB measurement of 20.6 mm in Thai

samples; Park *et al.* [7] reported 18.89 mm in South Koreans; and Monnazzi *et al.* [8] observed 16.50 mm in Brazilian mandibles. Additional analyses [9–11] relying on CBCT scans show comparable variability: in Turkey, Sekerci and Sisman [9] measured a mean of 16.77 mm, whereas Senel *et al.* [10] found 18.5 mm. Lupi *et al.* [11] documented 16.96 mm among Italian participants. In the current research, the Li–AB average was 18.88 mm. Differences across populations and methodologies highlight the influence of ethnic background, the choice of planes, and the adopted craniofacial reference points on the measured outcomes.

Across all subjects, the assimilated type demonstrated the smallest mean Li–AB distance (16.83 mm), while the truncated type showed the largest (20.30 mm). The Li–AB value for the truncated category was significantly greater than for the remaining three groups. Consequently, clinicians should take extra care when carrying out a medial horizontal osteotomy during SSRO in patients exhibiting a truncated lingula. To reliably reach the Li, the osteotomy may need to be extended by 3–4 mm beyond what would typically be sufficient for the assimilated type. Preoperative 3D imaging remains indispensable for such cases. Furthermore, our findings revealed no sex-related differences in Li position among the four morphological groups.

Regarding the Li–PB distance and the Li–AB/AB–PB proportion, Jansisyanont *et al.* [6] noted a mean Li–PB value of 18 mm and a 53.2% ratio. Park *et al.* [7] measured 18.89 mm and 55%, while Monnazzi *et al.* [8] reported 14.63 mm and 53%. Sekerci and Sisman [9] found 13.02 mm and 56%, and Senel *et al.* [10] calculated 16.9 mm and 53%. Lupi *et al.* [11] measured 15.28 mm with a 53% ratio. In our data set, the mean Li–PB distance was 15.23 mm, with no shape-dependent variations. The Li was positioned at 55% of the AB–PB span. The truncated group reached the largest ratio at 57%, while the assimilated type had only 50%. These statistically significant differences reflect how lingula form influences its anteroposterior placement.

#### *Distances from the sigmoid notch and inferior border to the lingula tip (SN–Li and IB–Li)*

Jansisyanont *et al.* [6] documented a mean SN–Li measurement of 16.6 mm. Lupi *et al.* [11] reported 13.87 mm for SN–Li, an IB–Li distance of 31.2 mm, and positioned the Li at 31% of the SN–IB span. Alves and Deana [12] found SN–Li at 17.29 mm, IB–Li at 33.3 mm, and the Li at 34%. Senel *et al.* [10] identified 18.1 mm for SN–Li and 38.3 mm for IB–Li, with the

Li at 32%. In the present sample, the mean SN–Li and IB–Li were 19.59 mm and 31.34 mm, respectively. No significant shape-related differences were observed for either measurement. The Li was positioned at 38.5% of the SN–IB range. This ratio differed among the four forms, with the nodular (39.9%) and truncated (39.6%) types showing significantly larger values than the assimilated form (34.5%).

Our observations show that lingula morphology substantially affects its vertical positioning. Prior investigations [6, 10–12] have reported variability in numeric measurements driven by demographic factors, reference plane selection, and landmark definitions. Nevertheless, the SN–Li/SN–IB ratio itself tends to remain relatively consistent between studies using dry mandibles and those using CBCT. In the current analysis, we did not compare right- and left-side measurements; accordingly, side-specific differences cannot be determined. Future work will examine whether average distances and ratios are symmetrical or display notable asymmetry across individuals.

During SSRO, surgeons must factor in not only the size of the Li and MF but also the vertical measure of the lingula. According to Alves and Deana [12], the lingula in a Brazilian Caucasian cohort averaged 8.89 mm in men and 7 mm in women. Zhou *et al.* [13] observed comparable trends in Korean adults, recording mean values of 10.1 mm for males and 9.8 mm for females, without noting a meaningful sex-related difference. Hsu *et al.* [14] reported that Taiwanese males had an average lingular height of 8.73 mm, which was significantly greater than the 7.76 mm reported for females. Regarding its relation to the occlusal plane, Jansisyanont *et al.* [6] stated that roughly 80% of lingulae rested 4.5 mm above this reference. Zhou *et al.* [13] similarly found that the lingula seldom appears inferior to the occlusal plane; instead, most lie about  $5.9 \pm 3.0$  mm above it. In addition, Akcay *et al.* [15] documented within a Turkish group that Class III individuals showed a mean value of 9.91 mm, which was significantly higher than the 8.12 mm observed in Class I subjects.

Attention must also be given to the thickness of cancellous and cortical bone between the SN and Li and to the junction where the medial and lateral cortices merge. Limited cancellous bone heightens the likelihood of an unfavorable split of the ramus during SSRO, even if the medial horizontal osteotomy does not reach the external cortex. Smith *et al.* [16] measured the Li-to-fusion-point distance along the vertical dimension to range between 7.5 and 13.3 mm and advised positioning the medial horizontal osteotomy at or just slightly above the Li. They

cautioned that carrying the cut too superiorly may make splitting more difficult or raise the probability of an adverse fracture. Tom *et al.* [17] showed that placing the osteotomy more than 5 mm above the Li increases the likelihood of intersecting the cortical fusion line. Suzen *et al.* [18] evaluated postoperative outcomes and reported that conducting the osteotomy above the Li correlated with fewer complications and fewer sensory disturbances than doing so below the Li. Performing the cut at the level of the Li, where cancellous bone is adequate, lowers the chance of a cortical-only split.

Jansisyanont *et al.* [6] measured the MF width at 4.7 mm, with values ranging from 2.9 to 6.8 mm. Park *et al.* [7] determined distances from the posterior MF border to the AB and PB as 19.69 mm and 14.41 mm, noting that this border is situated around 58% anteriorly and 46% superiorly relative to the ramus. Apinhasmit *et al.* [19] reported slightly different figures—22.3 mm to AB and 12.7 mm to PB—and placed the posterior margin at about 64% anteriorly. These results collectively show that the posterior MF border generally lies posterior to the lingula. Therefore, knowing the exact spatial relationship between the Li and MF is important in SSRO and IVRO. Wolford [20] recommended that the medial horizontal osteotomy begin above the Li and proceed posteriorly toward the region behind both the Li and MF. Muto *et al.* [21], in evaluating cancellous bone after applying this osteotomy, found that Class III skeletal patterns displayed narrower and more irregular cancellous bone, particularly around the anterior and posterior MF. They determined that the safest and most consistent osteotomy site is directly above the Li, extending backward by roughly 5–6 mm.

Preoperative imaging is necessary to verify the lingula's level relative to the occlusal plane when planning SSRO. Instruments must be used carefully to prevent accidental trauma to the lingula or MF, as such injuries may lead to substantial intraoperative bleeding or temporary lower-lip numbness after surgery. During the medial horizontal osteotomy, identifying the lingula visually or by palpation is not mandatory. To avoid injury to the IAN or associated vessels, the cut should be placed at least 5 mm above the occlusal plane.

## Conclusion

This study demonstrated notable positional differences among the four lingula configurations. Distinct variations were observed in the horizontal and vertical Li locations and in the ratios Li-AB/AB-PB and Li-SN/SN-IB. Among all shapes, the truncated form showed a significantly greater mean Li-AB distance.

Consequently, recognizing variations in lingula morphology and related spatial measurements is essential when performing SSRO or IVRO on the ramus.

**Acknowledgments:** None

**Conflict of Interest:** None

**Financial Support:** None

**Ethics Statement:** The study was approved by the institutional review board of Kaohsiung Medical University (IRB No. KMUH-IRB-20160066).

## References

1. Tuli A, Choudhry R, Choudhry S, Raheja S, Agarwal S. Variation in shape of the lingula in the adult human mandible. *J Anat.* 2000;197:313–7. doi:10.1046/j.1469-7580.2000.19720313.x
2. Rodríguez Vázquez JF, Mérida Velasco JR, Jiménez Collado J. Development of the human sphenomandibular ligament. *Anat Rec.* 1992;233:453–60. doi:10.1002/ar.1092330312
3. Hsu KJ, Lee HN, Chen CM. Morphological investigation of mandibular lingula: a literature review. *J Pers Med.* 2022;12:1015. doi:10.3390/jpm12061015
4. Colella G, Cannavale R, Vicidomini A, Lanza A. Neurosensory disturbance of the inferior alveolar nerve after bilateral sagittal split osteotomy: a systematic review. *J Oral Maxillofac Surg.* 2007;65:1707–15. doi:10.1016/j.joms.2007.05.009
5. Chen CM, Lee HN, Liang SW, Hsu KJ. Morphological study of the mandibular lingula and antilingula by cone-beam computed tomography. *Bioengineering.* 2023;10:170. doi:10.3390/bioengineering10020170
6. Jansisyanont P, Apinhasmit W, Chompoonpong S. Shape, height, and location of the lingula for sagittal ramus osteotomy in thais. *Clin Anat.* 2009;22:787–93. doi:10.1002/ca.20849
7. Park JH, Jung HD, Kim HJ, Jung YS. Anatomical study of the location of the antilingula, lingula, and mandibular foramen for vertical ramus osteotomy. *Maxillofac Plast Reconstr Surg.* 2018;40(1):15. doi:10.1186/s40902-018-0155-3
8. Monnazzi MS, Passeri LA, Gabrielli MF, Bolini PD, de Carvalho WR, da Costa Machado H. Anatomic study of the mandibular foramen, lingula and antilingula in dry mandibles, and its

- statistical relationship between the true lingula and the antilingula. *Int J Oral Maxillofac Surg.* 2012;41:74–8. doi:10.1016/j.ijom.2011.08.009
9. Sekerci AE, Sisman Y. Cone-beam computed tomography analysis of the shape, height, and location of the mandibular lingula. *Surg Radiol Anat.* 2014;36:155–62. doi:10.1007/s00276-013-1150-0
  10. Senel B, Ozkan A, Altug HA. Morphological evaluation of the mandibular lingula using cone-beam computed tomography. *Folia Morphol.* 2015;74:497–502. doi:10.5603/FM.2015.0114
  11. Lupi SM, Landini J, Olivieri G, Todaro C, Scribante A, Rodriguez Y, et al. Correlation between the mandibular lingula position and some anatomical landmarks in cone beam CT. *Healthcare.* 2021;9:1747. doi:10.3390/healthcare9121747
  12. Alves N, Deana NF. Morphological study of the lingula in adult human mandibles of Brazilians individuals and clinical implications. *Biomed Res Int.* 2015;2015:873751. doi:10.1155/2015/873751
  13. Zhou C, Jeon TH, Jun SH, Kwon JJ. Evaluation of mandibular lingula and foramen location using 3-dimensional mandible models reconstructed by cone-beam computed tomography. *Maxillofac Plast Reconstr Surg.* 2017;39:30. doi:10.1186/s40902-017-0128-y
  14. Hsu KJ, Tseng YC, Liang SW, Hsiao SY, Chen CM. Dimension and location of the mandibular Lingula: comparisons of gender and skeletal patterns using cone-beam computed tomography. *Biomed Res Int.* 2020;2020:2571534. doi:10.1155/2020/2571534
  15. Akcay H, Kalabalık F, Tatar B, Ulu M. Location of the mandibular lingula: comparison of skeletal class I and class III patients in relation to ramus osteotomy using cone-beam computed tomography. *J Stomatol Oral Maxillofac Surg.* 2019;120:504–8. doi:10.1016/j.jormas.2019.07.013
  16. Smith BR, Rajchel JL, Waite DE, Read L. Mandibular ramus anatomy as it relates to the medial osteotomy of the sagittal split ramus osteotomy. *J Oral Maxillofac Surg.* 1991;49:112–6. doi:10.1016/0278-2391(91)90095-4
  17. Tom WK, Martone CH, Mintz SMA. Study of mandibular ramus anatomy and its significance to sagittal split osteotomy. *Int J Oral Maxillofac Surg.* 1997;26:176–8. doi:10.1016/S0901-5027(97)80814-4
  18. Suzen M, Uckan S, Munevveroglu S, Ozel A. Effect of horizontal osteotomy level on complication rates and neurosensory deficits after sagittal split ramus osteotomy. *J Craniofac Surg.* 2021;32:1712–5. doi:10.1097/SCS.00000000000007404
  19. Apinhasmit W, Chompoopong S, Jansisanont P. Alternative landmarks of the mandibular foramen to prevent nerve injury during ramus surgery. *J Med Assoc Thai.* 2015;98:574–81.
  20. Wolford LM. Influence of osteotomy design on bilateral mandibular ramus sagittal split osteotomy. *J Oral Maxillofac Surg.* 2015;73:1994–2004. doi:10.1016/j.joms.2015.03.023
  21. Muto T, Shigeo K, Yamamoto K, Kawakami J. Computed tomography morphology of the mandibular ramus in prognathism: effect on the medial osteotomy of the sagittal split ramus osteotomy. *J Oral Maxillofac Surg.* 2003;61:89–93. doi:10.1053/joms.2003.50014