

Original Article

Evaluating the Brons–Mulié Analysis for Preoperative Decision-Making in Orthognathic Surgery

Jonas K. Weber^{1*}, Franz Müller¹, Anna L. Schmidt¹

¹Department of Oral Surgery, Faculty of Medicine, University of Heidelberg, Heidelberg, Germany.

*E-mail ✉ jonas.weber@outlook.com

Received: 06 May 2021; Revised: 14 August 2021; Accepted: 16 August 2021

ABSTRACT

Thorough preoperative preparation is a critical factor for successful orthognathic surgery outcomes. By applying different analytical approaches, dysgnathic regions can be accurately detected and specifically targeted during the planning phase. The Brons-Mulié soft-tissue analysis was applied to standardized profile photographs taken before and after orthognathic surgery. Achievement of normative values was regarded as evidence of restored facial harmony across the examined proportions. Direct comparison of pre- and postoperative measurements served as an objective quality control of the surgical results. A total of 160 patients (age range 13–61 years) had complete pre- and postoperative Brons-Mulié analyses available for comparison. Postoperatively, facial harmony was achieved in the vertical dimension in 99 patients (62%), in the upper lip region in 95 patients (59%), in the lower lip region in 138 patients (86%), and in the chin region in 118 patients (74%). This represented an improvement of 20% for the vertical dimension, 27% for the lower lip area, and 6% for the chin area. The upper lip region showed a minor worsening of 7%. Even when Brons-Mulié analysis is systematically used for preoperative planning of orthognathic surgery, postoperative outcomes demonstrate clear overall improvement yet rarely reach ideal harmony. Achieving perfect proportional balance remains challenging despite the use of this method.

Keywords: Brons–Mulié, Orthognathic, Dysgnathic regions, Surgery

How to Cite This Article: Weber JK, Müller F, Schmidt AL. Evaluating the Brons–Mulié Analysis for Preoperative Decision-Making in Orthognathic Surgery. *J Curr Res Oral Surg.* 2021;1:76-84. <https://doi.org/10.51847/UQr1KDe9Ac>

Introduction

Esthetics and facial beauty are fundamental considerations in the planning and execution of orthognathic surgery. The goal extends beyond establishing a stable, neutral occlusion to achieving an attractive and balanced overall facial appearance [1, 2]. However, how is esthetic quality objectively defined and quantified? To what degree should the jaws be repositioned to optimize both occlusion and facial esthetics? In the frontal view, parallelism between the bipupillary line and occlusal plane, as well as facial symmetry, is undoubtedly important [3-5]. Canut *et al.* emphasized that human facial beauty primarily depends on the balanced relationship between the three most prominent features: nose, lips, and chin [6]. Reuther described these elements as the “esthetic facial

triad,” underscoring their central role in preoperative facial analysis [7]. The soft-tissue analysis developed by Brons and Mulié, applicable to both lateral cephalograms and profile photographs, systematically evaluates these structures in the sagittal and vertical planes [8]. Facial harmony is considered present when the proportions of these anatomical components approximate the golden ratio [8]. Since orthognathic surgery can significantly alter the position and projection of the nose, lips, and chin, the procedure should aim to bring these elements as close as possible to harmonious proportions [8]. Although esthetic judgment ultimately remains subjective, adherence to mathematically derived harmonious proportions via the reproducible Brons-Mulié method provides an objective foundation for esthetic planning [8-10]. The method thus serves as a valuable adjunct for designing

a balanced facial profile, as previously reported by Freihofer *et al.* and Mooren [9, 10]. Gu *et al.* demonstrated a strong correlation between lateral and frontal facial attractiveness, suggesting that a harmonious profile predicts favorable frontal esthetics as well [11]. Furthermore, the same analysis can be employed postoperatively to objectively evaluate and refine surgical outcomes.

The present study investigates how frequently facial harmony is achieved or at least significantly improved through orthognathic surgery and whether the Brons–Mulié analysis is a reliable tool for preoperative decision-making and surgical simulation.

Materials and Methods

Preoperative planning protocol for orthognathic surgery

Surgical simulation has been a cornerstone of orthognathic treatment planning for decades [12]. It can be performed either analogically with an articulator or digitally using dedicated software [13]. In this investigation, all planning was carried out using the 3D-OSS articulator system developed by Krenkel and Lixl [14]. This device permits precise translational and rotational movements in all three spatial planes based on single-mounted plaster models, thereby facilitating particular attention to esthetic considerations. Mock surgery was conducted while simultaneously referencing facial photographs, lateral cephalograms, and Brons–Mulié analysis of profile images.

Assessment of profile photographs

Standardized profile photographs were obtained using a digital SLR camera positioned approximately 150 cm from the patient against a uniform blue background. The images were subsequently printed in color on A4

paper at near life-size scale (approximately 1:1). This format enabled manual performance of the Brons–Mulié soft-tissue analysis using pencil and set square, allowing direct visual and metric comparison with corresponding cephalometric radiographs.

Execution of the Brons–Mulié evaluation

About six weeks before the actual operation, the surgical team carried out the Brons–Mulié soft-tissue measurements during the mock surgery phase. To ensure reliability, the authors independently repeated the entire measurement protocol on postoperative profile pictures taken roughly six months after surgery. Following the original description by Brons [8], the nasofrontal reference was first marked, then a vertical reference line was constructed 15 degrees downward from the horizontal (**Figure 1**). In the vertical plane, the distance from nasion to subnasale (nasofacial height) and the length of the upper lip (maxillofacial height) were recorded. Using the Brons–Mulié formulas, the ideal lower-face height (mandibulofacial height) and its acceptable upper and lower limits were calculated. Lower-face height below the norm was labeled “short face,” above the norm “long face.” In the sagittal plane, the angles formed by the vertical reference line with the upper lip tangent (OLI), lower lip tangent (ULI), and chin tangent (MI) were measured. Acceptable corridors for these angles (with defined upper and lower boundaries) were derived from the individual nasal dorsum angle according to the original Brons–Mulié tables [8]. A backward-positioned profile was called dorsal, a forward-positioned profile ventral. All parameters lying inside the defined corridors were interpreted as facial harmony. **Figure 2** demonstrates the pre- and postoperative measurements in a Class III patient.

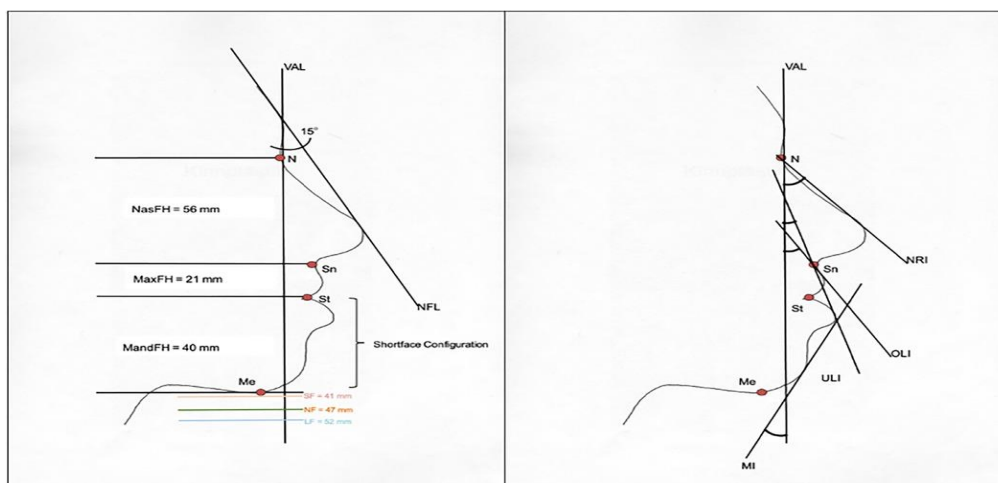


Figure 1. Schematic of Brons–Mulié measurements in vertical (left) and sagittal (right) planes. NFL nasofrontal line; VAL vertical reference line at 15°; NasFH nasofacial height; MaxFH maxillofacial height; MandFH mandibulofacial height; SF short-face limit; LF long-face limit; NF optimal mandibulofacial height;

NRI nasal dorsum angle; OLI upper lip angle; ULI lower lip angle; MI chin angle; N nasion; Sn subnasale; St stomion; Me menton.

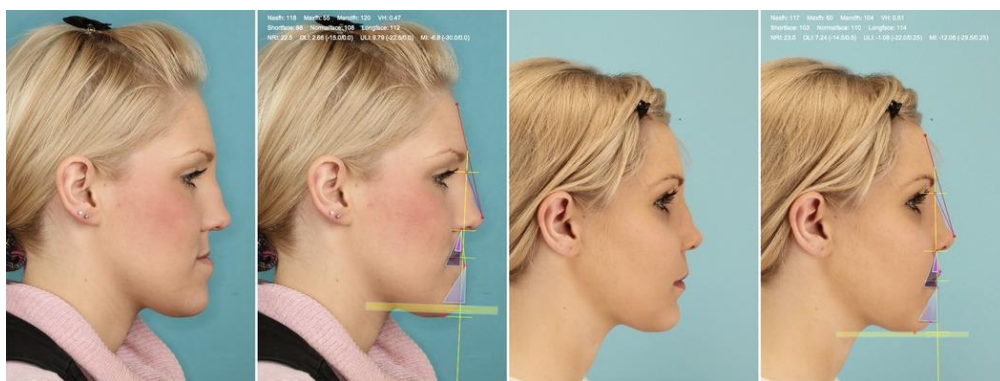

Figure 2. Example of Brons-Mulić measurements before and after surgery in a Class III case. Yellow band = ideal vertical zone; triangular zones = ideal inclination corridors for upper lip, lower lip, and chin.

Data from this retrospective exploratory study were processed with Microsoft Excel and SPSS® for Windows with assistance from the Department of Medical Statistics, Justus Liebig University Giessen. Every patient operated between February 2002 and February 2014 with complete records was included (n = 160). Preoperative versus postoperative Brons-Mulić values were compared directly. Fisher’s exact test was used to determine whether each parameter (vertical MandFH; sagittal OLI, ULI, MI) ended inside the normal corridor (success) or outside (failure). Logistic regression identified the factors most predictive of success or failure. Significance level was $p < 0.05$. Power calculation ($\alpha = 0.05$, odds ratio = 2) resulted in achieved power of 0.62–0.86 depending on the degree of preoperative deviation.

Results and Discussion

One hundred sixty patients who had orthognathic surgery from February 2002 to February 2014 were included. Females: 99 (62%), males: 61 (38%). Age range 13–61 years, median 23 years. Malocclusion distribution: Class II 64 patients (40%), Class III 92 patients (57.5%), remaining cases anterior open bite in Class I. Surgical procedures: bimaxillary osteotomies 123 patients (76.9%), isolated mandibular BSSO 24 patients (15%), isolated Le Fort I 13 patients (8.1%).

Rate of achieved facial balance

Harmony was separately evaluated for the vertical plane and the three sagittal angles (OLI, ULI, MI). Preoperatively, only a minority showed normal values in all areas. After surgery, a clear overall gain in balance was recorded, except for a small average worsening of upper lip position (OLI). Exact percentages and graphic comparison are given in **Table 1** and **Figure 3**.

Table 1. Proportion of patients inside normal Brons-Mulić ranges before versus after surgery (n = 160).

Facial Proportion	Pre-operative: In Harmony (Yes)	Pre-operative: Not in Harmony (No)	Pre-operative % in Harmony	Post-operative: In Harmony (Yes)	Post-operative: Not in Harmony (No)	Post-operative % in Harmony
Vertical Dimension	67	93	42%	99	61	62%
Upper Lip Index (ULI)*	106	54	66%	95	65	59%
Lower Lip Index (LLI)*	95	65	59%	138	22	86%
Mandibular/Chin Index (MI)	109	51	68%	118	42	74%
Facial Proportion	Improvement (n)	Aggravation (n)	Odds Ratio	95% CI (Lower)	95% CI (Upper)	p-value
Vertical Dimension	44	12	5.05	2.31	11.77	<0.01

Occlusal/Lower Lip Index (OLI)	21	32	3.60	1.73	7.66	<0.01
Upper Lip Index (ULI)	47	4	8.59	2.63	36.90	<0.01
Mandibular/Chin Index (MI)	23	14	8.12	3.51	19.64	<0.01

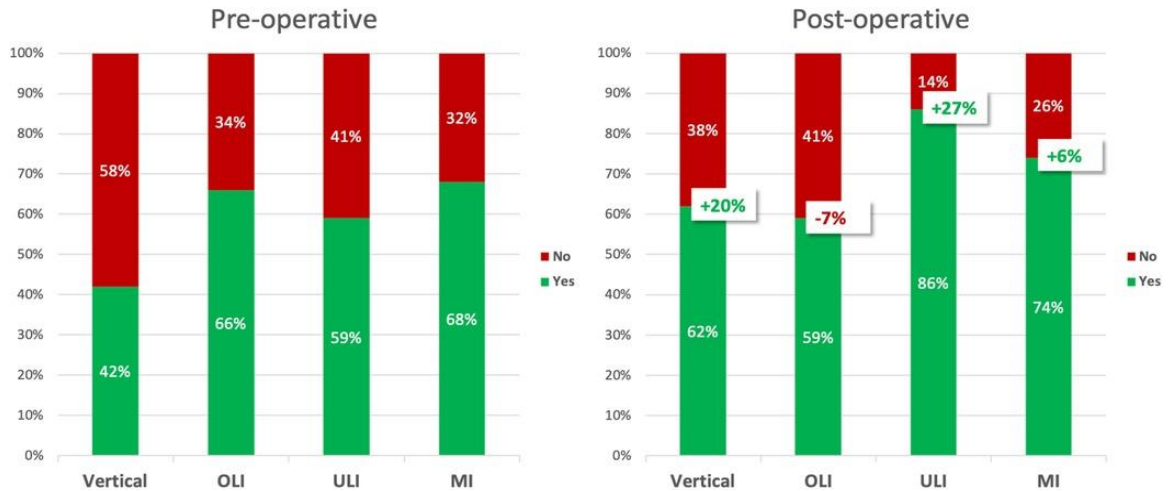


Figure 3. Percentage improvement of facial harmony after orthognathic surgery. Vertical = vertical dimension; OLI = upper lip angle; ULI = lower lip angle; MI = chin angle.

Predictors of outcome

Despite clear gains in facial balance after surgery (**Figure 3**), the total proportion of fully harmonious results remained limited. This prompted examination of which patient groups or deformity patterns were least likely to reach the target zones. **Table 2** presents success/failure rates stratified by preoperative Angle

classification. Fisher’s exact test revealed statistically significant differences for the vertical dimension and chin inclination (MI) (**Table 2**). Specifically, nearly 50% of Class III cases still lacked vertical harmony postoperatively, while almost 50% of Class II cases failed to achieve correct chin inclination.

Table 2. Postoperative facial harmony stratified by preoperative Angle class.

Facial Proportion	Angle Class	Yes (n)	Yes (%)	No (n)	No (%)	Total (n)	p-value
Vertical Dimension	Class I	3	75.0%	1	25.0%	4	
	Class II	47	73.4%	17	26.6%	64	
	Class III	49	53.3%	43	46.7%	92	
	Total	99	61.9%	61	38.1%	160	0.025*
Occlusal/Lower Lip Index (OLI)	Class I	3	75.0%	1	25.0%	4	
	Class II	40	62.5%	24	37.5%	64	
	Class III	52	56.5%	40	43.5%	92	
	Total	95	59.4%	65	40.6%	160	0.623
Upper Lip Index (ULI)	Class I	4	100.0%	0	0.0%	4	
	Class II	57	89.1%	7	10.9%	64	
	Class III	77	83.7%	15	16.3%	92	
	Total	138	86.2%	22	13.8%	160	0.716
Mandibular/Chin Index (MI)	Class I	4	100.0%	0	0.0%	4	
	Class II	34	53.1%	30	46.9%	64	
	Class III	80	86.9%	12	13.1%	92	
	Total	118	73.8%	42	26.2%	160	<0.001*

(*) Fisher’s exact test significant for vertical dimension and MI.

Logistic regression was then conducted, including the predictors Angle class, preoperative vertical height,

OLI, ULI, MI, gender, type of operation (Le Fort I / BSSO / bimaxillary), and age. The most parsimonious

Weber *et al.*, Evaluating the Brons–Mulić Analysis for Preoperative Decision-Making in Orthognathic Surgery
 model for each of the four outcome dimensions was
 chosen via the Akaike information criterion (**Table 3**).

Table 3. Logistic regression results for postoperative success in the four dimensions (vertical, OLI, ULI, MI). Variables selected by the Akaike criterion from the pool: Angle class, vertical height, OLI, ULI, MI, gender, surgery type, and age.

Outcome	Predictor	Df	Deviance	Residual Df	Residual Deviance	p-value
Vertical Dimension	Pre-op Vertical	2	24.9	157	187.79	<0.001 ***
	Pre-op OLI	2	6.53	155	181.27	0.038 *
	Pre-op MI	2	7.26	153	174.01	0.027 *
Mandibular Inclination (MI)	Pre-op MI	2	31.00	157	153.21	<0.001 ***
	Gender	1	1.86	156	151.36	0.173
	Surgery Type	2	9.23	154	142.13	0.01 **
Upper Lip Inclination (ULI)	Pre-op OLI	2	14.19	157	201.96	0.001 ***
	Pre-op MI	2	6.94	155	195.02	0.031 *
	Pre-op ULI	2	11.85	153	183.17	0.003 **
Lower Lip Inclination (LLI)	Pre-op ULI	2	18.56	157	109.57	<0.001 ***
	Gender	1	3.29	156	106.28	0.07 .
	Age	1	3.43	155	102.85	0.064 .

Key findings:

- Preoperative long-face pattern was the strongest negative predictor of vertical success (high failure rate in long-face patients); (**Tables 3 and 4**).
- Extreme preoperative chin inclination (either too retrognathic or too prognathic) strongly predicted persistent disharmony of MI postoperatively.
- For lower lip inclination (ULI), the preoperative lower-lip position itself was the dominant determinant of final success. Very few patients starting with extreme values in these parameters reached the normal corridor after surgery (**Table 4**).

Table 4. Detailed breakdown of how specific preoperative deviations influenced postoperative success (extension of **Table 3**).

<i>1. Success: Vertical Dimension</i>							
Predictor	Estimate	Odds Ratio	95% CI (Lower)	95% CI (Upper)	Std. Error	z value	p-value
Intercept	2.06	7.82	3.76	18.82	0.41	4.97	<0.001
Pre-op Vertical: SF	-0.59	0.56	0.18	1.71	0.56	-1.04	0.298
Pre-op Vertical: LF	-2.17	0.11	0.05	0.27	0.45	-4.79	<0.001
Pre-op OLI: H	-1.01	0.36	0.14	0.90	0.47	-2.15	0.031
Pre-op OLI: L	0.98	2.67	0.81	10.73	0.65	1.51	0.13
Pre-op MI: H	-0.06	0.94	0.26	3.42	0.64	-0.09	0.929
Pre-op MI: L	-1.33	0.26	0.09	0.70	0.51	-2.61	0.009
<i>2. Success: Mandibular/Chin Index (MI)</i>							
Predictor	Estimate	Odds Ratio	95% CI (Lower)	95% CI (Upper)	Std. Error	z value	p-value
Intercept	18.47	–	0.00	1048.17	0.02	0.986	–
Pre-op MI: H	-1.75	0.17	0.05	0.60	0.63	-2.77	0.006
Pre-op MI: L	-2.19	0.11	0.04	0.28	0.49	-4.47	<0.001
Gender: Female	-0.78	0.46	0.18	1.13	0.47	-1.67	0.095
BSSO	-15.25	0.00	0.00	1048.17	-0.01	0.988	–
Bimaxillary	-16.34	0.00	–	1048.17	-0.02	0.988	–
<i>3. Success: Occlusal/Lower Lip Index (OLI)</i>							

Predictor	Estimate	Odds Ratio	95% CI (Lower)	95% CI (Upper)	Std. Error	z value	p-value
Intercept	0.95	2.57	1.53	4.49	0.27	3.46	0.001
Pre-op OLI: H	-1.09	0.34	0.12	0.88	0.50	-2.19	0.029
Pre-op OLI: L	-1.15	0.32	0.10	0.95	0.57	-2.03	0.042
Pre-op MI: H	2.08	7.98	2.02	42.03	0.76	2.75	0.006
Pre-op MI: L	0.70	2.01	0.80	5.44	0.48	1.44	0.15
Pre-op ULI: H	-0.96	0.38	0.16	0.93	0.45	-2.12	0.034
Pre-op ULI: L	-1.98	0.14	0.03	0.50	0.69	-2.87	0.004

4. Success: Upper Lip Index (ULI)

Predictor	Estimate	Odds Ratio	95% CI (Lower)	95% CI (Upper)	Std. Error	z value	p-value
Intercept	1.27	3.56	0.53	23.21	0.95	1.34	0.179
Pre-op ULI: H	-2.24	0.11	0.03	0.34	0.63	-3.54	<0.001
Pre-op ULI: L	-2.74	0.06	0.01	0.30	0.80	-3.42	0.001
Gender: Female	0.98	2.67	0.99	7.59	0.51	1.91	0.056
Age	0.06	1.06	1.00	1.15	0.04	1.69	0.092

SF short face; LF long face; H too high; L too low; BSSO bilateral sagittal split osteotomy; Bimax bimaxillary surgery.

Meticulous preoperative preparation is indispensable for satisfactory orthognathic results [12]. The aim must extend beyond stable occlusion to deliver functional and visually pleasing facial proportions [2, 9, 10, 12, 15]. Patients often value correction of facial disharmony at least as highly as restoration of bite function [16]. Achieving balanced aesthetics has been shown to improve compliance and psychological well-being [17, 18], underlining the central role of esthetics in modern orthognathic treatment.

Facial attractiveness arises from symmetry, average proportions, and balanced relationships between facial thirds and prominent features [5, 9]. Lateral profile harmony reliably predicts frontal attractiveness [11]. Because jaw surgery profoundly affects both vertical and sagittal soft-tissue relationships, Freihofer and Mooren advocated defining a precise target profile line preoperatively [9]. However, they also demonstrated that hand-drawn target profiles vary widely even among experienced surgeons and are heavily influenced by personal taste [9]. To reduce subjectivity, they strongly endorsed the Brons-Mulié method as an objective, reproducible guide for planning the desired postoperative soft-tissue contour [9, 10].

The Brons-Mulié system provides a straightforward, clinically practical instrument for quantifying facial balance that usefully complements conventional cephalometric planning [8]. In the vertical plane, it directly evaluates lower-facial height proportions. In the sagittal plane, it assesses chin projection independently of cranial-base angulation and adds objective evaluation of lip posture—areas where standard skeletal cephalometrics are limited [8].

In this series of 160 patients, a Brons-Mulié evaluation was routinely performed before surgery to guide the planning toward a balanced profile. Results were subsequently checked with a second analysis performed on photographs taken six months postoperatively. The findings confirm that, even when this method is actively used in decision-making, reaching the ideal zones in both vertical and sagittal planes remains challenging in a considerable number of cases. As shown in **Table 1** and **Figure 1**, meaningful gains were limited to the vertical dimension (+20%) and lower lip inclination (+27%), whereas chin inclination improved only marginally (+6%) and upper lip inclination actually worsened slightly (-7%).

These modest overall improvements probably stem from two main limitations of the method: (1) it reliably highlights which parameters are outside the normal corridors but does not specify the exact millimetres or degrees of jaw movement required to enter the target zone; (2) isolated correction of one parameter is rarely possible because moving the jaws inevitably affects multiple soft-tissue relationships simultaneously (e.g., excessive upward repositioning of a long chin risks creating a gummy smile). Consequently, surgeons are sometimes forced to accept residual deviations during planning.

Nevertheless, the Brons-Mulié system remains valuable because it objectifies esthetic shortcomings and reveals the realistic boundaries of skeletal movement. For instance, in Class II patients with flat chin inclination, the analysis clearly justifies mandibular advancement or conversion to bimaxillary surgery with forward–downward rotation of the maxillomandibular complex, yielding far better chin

projection [19–24]. Conversely, in Class III patients with long-face pattern and steep mandibular plane, the method often signals that simple maxillary advancement would worsen the profile and that bimaxillary surgery with clockwise rotation and moderate mandibular setback is aesthetically superior [25–27].

Statistical analysis (Fisher’s exact) (**Table 2**); (logistic regression) (**Tables 3 and 4 and Figure 3**) further identified deformity patterns that are particularly resistant to correction:

- Class III patients frequently retained excessive vertical height after surgery.
- Class II patients often failed to achieve adequate chin inclination.

Regression revealed that preoperative long-face pattern (LF) reduced the odds of postoperative vertical success

to 0.11, and preoperative retruded chin inclination (low MI) similarly reduced the odds of normal postoperative MI to 0.11. These low success rates reflect practical constraints: in Class III cases, airway-preserving anterior–caudal positioning of the maxillomandibular complex makes significant impaction difficult [28], while in severe Class II cases, even large bimaxillary advancement may not advance the soft-tissue pogonion sufficiently (**Figure 5**). In both scenarios, an additional genioplasty—reductive in long-face Class III, augmentative in retrusive-chin Class II—emerges as the most effective solution [29–31]. Genioplasty can be performed simultaneously or as a secondary procedure at six months, at which point a new Brons-Mulić analysis again proves helpful for precise planning [32].

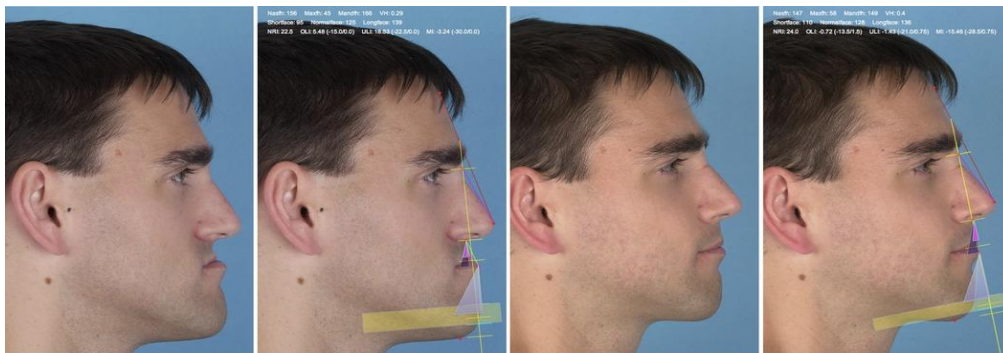

Figure 4. Class III patient before and after surgery. Chin inclination reached the normal corridor, but a persistent long-face pattern in the vertical dimension.

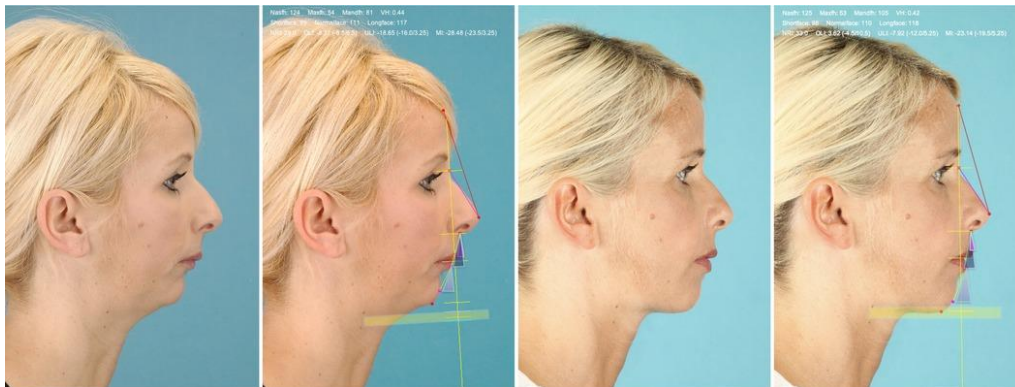


Figure 5. Class II patient before and after surgery. Vertical dimension normalised, but chin inclination remained too flat despite major profile improvement.

Conclusion

The Brons-Mulić method is a straightforward, clinically practical supplement to conventional cephalometric planning that objectively quantifies soft-tissue disharmony before orthognathic surgery. Its postoperative application allows critical quality control of aesthetic results and highlights residual deficits. In many patients, final facial balance can only be achieved

by adding a targeted genioplasty once the primary dentoskeletal correction has been completed.

Acknowledgments: None

Conflict of Interest: None

Financial Support: None

Ethics Statement: The studies involving humans were approved by Ethics Committee at the Faculty of Medicine at Justus Liebig University Giessen. The studies were conducted in accordance with the local legislation and institutional requirements. The human samples used in this study were acquired from a by-product of routine care or industry. Written informed consent for participation was not required from the participants or the participants' legal guardians/next of kin in accordance with the national legislation and institutional requirements. Written informed consent was obtained from the individual(s) for the publication of any potentially identifiable images or data included in this article.

References

1. Arnett GW, Bergman RT. Facial Keys to Orthodontic Diagnosis and Treatment Planning. Part I. *Am J Orthod Dentofacial Orthop.* 1993;103:299–312. doi:10.1016/0889-5406(93)70010-L
2. Bass NM. *The Aesthetic Analysis of the Face.* Oxford: Oxford University Press; 1991. p. 343–50. doi:10.1093/ejo/13.5.343
3. Kochel J, Meyer-Marcotty P, Strnad F, Kochel M, Stellzig-Eisenhauer A. 3d soft tissue analysis—part 1: sagittal parameters. *J Orofac Orthop.* 2010;71(1):40–52. doi:10.1007/s00056-010-9926-x
4. Beckmann-van der Ven G, Segner D, Hasund A. Die Erfassung Der Gesichtswichteiloberfläche in Drei Dimensionen Unter Besonderer Berücksichtigung Der Mandibula. *Fortschritte der Kieferorthopädie: Springer-Verlag;* 1985. p. 279–87. doi:10.1007/BF02164205
5. Hönn M, Göz G. The ideal of facial beauty: a review. *J Orofac Orthop.* 2007;68:6–16. doi:10.1007/s00056-007-0604-6
6. Canut J. Extraktion oder nichtextraktion: ästhetische erwägungen. In: Bolender C, G B, B Y, editors. *Extraction Versus Nonextraction.* München: Neuer Merkur Verlag; 1995. p. 203–13.
7. Reuther J. Orthognathe chirurgie: skelettverlagernde operationen. *Mund Kiefer Gesichtschir.* 2013;4:S237–S48. doi:10.1007/PL00014545
8. Brons R. *Facial Harmony: Standards for Orthognathic Surgery and Orthodontics.* Chicago: Quintessence Publishing Co Inc. U.S; 1998.
9. Freihofer HP, Mooren RE. Profiloplasty: variations in personal views. *J Craniomaxillofac Surg.* 1997;25(5):249–53. doi:10.1016/s1010-5182(97)80061-3
10. Mooren RE, Freihofer HP, Borstlap WA. Reproducibility of aimed-at profiles. *J Craniomaxillofac Surg.* 1998;26(1):22–8. doi:10.1016/s1010-5182(98)80031-0
11. Gu JT, Avilla D, Devcic Z, Karimi K, Wong BJB. Association of frontal and lateral facial attractiveness. *JAMA Facial Plast Surg.* 2018;20(1):19–23. doi:10.1001/jamafacial.2017.0710
12. Bamber MA, Harris M, Nacher C. A validation of two orthognathic model surgery techniques. *J Orthod.* 2001;28:135–42. doi:10.1093/ortho/28.2.135
13. Aboul-Hosn Centenero S, Hernández-Alfaro F. 3d Planning in orthognathic surgery: cad/cam surgical splints and prediction of the soft and hard tissues results E our experience in 16 cases. *J Craniomaxillofac Surg.* 2012;40:162–8. doi:10.1016/j.jcms.2011.03.014
14. Krenkel C, Lixl G. Model surgical apparatus for planning and simulation of maxillary and mandibular osteotomies. *Zahnärztl Prax.* 1991;42:471–3.
15. Hönn M, Dietz K, Godt A, Göz G. Perceived relative attractiveness of facial profiles with varying degrees of skeletal anomalies. *J Orofac Orthop.* 2005;66:187–96. doi:10.1007/s00056-005-0445-0
16. Steenen SA, van Teeseling RA, Vulink NC, Becking AG. Psychological aspects of orthognathic surgery. *Ned Tijdschr Tandheelkd.* 2014;121(9):446–52. doi:10.5177/ntvt.2014.09.14114
17. Brucoli M, Zeppego P, Benech R, Boffano P, Benech A. Psychodynamic features associated with orthognathic surgery: a comparison between conventional orthognathic treatment and “surgery-first” approach. *J Oral Maxillofac Surg.* 2019;77(1):157–63. doi:10.1016/j.joms.2018.06.005
18. Wang BL, Yang ML. Psychological status of patients with skeletal class iii malocclusion undergoing bimaxillary surgery: a comparative study. *Medicine.* 2024;103(34):e39435. doi:10.1097/md.00000000000039435
19. Shelly AD, Southard TE, Southard KA, Casco JS, Jakobsen JR, Fridrich KL, et al. Evaluation of profile esthetic change with mandibular advancement surgery. *Am J Orthod Dentofacial Orthop.* 2000;117(6):630–7. doi:10.1016/S0889-5406(00)70171-5
20. Tsang ST, McFadden LR, Wiltshire WA, Pershad

- N, Baker AB. Profile changes in orthodontic patients treated with mandibular advancement surgery. *Am J Orthod Dentofacial Orthop.* 2009;135(1):66–72. doi:10.1016/j.ajodo.2007.01.033
21. Klaus K, Heumann C, Ruf S. Effect of orthognathic surgery on profile esthetics in class ii:1 malocclusions. *J Orofac Orthop.* 2017;78(6):472–9. doi:10.1007/s00056-017-0099-8
22. Raposo R, Peleteiro B, Paço M, Pinho T. Orthodontic camouflage versus orthodontic-orthognathic surgical treatment in class ii malocclusion: a systematic review and meta-analysis. *Int J Oral Maxillofac Surg.* 2018;47(4):445–55. doi:10.1016/j.ijom.2017.09.003
23. Balasubramanian B, Sundaram NR, Boovaraghavan S, Gali RS, Venkatachalapathy S, Natarajan K. Management of class ii hyperdivergent mandible by surgically altering occlusal plane pattern through counterclockwise rotation of mandible. *J Contemp Dent Pract.* 2021;22(9):1048–54. doi:10.5005/jp-journals-10024-3146
24. Ruslin M, Hajrah Yusuf AS, Forouzanfar T, Greebe RB, Tuinzing DB, Thamrin SA, et al. One-Year stability of the mandibular advancement and counterclockwise rotation for correction of the skeletal class ii malocclusion and high mandibular plane angle: dental and skeletal aspect. *Biomed J.* 2022;45(1):206–14. doi:10.1016/j.bj.2021.02.005
25. Ellis E, McNamara JA. Components of adult class iii open-bite malocclusion. *Am J Orthod.* 1984;86:277–90. doi:10.1016/0002-9416(84)90138-6
26. Cao Y, Zhou Y, Li Z. Surgical-orthodontic treatment of class iii patients with long face problems: a retrospective study. *J Oral Maxillofac Surg.* 2009;67(5):1032–8. doi:10.1016/j.joms.2008.11.017
27. Kor HS, Yang HJ, Hwang SJ. Relapse of skeletal class iii with anterior open bite after bimaxillary orthognathic surgery depending on maxillary posterior impaction and mandibular counterclockwise rotation. *J Craniomaxillofac Surg.* 2014;42(5):e230–8. doi:10.1016/j.jcms.2013.08.013
28. He J, Wang Y, Hu H, Liao Q, Zhang W, Xiang X, et al. Impact on the upper airway space of different types of orthognathic surgery for the correction of skeletal class iii malocclusion: a systematic review and meta-analysis. *Int J Surg.* 2017;38:31–40. doi:10.1016/j.ijssu.2016.12.033
29. Ramanathan M, Panneerselvam E, Parameswaran A, Kanno T. Genioplasty in contemporary orthognathic surgery. *Oral Maxillofac Surg Clin North Am.* 2023;35(1):97–114. doi:10.1016/j.coms.2022.06.009
30. San Miguel Moragas J, Oth O, Büttner M, Mommaerts MY. A systematic review on soft-to-hard tissue ratios in orthognathic surgery part ii: chin procedures. *J Craniomaxillofac Surg.* 2015;43(8):1530–40. doi:10.1016/j.jcms.2015.07.032
31. Park JY, Kim MJ, Hwang SJ. Soft tissue profile changes after setback genioplasty in orthognathic surgery patients. *J Craniomaxillofac Surg.* 2013;41(7):657–64. doi:10.1016/j.jcms.2013.01.005
32. Torgersbråten N, Stenvik A, Espeland L. Bimaxillary surgery to correct high- angle class ii malocclusion: does a simultaneous genioplasty affect long-term stability? *Eur J Orthod.* 2020;42(4):426–33. doi:10.1093/ejo/cjz055