Asian Journal of Periodontics and Orthodontics
2026, Volume 6, Issue 2, Page No: 61-72
Copyright CC BY-NC-SA 4.0
Available online at: www.tsdp.net

ISSN: 3062-3499

Original Article

Sequencing Orthodontic Space Redistribution and Implant Placement in Adults with Periodontal Attachment Loss: A Decision Architecture for Root Position, Ridge Preservation, and Irreversible Treatment Commitments

Hassan Al-Rashid[1]*, Faisal Al-Harbi[2]

[1]Department of Implant Dentistry, King Fahd University of Petroleum and Minerals, Dhahran, Saudi Arabia.
[2]Department of Orthodontics, King Saud University, Riyadh, Saudi Arabia.

***E-mail** ✉ hassan.alrashid@kfupm.edu.sa

Received: 27 July 2026; **Revised:** 30 August 2026; **Accepted:**3 September 2026

ABSTRACT

Multidisciplinary rehabilitation in adults with periodontal attachment loss may require both orthodontic redistribution of tooth position and implant-supported replacement of missing or non-maintainable teeth. These interventions differ fundamentally in reversibility: root positions, interradicular relationships, and some aspects of ridge form can remain modifiable during staged treatment, whereas implant placement fixes a three-dimensional position that cannot subsequently participate in orthodontic tooth movement. This non-empirical interdisciplinary decision analysis integrates contemporary periodontal treatment guidance, clinical evidence on orthodontic treatment in reduced but treated periodontia, studies of regenerative-periodontal and orthodontic timing, three-dimensional root and alveolar assessment, and implant-placement and ridge-preservation evidence. Evidence was interpreted according to whether it established biological feasibility, spatial information, treatment-effect evidence, methodological uncertainty, or a basis for original clinical synthesis. The evidence does not support a universal rule that orthodontics must always precede implant placement, nor does it justify a single waiting interval after periodontal therapy or regeneration. Instead, sequencing depends on whether clinically consequential root, alveolar, ridge, and restorative relationships remain modifiable; whether periodontal stability and maintenance are adequate; how reliably those relationships can be measured; and how much a proposed intervention would close subsequent corrective options. Immediate, early, and delayed implant strategies may each be reasonable in selected circumstances, but their evidence does not remove the need to resolve patient-specific spatial conflicts before irreversible fixture positioning. Implant placement should be interpreted as a progressive commitment within an interdisciplinary sequence rather than as an isolated replacement event. When unresolved root position, interradicular space, periodontal support, ridge configuration, or measurement uncertainty could materially alter the definitive implant position, maintaining reversibility until those uncertainties have been adequately addressed provides a defensible organizing principle. This principle remains a proposed decision architecture rather than a validated treatment algorithm.

Keywords: Periodontitis, Orthodontic tooth movement, Dental implants, Root position, Alveolar ridge preservation, Interdisciplinary treatment

How to Cite This Article: Al-Rashid H, Al-Harbi F. Sequencing Orthodontic Space Redistribution and Implant Placement in Adults with Periodontal Attachment Loss: A Decision Architecture for Root Position, Ridge Preservation, and Irreversible Treatment Commitments. Asian J Periodont Orthodont. 2026;6(2):61-72. https://doi.org/10.51847/mLgcxlbsgX

Introduction

Periodontitis creates a rehabilitation problem that extends beyond the amount of attachment already lost. Contemporary staging incorporates disease severity, complexity, tooth loss, functional consequences, and treatment difficulty rather than reducing prognosis to one anatomical measurement [1]. The current classification likewise distinguishes the presence and extent of periodontal destruction from the broader

© 2026 Asian Journal of Periodontics and Orthodontics

clinical interpretation required for case management [2]. For interdisciplinary rehabilitation, that distinction is important because historical attachment loss does not by itself determine whether a tooth remains maintainable, whether orthodontic movement is feasible, or whether replacement should proceed immediately.

Contemporary periodontal treatment is consequently organized around control of active disease, reassessment, correction of residual problems, and supportive care rather than a single procedural endpoint [3]. Stage IV disease adds functional rehabilitation, pathologic tooth migration, occlusal dysfunction, advanced tooth loss, and the need for multidisciplinary planning to those periodontal objectives [4]. A patient may therefore reach a point at which periodontal inflammation is acceptably controlled while the dentition still requires major redistribution of tooth position, correction of migrated roots, replacement of missing teeth, or management of a deficient extraction ridge.

Clinical evidence supports orthodontic treatment in appropriately treated periodontitis, but it does not justify treating all reduced periodontia as biologically equivalent or all interdisciplinary sequences as interchangeable. Systematic reviews collectively indicate that orthodontic movement can be undertaken in selected periodontally compromised patients, including patients with advanced disease and intrabony defects, while also emphasizing substantial heterogeneity in case selection, periodontal treatment, biomechanics, maintenance, and outcome reporting [5–7]. The defensible inference is therefore conditional feasibility rather than unrestricted safety.

The central sequencing problem becomes most apparent when an implant is being considered within the same region in which tooth positions remain modifiable. Orthodontic movement may change mesiodistal space, root angulation, interradicular separation, alveolar relationships, and the location from which a definitive restoration must emerge. Implant placement, in contrast, converts a proposed restorative location into an osseointegrated fixture position that cannot subsequently be moved orthodontically. This asymmetry makes the order of treatment clinically meaningful even when each intervention, considered independently, is technically feasible.

The purpose of this analysis is to determine which biological and spatial conditions should be clarified before orthodontic space redistribution is translated into implant placement, which uncertainties may appropriately remain unresolved, and when an irreversible intervention closes clinically valuable options. The intended contribution is not a universal orthodontics-first protocol. It is an evidence-bounded account of how current periodontal status, root geometry, ridge preservation, measurement uncertainty, implant-site selection, and reversibility can be integrated when several defensible treatment sequences are possible.

Biological and spatial dependencies in multidisciplinary rehabilitation

Treatment sequence cannot be derived from elapsed time alone. In a multicenter randomized trial of patients with Stage IV periodontitis and intrabony defects treated regeneratively, initiating orthodontic therapy four weeks after surgery did not produce inferior primary periodontal improvement compared with delaying orthodontics for six months [8]. The finding directly challenges the assumption that biological prudence always requires a prolonged fixed interval before tooth movement. It does not, however, establish four weeks as a universal readiness threshold. The studied patients had defined defects, structured periodontal treatment, specialist follow-up, and clinical conditions that cannot be presumed in every reduced periodontium.

Observational evidence supports the same distinction between what is possible and what is universally indicated. A practice-based cohort in which orthodontic movement followed regenerative periodontal surgery demonstrated favorable periodontal and radiographic outcomes in selected patients [9]. Long-term follow-up of a related clinical population showed that favorable periodontal changes could remain stable for many years under continuing care [10]. These findings make combined periodontal and orthodontic rehabilitation biologically credible, but neither study supplies an invariant treatment interval or proves that the same sequence performs identically when inflammation control, compliance, defect morphology, tooth mobility, loading, or supportive care differ.

Periodontal status at the time of sequencing therefore matters more than historical destruction alone. A systematic review of supportive periodontal care demonstrates that periodontal stability and completeness of treatment are related to subsequent tooth-loss patterns, although definitions of stability and study designs remain heterogeneous [11]. Long-term clinical observation likewise shows that teeth in periodontitis-susceptible patients can remain serviceable for decades when active therapy is followed by sustained supportive care [12]. In an

interdisciplinary sequence, previous attachment loss should consequently be interpreted as a biological and mechanical constraint, not an automatic instruction to replace the tooth.

Spatial conditions require a similarly state-dependent interpretation. Alveolar bone thickness around anterior roots varies with skeletal morphology and tooth inclination [13]. Dehiscence and fenestration also differ across dentoalveolar configurations and may be present before orthodontic treatment begins [14]. These observations are important because a root that appears unfavorably positioned relative to a proposed implant space may coexist with a limited or asymmetric bony housing. Correcting crown position without considering root position may therefore produce an apparently adequate restorative gap while leaving an unfavorable interradicular or alveolar configuration.

Periodontal support, root geometry, the alveolar envelope, the edentulous ridge, and the intended prosthetic position are thus interdependent but not equivalent variables. Some describe biological readiness; others describe spatial feasibility; still others determine whether later correction will remain possible. **Table 1** distinguishes these functions so that a sequencing decision is not reduced to a single measurement or waiting period.

Table 1. Biological and spatial variables that determine whether an interdisciplinary sequence remains modifiable before implant placement

Sequencing variable	What must be understood before irreversible implant positioning	What can still change during staged treatment	Consequence of premature commitment	Appropriate interpretation
Current periodontal inflammatory state	Whether active inflammation has been controlled sufficiently for planned tooth movement and restorative care	Inflammatory control, plaque control, supportive-care intensity, reassessment findings	Implant planning may proceed from a biologically unstable reference state	A current treatment-state variable, not a judgment based only on previous attachment loss
Remaining periodontal support	Distribution and asymmetry of attachment support around teeth expected to move or border the implant site	Tooth position and loading environment can be modified; lost support cannot simply be assumed recoverable	Movement may be planned as though a conventionally supported tooth were present	A mechanical and biological boundary requiring individualized interpretation
Root position and interradicular geometry	Root angulation, proximity, divergence, and relation to the proposed fixture corridor	Root positions can often be changed orthodontically before implant placement	A fixture may occupy space later required for root correction or acceptable restorative emergence	A potentially modifiable spatial variable with direct sequencing relevance
Alveolar housing around adjacent teeth	Buccal/lingual or facial/palatal bone boundaries and pre-existing defects	Tooth position relative to the housing may change; anatomy itself may remain restrictive	Crown-space correction may conceal an unfavorable root–bone relationship	An anatomical constraint rather than a universal numerical movement limit
Edentulous-site ridge configuration	Ridge volume, contour, defect form, soft-tissue environment, and relationship to neighboring roots	Preservation or augmentation may change aspects of site form before definitive placement	Implant position may be selected around a temporarily deficient ridge rather than the intended final site	A site-development variable that must be integrated with orthodontic objectives
Intended restorative position	Desired crown location, emergence direction, occlusal relationship, and restorative access	Orthodontic space distribution and adjacent tooth positions may be modified	Fixture position may satisfy existing space while compromising the intended final restoration	The prosthetic endpoint should inform, but not independently dictate, fixture position
Maintenance capacity	Ability to sustain periodontal and peri-implant care during prolonged multidisciplinary treatment	Recall intensity and preventive support can be adapted	A biologically or mechanically acceptable plan may fail under inadequate maintenance	A longitudinal condition rather than a one-time eligibility criterion

Measurement certainty	Reliability with which roots, bone boundaries, and site anatomy have been characterized	Information can be refined through additional or repeated assessment when clinically justified	Irreversible decisions may be made on falsely precise or incomplete spatial information	Uncertainty should remain visible in the treatment decision rather than converted into a false threshold

The central implication is that multidisciplinary rehabilitation should proceed from a current biological-spatial state, not from diagnosis alone. Periodontal control establishes whether further tooth movement can reasonably be considered; root and ridge relationships determine what must still be modified; and maintenance determines whether favorable conditions can be sustained. These dependencies are prerequisites for sequencing but do not themselves specify the sequence.

Orthodontic space redistribution before implant placement

Orthodontic space redistribution becomes particularly consequential when the therapeutic objective is not merely to create a crown-width gap but to produce a three-dimensional site compatible with implant placement. Mesiodistal crown space may appear adequate while adjacent roots remain convergent, displaced, or otherwise positioned unfavorably. Conversely, correcting root relationships may change the apparent size or center of the edentulous space and may alter the site that subsequently requires preservation, augmentation, or implant preparation.

An expected-root-position method has been evaluated specifically for determining root proximity adjacent to an edentulous implant site [15]. Its importance to sequencing lies less in the performance of one particular software workflow than in the problem it exposes: restorative space visible at the crowns does not necessarily describe the root-level corridor into which an implant would be placed. When adjacent roots are orthodontically movable, their final relationship should be considered part of site preparation rather than treated as a fixed background condition.

Root information also need not remain static throughout treatment. Digital methods using serial intraoral scans and automated registration have been investigated for repeated assessment of root position during orthodontic therapy [16]. Such approaches support an iterative interpretation of spatial development: a planned implant site can be reassessed as tooth movement progresses rather than judged solely from pretreatment crown positions or a one-time projected setup. Methodological accuracy and clinical applicability remain technology-dependent, so repeated assessment should not be mistaken for perfect knowledge.

The clinical importance of incorporating root and bone information into treatment planning is reinforced by evidence that clinicians may alter their treatment choices when these structures are visible. In a study of virtual orthodontic setups, access to crown, root, and bone information changed planning decisions for a meaningful proportion of participating orthodontists [17]. A changed plan is not necessarily a better plan, but the observation demonstrates that clinically consequential information may be absent when treatment is planned from crown relationships alone.

At the same time, greater imaging detail does not eliminate uncertainty. The visibility of thin alveolar bone on cone-beam computed tomography varies with acquisition, reconstruction, resolution, and viewing conditions [18]. Apparent boundaries therefore cannot automatically be converted into precise biological limits. In a periodontally reduced dentition, this is particularly important because decisions may concern roots already located near a diminished cortical envelope. The sequencing question is not simply whether imaging shows sufficient bone, but how confidently the observed geometry can support an irreversible treatment commitment.

Orthodontic space redistribution should consequently be understood as an opportunity to resolve modifiable spatial conflicts while the dentition remains changeable. It does not follow that every patient requires completion of all orthodontic treatment before any implant-related procedure. Ridge preservation, extraction-site management, temporary prosthetic treatment, periodontal therapy, and orthodontic movement may overlap in carefully coordinated sequences. What should not be lost is the distinction between actions that preserve later correction and actions that permanently constrain it.

The clinically plausible sequences in **Table 2** differ mainly in which uncertainties they allow to remain unresolved before transition to the next phase.

Table 2. Alternative periodontal–orthodontic–implant sequences according to the spatial problem that remains unresolved

Sequence pattern	Spatial problem the sequence is intended to address	Information required before transition	Options retained while treatment remains reversible	Principal residual uncertainty
Periodontal stabilization → orthodontic root redistribution → final implant-site development → implant placement	Inadequate interradicular geometry or displaced adjacent roots are central obstacles	Current periodontal stability, root trajectory, alveolar boundaries, desired restorative position	Root angulation, interradicular spacing, and implant-site center can still be modified	Final ridge form may change during orthodontic treatment or healing
Periodontal stabilization → extraction/ridge preservation → orthodontic redistribution during ridge healing → implant reassessment	A non-maintainable tooth must be removed but adjacent root relationships remain modifiable	Extraction indication, preservation objective, adjacent-root plan, periodontal maintenance	Orthodontic correction can continue while the site is preserved for later reassessment	Preserved ridge dimensions and later implant requirements remain patient-specific
Periodontal stabilization → coordinated orthodontic redistribution and site augmentation → implant placement after spatial convergence	Both root geometry and ridge deficiency require correction	Compatibility of tooth movement with augmentation/site-development strategy	Implant position is deferred while both site and dentition evolve	Interaction between healing, movement, and final prosthetic demands
Orthodontic redistribution before extraction of a strategically retained tooth → extraction/site management → implant placement	Existing tooth position assists anchorage or space control before eventual replacement	Maintainability during orthodontics, extraction rationale, planned post-extraction site	Space and root relationships remain controllable until extraction	Biological deterioration during prolonged retention must be monitored
Selected implant-first or accelerated implant sequence	Root geometry is already acceptable and delaying replacement offers little additional spatial benefit	Adequate site anatomy, stable neighboring roots, defined restorative position, valid implant indication	Fewer orthodontic options remain around the fixed implant	Later discovery of a root, ridge, or restorative conflict is harder to correct

These alternatives should not be ranked generically. Their relevance depends on the particular reason space redistribution is being undertaken. If an implant site is already spatially mature and neighboring roots require no consequential modification, delaying fixture placement solely to preserve theoretical reversibility may offer little value. By contrast, if root positions are actively being altered to create the future implant corridor, fixing the implant before that geometry is resolved converts a correctable problem into a constraint around which later orthodontics must adapt. This distinction also protects against a common conceptual error: treating digital visualization as an intervention. Root setups, serial scans, and CBCT-derived anatomy can improve information, but none guarantees biological safety or predicts long-term implant success. They inform the decision concerning when sufficient uncertainty has been reduced; they do not themselves determine the answer.

Irreversibility and sequencing risk

Implant therapy introduces a qualitatively different commitment from orthodontic movement because the fixture establishes a fixed three-dimensional relationship to bone, neighboring roots, and the future restoration. The surrounding tissue environment is itself multidimensional. The peri-implant phenotype encompasses hard- and soft-tissue characteristics rather than a single descriptor of site adequacy [19]. Consequently, a space that appears prosthetically acceptable cannot be assumed to be biologically or spatially mature for implantation.

Some limitations can be mitigated after or during implant therapy. Soft-tissue augmentation performed in association with immediate implant placement can improve selected peri-implant soft-tissue outcomes in appropriate cases [20]. Yet mitigation should not be confused with reversibility. Grafting cannot make an osseointegrated implant orthodontically movable, and treatment performed after fixture placement may be forced to accommodate the existing implant axis and position.

Contemporary implant evidence reinforces the importance of conditional site selection. Bone dimensions and soft-tissue management, candidate selection for immediate treatment, and placement/loading protocols each influence clinical interpretation [21–23]. These sources do not establish one universally preferable timing pathway. Instead, they demonstrate that immediate, early, and delayed approaches have different indications and depend on site-specific biological and restorative conditions.

The same caution applies to ridge preservation and augmentation evidence. Clinical trials in this area use heterogeneous outcomes, including dimensional changes, augmentation requirements, radiographic measurements, clinician assessments, and patient-reported measures [24]. A favorable surrogate such as preservation of ridge width therefore cannot automatically be translated into long-term superiority of a complete rehabilitation sequence. For the present decision problem, ridge management is relevant because it may preserve or alter future options; it should not be interpreted as proof that one implant schedule is categorically best.

Comparative evidence likewise resists a simple timing hierarchy. Systematic reviews and randomized evidence comparing immediate placement, early placement, and ridge-preservation followed by delayed implantation show that more than one strategy can produce acceptable outcomes in appropriately selected sites, with differences depending on the endpoint examined and the procedural context [25–27]. These studies mostly concern selected single-tooth sites and should not be directly transplanted to patients with advanced periodontal attachment loss requiring simultaneous orthodontic reorganization. Their principal value here is to show that an evidence-based decision architecture must permit legitimate exceptions rather than impose an orthodontics-first rule.

Evidence from periodontally compromised extraction sites further supports preserving this conditionality. Ridge preservation in severely periodontally affected molar sites can be followed by implant treatment, and different wound-management approaches may produce broadly comparable healing and short-term implant outcomes in selected patients [28]. This demonstrates that a diseased extraction history does not eliminate later implant options, but it does not specify when orthodontic redistribution should occur relative to the site-management process.

Irreversibility should therefore be understood as progressive rather than binary. Some interventions narrow future options slightly; others close them substantially. Extraction removes the possibility of retaining or moving the tooth. Ridge-preservation or augmentation procedures alter the healing pathway but generally leave the definitive fixture position undecided. Implant osteotomy and fixture insertion commit the site much more strongly. Definitive prosthetic contours and occlusion introduce further dependencies. **Table 3** separates these commitments from the mitigation strategies available while the treatment pathway remains comparatively reversible.

Table 3. Irreversible commitments in combined orthodontic–implant rehabilitation and the options available before they are made

Treatment commitment	Why the commitment narrows future options	Risk if made before relevant spatial variables are resolved	Option-preserving action while still reversible	Residual uncertainty that cannot be eliminated
Extraction of a potentially maintainable tooth	Removes the possibility of periodontal retention and future orthodontic movement of that tooth	The implant plan may be built on a replacement decision that was not yet necessary	Reassess periodontal maintainability, strategic orthodontic value, patient burden, and long-term maintenance	Tooth prognosis remains probabilistic even after comprehensive assessment
Extraction-site management and ridge-preservation strategy	Directs healing and may influence later augmentation needs and site contours	Site development may be optimized for an implant position that later changes after root redistribution	Preserve the ridge while deferring exact fixture position when adjacent geometry remains unsettled	Final healed contour and remodeling remain individually variable
Orthodontic completion around the future implant site	Establishes root positions that may subsequently be treated as fixed	Premature declaration of completion may leave hidden root or alveolar conflicts	Verify root-level geometry and restorative requirements before ending corrective movement	Imaging and prediction cannot perfectly represent future biology

Implant osteotomy and fixture insertion	Creates a fixed osseointegrated position that cannot be moved orthodontically	Later space redistribution may be constrained by fixture proximity, axis, or restorative emergence	Delay definitive placement when consequential root/site relationships remain genuinely modifiable	Even careful site selection cannot eliminate future biological or prosthetic complications
Immediate or early provisional restoration	Begins shaping peri-implant soft tissues and transfers functional/restorative demands to the new site	A provisional trajectory may reinforce a suboptimal implant or emergence relationship	Maintain adjustability in provisional contour and loading where clinically appropriate	Tissue response and patient adaptation vary
Definitive implant restoration	Consolidates occlusal, emergence, contact, and cleansability relationships	Later orthodontic or restorative correction may require disproportionate compromise	Confirm periodontal stability, adjacent root position, occlusion, access, and maintenance before definitive completion	Long-term peri-implant and periodontal change remains possible despite favorable initial conditions

The most consequential sequence error is therefore not merely choosing an implant protocol that later proves imperfect. It is fixing an implant position while clinically relevant neighboring geometry remains both uncertain and realistically correctable. That risk is amplified when apparent crown space is accepted as a surrogate for root-level feasibility, when a thin alveolar boundary is treated as perfectly measured, or when ridge dimensions are interpreted independently of the final restorative axis.

These relationships are summarized in **Figure 1**. The figure does not represent a treatment algorithm; it depicts the spatial conditions that must converge around a candidate implant corridor and the point at which a modifiable orthodontic configuration becomes constrained by fixture placement.

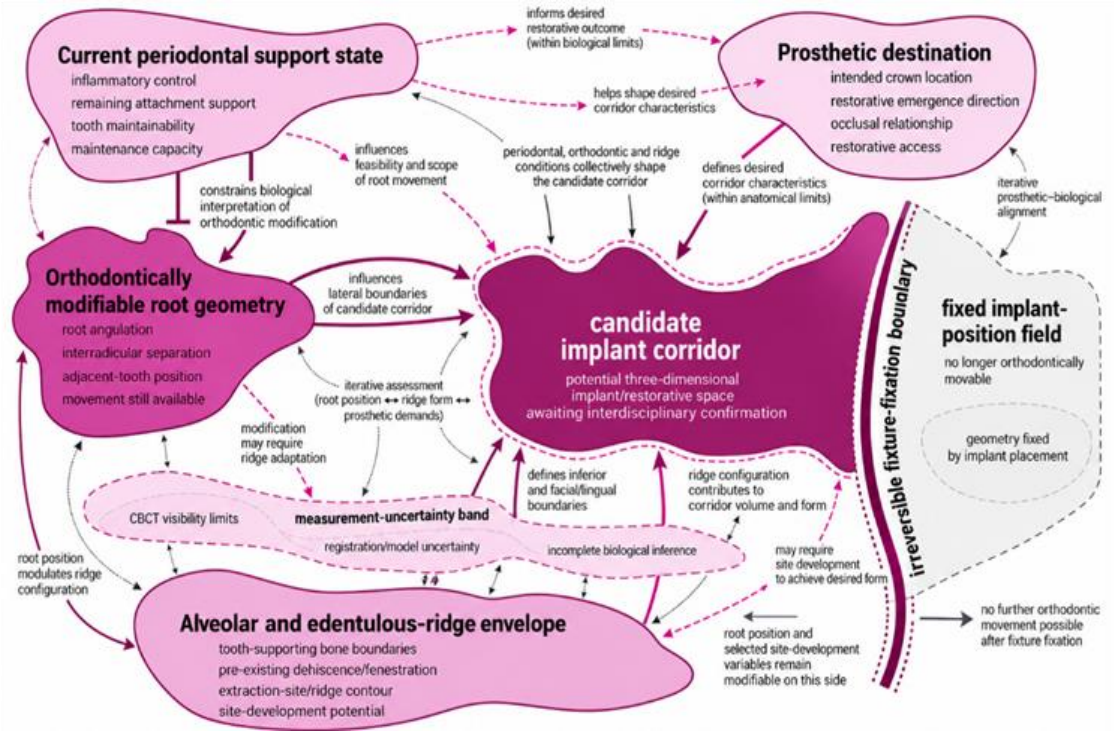

Figure 1. Root–ridge constraint landscape before irreversible implant fixation

By the end of this stage of the sequence, the clinically relevant question has changed. It is no longer simply whether orthodontic treatment or implant therapy is feasible in isolation. It is whether the remaining correctable biological and spatial uncertainties are sufficiently resolved that converting a modifiable site into a fixed implant position is defensible. That transition provides the basis for the interdisciplinary decision architecture developed in the next section.

An interdisciplinary sequencing decision architecture

The evidence assembled across periodontal, orthodontic, imaging, and implant domains does not yield a single clinically validated sequence applicable to every adult with periodontal attachment loss. It instead supports a more restrained organizing principle: the importance of resolving a treatment variable should depend partly on whether that variable remains correctable after the next intervention. Current periodontal status, maintenance capacity, root geometry, alveolar boundaries, ridge configuration, and the proposed restorative destination therefore need not carry identical weight at every treatment stage.

The first analytical task is to establish whether the dentition has reached a sufficiently controlled and maintainable periodontal state for complex rehabilitation to proceed. Stage IV guidance explicitly recognizes multidisciplinary rehabilitation as part of management, but does not define one universal ordering of orthodontic and implant procedures [4]. Long-term supportive-care evidence further shows why historical attachment loss cannot substitute for current state: periodontal stability and maintenance influence subsequent tooth retention, and severely affected teeth may remain serviceable for prolonged periods under appropriate care [11]. Similarly, decades of observation in susceptible patients demonstrate that prior periodontal destruction does not make tooth loss inevitable [12]. The first component of the proposed architecture is therefore state clarification, not extraction or implantation.

The second component concerns modifiable spatial uncertainty. Evidence from periodontal regeneration demonstrates that tooth movement need not invariably be postponed for a long fixed interval in appropriately selected patients [8]. Once movement is biologically defensible, the relevant question becomes whether root position, interradicular separation, or the center of the future implant space remains meaningfully adjustable. Expected-root-position methods show that root-level geometry around an implant site can be assessed directly rather than inferred from crowns alone [15]. Yet spatial assessment must retain an uncertainty margin because visualization of thin alveolar structures is method-dependent [18]. The architecture consequently does not demand perfect certainty. It requires recognition of uncertainties whose later correction would become disproportionately difficult after fixture placement.

A third component is commitment proportionality. Implant-related evidence shows that bone and soft-tissue conditions influence treatment stability and that selection criteria remain central to immediate or accelerated implant protocols [21]. At the same time, ridge-preservation and augmentation studies employ heterogeneous endpoints, limiting any attempt to translate one dimensional measurement into a comprehensive readiness threshold [24]. Even in periodontally compromised extraction sockets, ridge preservation can support subsequent implant treatment, demonstrating that site management may preserve future options without requiring immediate fixture commitment [28]. These findings justify distinguishing procedures that develop or preserve a future implant site from the later act of fixing the definitive implant position.

The proposed decision architecture therefore contains no numerical score and no automatic treatment recommendation. Its clinical logic is conditional: the greater the irreversibility of the next intervention, the stronger the justification should be for leaving a clinically important modifiable variable unresolved. Conversely, when neighboring roots are already appropriately positioned, periodontal conditions are stable, the restorative destination is well established, and further orthodontic movement offers little realistic benefit, preserving theoretical reversibility alone may not justify delaying implant therapy.

Figure 2 expresses this logic as a nonlinear decision-and-constraint landscape. It deliberately permits more than one route to implantation and includes routes in which ridge preservation, orthodontic movement, site development, or appropriately selected implant treatment proceed in different orders. The central distinction is between uncertainty that can safely remain under surveillance and uncertainty that would become clinically consequential after an irreversible commitment.

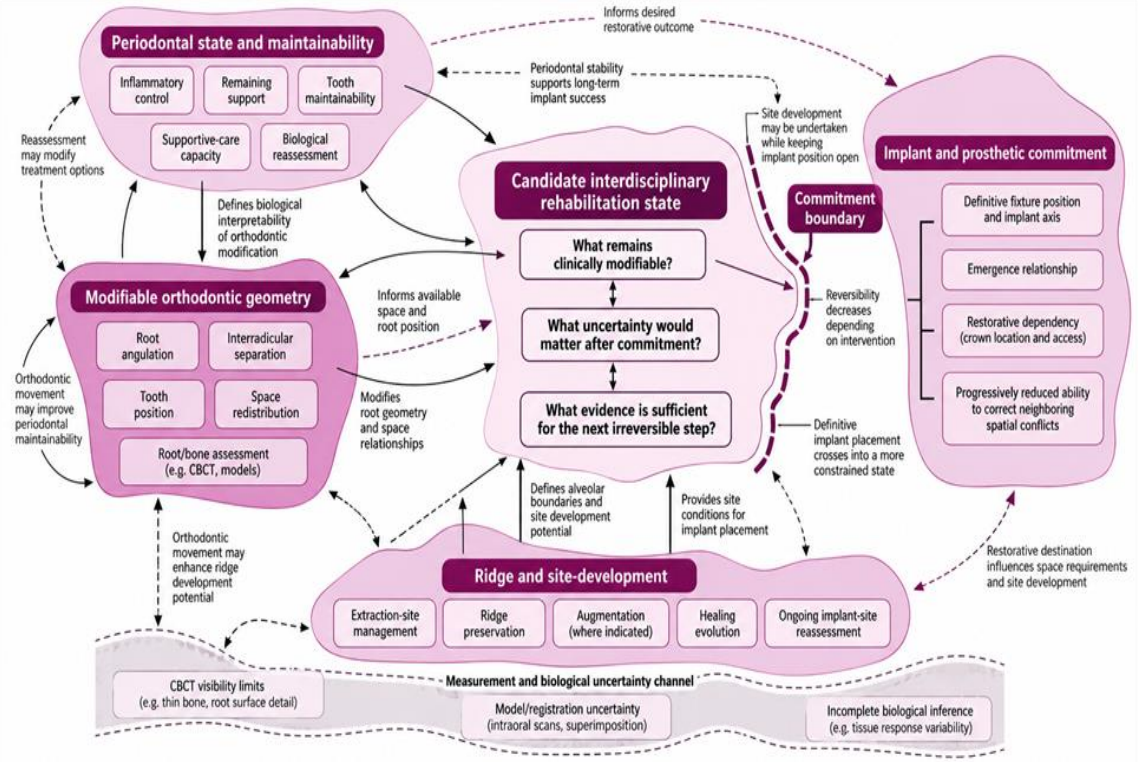

Figure 2. Conditional commitment landscape for sequencing modifiable dentoalveolar conditions and definitive implant placement

Clinical applications and decision uncertainty

The architecture is most useful when treatment options appear individually reasonable but differ in the amount of future correction they preserve. Consider first a patient with treated periodontitis, sustained maintenance, and an edentulous space bordered by migrated teeth. Evidence supports the feasibility of orthodontic treatment in selected treated periodontitis populations [5], and long-term studies show that favorable periodontal outcomes can remain stable when treatment is followed by supportive care [10]. Long-term tooth-retention evidence further cautions against treating historical attachment loss as sufficient reason to replace a maintainable tooth [12]. In such a patient, root redistribution may reasonably precede definitive implant positioning when the anticipated movement could materially change the implant corridor.

A second scenario arises when crown space appears adequate but root or alveolar relationships remain uncertain. Root and bone visualization can alter orthodontic treatment decisions [17], while CBCT-based interpretation of thin alveolar structures remains technically dependent [18]. The appropriate response is not automatically to obtain more imaging or delay treatment indefinitely. It is to identify whether the unresolved information could plausibly change fixture position, tooth movement, site development, or restorative design. If it could, preserving corrective options has greater value.

A different conclusion may follow when the future implant site is already spatially mature. Evidence concerning immediate implant selection indicates that accelerated treatment can be clinically defensible in carefully selected sites [22]. Comparative evidence also shows that immediate, early, and staged approaches may each produce acceptable outcomes under suitable conditions [25]. Randomized comparison of early placement with ridge preservation followed by delayed placement similarly demonstrates that different pathways can reach broadly comparable patient- and clinician-relevant outcomes despite procedural differences [27]. The proposed architecture must therefore allow implant-first or accelerated pathways when orthodontic modification would not materially improve the definitive site.

The remaining uncertainty is that no trial represented in this evidence base randomizes adults with periodontal attachment loss to complete multidisciplinary sequences defined by root redistribution, ridge preservation, and implant timing. Evidence is instead distributed across periodontal therapy, orthodontic movement, imaging, ridge management, and implant protocols. Even the recent clinical evidence from periodontally compromised extraction sockets supports the feasibility of ridge preservation rather than a specific orthodontic–implant

chronology [28]. The architecture should accordingly be regarded as a testable synthesis whose validity depends on future comparative and prospective evaluation.

Clinical application should therefore remain transparent about the distinction between evidence and inference. Evidence can establish that selected treated periodontal patients may undergo orthodontics, that root-level information can affect planning, that implant protocols have selection-dependent outcomes, and that ridge-management strategies can preserve treatment possibilities. The inference is that these findings can be organized according to modifiability and irreversible commitment. That inference is defensible, but it is not yet a validated clinical algorithm.

Conclusion

Sequencing orthodontic space redistribution and implant placement in adults with periodontal attachment loss cannot be reduced to a fixed waiting period or a universal orthodontics-first or implant-first rule. The central problem is the relationship between present biological stability, modifiable root and space geometry, evolving ridge conditions, measurement uncertainty, and the consequences of fixing an implant position.

When clinically important root, interradicular, alveolar, or restorative relationships remain both uncertain and realistically correctable, preserving the ability to modify them before definitive implant fixation is a defensible principle. When those relationships are already sufficiently resolved and an implant indication is otherwise sound, earlier placement may also be reasonable. The proposed architecture therefore treats sequencing as a conditional management of option preservation and commitment rather than a hierarchy of procedures. Its value now requires prospective testing against real multidisciplinary treatment decisions and long-term patient-centered outcomes.

Acknowledgments: None

Conflict of Interest: None

Financial Support: None

Ethics Statement: None

References

1. Tonetti MS, Greenwell H, Kornman KS. Staging and grading of periodontitis: Framework and proposal of a new classification and case definition. J Periodontol. 2018;89(Suppl 1). doi:10.1002/JPER.18-0006
2. Papapanou PN, Sanz M, Buduneli N, Dietrich T, Feres M, Fine DH, et al. Periodontitis: Consensus report of workgroup 2 of the 2017 World Workshop on the Classification of Periodontal and Peri-Implant Diseases and Conditions. J Clin Periodontol. 2018;45(Suppl 20). doi:10.1111/jcpe.12946
3. Sanz M, Herrera D, Kebschull M, Chapple I, Jepsen S, Berglundh T, et al. Treatment of stage I-III periodontitis-The EFP S3 level clinical practice guideline. J Clin Periodontol. 2020;47(Suppl 22):4-60. doi:10.1111/jcpe.13290
4. Herrera D, Sanz M, Kebschull M, Jepsen S, Sculean A, Berglundh T, et al. Treatment of stage IV periodontitis: The EFP S3 level clinical practice guideline. J Clin Periodontol. 2022;49(Suppl 24):4-71. doi:10.1111/jcpe.13639
5. Martin C, Celis B, Ambrosio N, Bollain J, Antonoglou GN, Figuero E. Effect of orthodontic therapy in periodontitis and non-periodontitis patients: A systematic review with meta-analysis. J Clin Periodontol. 2022;49(Suppl 24):72-101. doi:10.1111/jcpe.13487
6. Kloukos D, Roccuzzo A, Stähli A, Sculean A, Katsaros C, Salvi GE. Effect of combined periodontal and orthodontic treatment of tilted molars and of teeth with intra-bony and furcation defects in stage-IV periodontitis patients: A systematic review. J Clin Periodontol. 2022;49(Suppl 24):121-48. doi:10.1111/jcpe.13509
7. Erbe C, Heger S, Kasaj A, Berres M, Wehrbein H. Orthodontic treatment in periodontally compromised patients: A systematic review. Clin Oral Investig. 2023;27(1):79-89. doi:10.1007/s00784-022-04822-1
8. Jepsen K, Tietmann C, Kutschera E, Wüllenweber P, Jäger A, Cardaropoli D, et al. The effect of timing of orthodontic therapy on the outcomes of regenerative periodontal surgery in patients with stage IV periodontitis: A multicenter randomized trial. J Clin Periodontol. 2021;48(10):1282-92. doi:10.1111/jcpe.13528
9. Tietmann C, Bröseler F, Axelrad T, Jepsen K, Jepsen S. Regenerative periodontal surgery and orthodontic tooth movement in stage IV periodontitis: A retrospective practice-based cohort study. J Clin Periodontol. 2021;48(5):668-78. doi:10.1111/jcpe.13442

10. Tietmann C, Jepsen S, Heibrok H, Wenzel S, Jepsen K. Long-term stability of regenerative periodontal surgery and orthodontic tooth movement in stage IV periodontitis: 10-year data of a retrospective study. J Periodontol. 2023;94(10):1176-86. doi:10.1002/JPER.23-0081
11. Rattu V, Raindi D, Antonoglou G, Nibali L. Prevalence of stable and successfully treated periodontitis subjects and incidence of subsequent tooth loss within supportive periodontal care: A systematic review with meta-analyses. J Clin Periodontol. 2023;50(10):1371-89. doi:10.1111/jcpe.13835
12. Agudio G, Buti J, Bonaccini D, Pini Prato G, Cortellini P. Longevity of teeth in patients susceptible to periodontitis: Clinical outcomes and risk factors associated with tooth loss after active therapy and 30 years of supportive periodontal care. J Clin Periodontol. 2023;50(4):520-32. doi:10.1111/jcpe.13770
13. Dalaie K, Hajimiresmail YS, Safi Y, Akbarzadeh Baghban A, Behnaz M, Talebi Rafsanjan K. Correlation of alveolar bone thickness and central incisor inclination in skeletal Class I and II malocclusions with different vertical skeletal patterns: A CBCT study. Am J Orthod Dentofacial Orthop. 2023;164(4):537-44. doi:10.1016/j.ajodo.2023.02.021
14. Han S, Fan X, Wang S, Du H, Liu K, Ji M, et al. Dehiscence and fenestration of skeletal Class III malocclusions with different vertical growth patterns in the anterior region: A cone-beam computed tomography study. Am J Orthod Dentofacial Orthop. 2024;165(4):423-33. doi:10.1016/j.ajodo.2023.10.016
15. Pi S, Geng J, Bajestan M, Oberoi S, Lee RJ. Accuracy and reliability of the expected root position setup to evaluate root proximity of an edentulous site. Am J Orthod Dentofacial Orthop. 2022;162(5):753-62. doi:10.1016/j.ajodo.2022.05.019
16. Hu X, Zhao Y, Yang C. Evaluation of root position during orthodontic treatment via multiple intraoral scans with automated registration technology. Am J Orthod Dentofacial Orthop. 2023;164(2):285-92. doi:10.1016/j.ajodo.2023.04.012
17. Tüfekçi E, Carrico CK, Gordon CB, Lindauer SJ. Does crown, root, and bone visualization in a clear aligner virtual setup impact treatment decisions? Am J Orthod Dentofacial Orthop. 2024;165(6):671-79. doi:10.1016/j.ajodo.2024.01.014
18. Lennholm C, Andreasen H, Westerlund A, Lund H. Visibility of alveolar bone thicknesses on CBCT images-a study on minimum bone requirements using various reconstruction techniques, viewing modes, and resolutions. Clin Oral Investig. 2024;28(12):641. doi:10.1007/s00784-024-06034-1
19. Avila-Ortiz G, Gonzalez-Martin O, Couso-Queiruga E, Wang HL. The peri-implant phenotype. J Periodontol. 2020;91(3):283-8. doi:10.1002/JPER.19-0566
20. Seyssens L, De Lat L, Cosyn J. Immediate implant placement with or without connective tissue graft: A systematic review and meta-analysis. J Clin Periodontol. 2021;48(2):284-301. doi:10.1111/jcpe.13397
21. Jensen SS, Aghaloo T, Jung RE, Bertl K, Buser D, Chappuis V, et al. Group 1 ITI consensus report: The role of bone dimensions and soft tissue augmentation procedures on the stability of clinical, radiographic, and patient-reported outcomes of implant treatment. Clin Oral Implants Res. 2023;34(Suppl 26):43-9. doi:10.1111/clr.14154
22. Hamilton A, Gonzaga L, Amorim K, Wittneben JG, Martig L, Morton D, et al. Selection criteria for immediate implant placement and immediate loading for single tooth replacement in the maxillary esthetic zone: A systematic review and meta-analysis. Clin Oral Implants Res. 2023;34(Suppl 26):304-48. doi:10.1111/clr.14109
23. Morton D, Wismeijer D, Chen S, Hamilton A, Wittneben JG, Casentini P, et al. Group 5 ITI consensus report: Implant placement and loading protocols. Clin Oral Implants Res. 2023;34(Suppl 26):349-56. doi:10.1111/clr.14137
24. Shi JY, Montero E, Wu XY, Palombo D, Wei SM, Sanz-Sánchez I. Bone preservation or augmentation simultaneous with or prior to dental implant placement: A systematic review of outcomes and outcome measures used in clinical trials in the last 10 years. J Clin Periodontol. 2023;50(Suppl 25):67-82. doi:10.1111/jcpe.13626
25. Ickroth A, Seyssens L, Christiaens V, Pitman J, Cosyn J. Immediate versus early implant placement for single tooth replacement in the aesthetic area: A systematic review and meta-analysis. Clin Oral Implants Res. 2024;35(6):585-97. doi:10.1111/clr.14261
26. Atieh MA, Shah M, Hakam A, AlAli F, Aboushakra I, Alsabeeha NHM. Alveolar ridge preservation versus early implant placement in single non-molar sites: A systematic review and

meta-analysis. Clin Oral Implants Res. 2024;35(9):1055-71. doi:10.1111/clr.14314

27. Thoma D, Gil A, de Bruyckere T, Jung RE, Fukuba S, Ickroth A, et al. Early implant placement versus ridge preservation and delayed implant placement: Analysis of profilometric, clinician- and patient-reported outcomes from a two-centre RCT. Clin Oral Implants Res. 2024;35(11):1382-93. doi:10.1111/clr.14325
28. Wei Y, Tao A, Hu W, Zhao L, Xu T, Liu Y. Ridge preservation in extraction sockets of periodontally compromised molars with and without primary wound closure: Histological and 1-year implant outcomes of a clinical trial. Clin Oral Implants Res. 2025;36(9):1106-14. doi:10.1111/clr.14459