

## Review Article

**Histological and Histomorphometric Evaluation of Sinus Floor Augmentation with Calcium Phosphate Materials: A Systematic Review****Zygimantas Petronis<sup>1\*</sup>, Jonas Zigmantavicius<sup>1</sup>, Gintaras Januzis<sup>1</sup>**<sup>1</sup>Department of Maxillofacial Surgery, Lithuanian University of Health Sciences, Kaunas, Lithuania.\*E-mail ✉ [petronis.zygimantas@gmail.com](mailto:petronis.zygimantas@gmail.com)

Received: 19 December 2023; Revised: 27 February 2024; Accepted: 03 March 2024

**ABSTRACT**

Tooth loss in the maxillary arch leads to gradual bone resorption, and the maxillary sinus expansion can complicate the process of replacing natural teeth with dental implants. This study aimed to evaluate and compare the effectiveness of alloplastic grafts, specifically calcium phosphate ceramics— $\beta$ -tricalcium phosphate ( $\beta$ -TCP) and biphasic calcium phosphate (BCP)—in preserving bone volume after maxillary sinus augmentation. The intervention consisted of a two-stage sinus floor elevation procedure using  $\beta$ -TCP or BCP as bone substitutes. The comparison group included different bone grafting materials such as autografts, allografts, xenografts, or combinations of these substances. A total of 8 studies met the inclusion criteria for the systematic review, including six randomized clinical trials and two cohort studies. Of these, 5 studies provided histological analysis of new bone formation. Sinus sites treated with  $\beta$ -TCP showed new bone formation volumes ranging from  $26.92\% \pm 7.26\%$  to  $47.6\% \pm 9.9\%$ , with the remaining graft volume ranging from  $30.39\% \pm 10.29\%$  to  $32.25\% \pm 8.48\%$ . For sites augmented with BCP, new bone volume ranged from  $23.0\% \pm 8.80\%$  to  $43.4\% \pm 6.1\%$ , and the remaining graft volume was between  $16.4\% \pm 11.4\%$  to  $32.9\% \pm 15.6\%$ . The findings suggest that BCP and  $\beta$ -TCP may yield favorable outcomes in sinus floor elevation procedures, with alloplastic grafts ensuring adequate bone formation and maintaining residual graft particle volume better than other graft materials.

**Keywords:** Histomorphometric analysis, Calcium phosphate, Sinus lift elevation, Histologic analysis**How to Cite This Article:** Petronis Z, Zigmantavicius J, Januzis G. Histological and Histomorphometric Evaluation of Sinus Floor Augmentation with Calcium Phosphate Materials: A Systematic Review. *Int J Dent Res Allied Sci.* 2024;4(1):7-15.**Introduction**

Loss of teeth in the upper jaw causes progressive bone resorption, and the enlargement of the maxillary sinus cavities can substantially complicate the process of replacing natural teeth with dental implants [1]. The sinus floor elevation procedure has become a widely used approach before placing implants in the posterior maxilla [2]. In 1976, Tatum introduced the first sinus lift surgery, modifying the Caldwell-Luc technique by creating a lateral bony window to access and elevate the maxillary sinus membrane, known as the Schneiderian membrane [3].

Various bone graft materials are commonly utilized to promote bone formation in the maxillary sinuses. In

1989, the criteria for an ideal graft were established, which included non-toxicity, non-antigenicity, non-carcinogenicity, strength, resilience, ease of fabrication, tissue attachment promotion, infection resistance, availability, and cost-effectiveness [4].

Bone graft materials in dentistry are generally classified into four categories: autografts, allografts, xenografts, and photogenic materials [5].

Autografts are considered the gold standard due to their absence of immunogenicity and histocompatibility issues, offering the highest level of biological safety. Cancellous autografts contain osteoblasts and progenitor cells, which are essential for osteogenesis [5]. To enhance bone remodeling and healing, a combination of cancellous and cortical bone is

recommended [6]. When autografts are not suitable, allografts provide a good alternative, exhibiting strong histocompatibility [5]. Xenografts, however, come with challenges such as inconsistent resorption rates, absence of viable cells, and biological components, and require extensive processing to retain osteoinductive cells [7]. Phytogenic materials have been shown to have osteoinductive properties, enhance alkaline phosphatase activity, and aid in bone calcification and remodeling [5]. Additionally, synthetic materials that primarily support osteointegration and osteoconduction properties are also widely used in the market today [8]. These include calcium phosphate ceramics, such as hydroxyapatite (HA), beta-tricalcium phosphate ( $\beta$ -TCP), biphasic calcium phosphate (BCP), bioglass, and others [9]. While  $\beta$ -TCP offers good osteoconductive properties, radiopacity for tracking healing, excellent resorbability, and low immunogenicity, it falls short in mechanical strength, especially in terms of compressive strength. BCP, on the other hand, not only possesses osteoinductive potential but also has comparatively better mechanical strength than  $\beta$ -TCP [5]. Animal studies have shown that BCP ceramics achieve tissue integration similar to  $\beta$ -TCP [10]. Due to differing views in the literature, this study seeks to assess and compare the performance of  $\beta$ -TCP and BCP alloplastic grafts in maintaining bone volume after maxillary sinus elevation.

## Materials and Methods

A systematic review of relevant literature was carried out between April 3, 2017, and April 3, 2022, following the PRISMA guidelines. The review was independently conducted by all authors across several electronic databases, including PubMed Medline, Science Direct, Wiley Online Library, and The Cochrane Library. The search was performed using the following query: ( $\beta$ -TCP OR beta-tricalcium phosphate OR biphasic calcium phosphate) AND sinus AND (lift OR augmentation) AND (histomorphometric OR histomorphometry).

The review protocol was registered prospectively in the PROSPERO database, with the registration number CRD42022316448. The interventions involved in this review included a two-stage sinus floor elevation procedure using  $\beta$ -TCP or BCP as bone substitutes. Comparison groups consisted of other treatments using autografts, allografts, xenografts, alloplastic materials, or a combination of these substances.

Studies included in the review involved patients who underwent maxillary sinus augmentation with BCP or  $\beta$ -TCP, where histomorphometric analysis was used to evaluate the percentage of newly formed bone and the

residual volume of bone substitute from bone biopsies taken during implantation.

This systematic review focused on clinical studies involving humans published within the past five years, written in English, and reporting histomorphometric evaluation of native bone and changes in bone grafts following maxillary sinus lift procedures. Excluded from the review were meta-analyses, letters to the editor, narrative and systematic reviews, animal studies, case series or case reports, in vitro studies, and studies with non-comparable results.

The PICO criteria for this review were established as follows:

- Patients: Those needing lateral maxillary sinus floor augmentation.
- Intervention: Open sinus floor elevation procedure.
- Comparison: Two-stage sinus floor elevation using various graft materials, including BCP,  $\beta$ -TCP, autograft, allograft, xenograft, alloplastic materials, or their combinations.
- Outcome: Histological and histomorphometric assessment of new bone formation and residual graft particles, with a focus on BCP and  $\beta$ -TCP.

The review process began by examining titles and abstracts based on the selection criteria, followed by a thorough review of full-text articles. Any discrepancies between reviewers regarding study inclusion were resolved through discussion until an agreement was reached.

The quality of the studies included in the review was assessed using specific tools. For randomized controlled trials, the RoB 2 tool, a revised version of the Cochrane risk of bias tool, was utilized [11]. For observational studies, the ROBINS-I tool was employed to evaluate the risk of bias in non-randomized intervention studies [12].

Key information such as publication date, number of augmented sinuses or patients, graft materials used, time until histologic and histomorphometric evaluation, as well as the main findings and outcomes, were extracted and independently compiled from the selected articles.

## Results and Discussion

### Study selection

The literature search initially identified 654 publications. After applying the pre-defined eligibility criteria, 184 articles remained for further screening. Following the exclusion of articles with irrelevant titles or content, 21 articles were selected for full-text evaluation. Ultimately, 8 articles met all inclusion

criteria and were included in the systematic review (Figure 1).

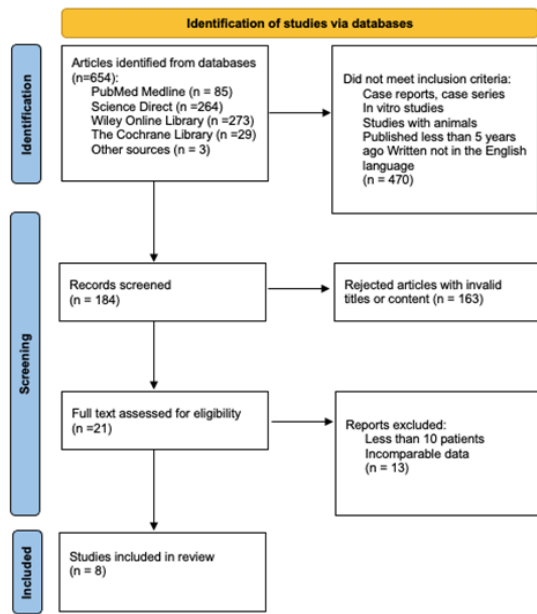


Figure 1. PRISMA flow diagram.

### Studies design and characteristics

A total of eight studies were included in this systematic review: six randomized clinical trials [13-18] and two cohort studies [19, 20]. All of these studies investigated new bone formation following lateral sinus augmentation using alloplastic grafts. Three studies specifically evaluated the effects of  $\beta$ -TCP alone [16, 18, 20], while five clinical trials assessed the impact of BCP (a combination of  $\beta$ -TCP and hydroxyapatite) [13-15, 18, 19]. Additionally, the review includes studies that explored the effects of supplementary substances such as PRP, PRF [16, 17], and enamel matrix proteins (EMD) [15] on bone formation following sinus augmentation with alloplastic grafts. Details of the study designs and characteristics are presented in Table 1.

Table 1. Studies design and characteristics.

No.	Reference	Study design	Patients (augmented sinuses)	Time until histologic and histomorphometric evaluation (months)
1	Sokolowski <i>et al.</i> [13]	RCT	20 (20)	3, 6
2	Oh <i>et al.</i> [14]	RCT	56 (60)	6
3	Nery <i>et al.</i> [15]	RCT	10 (20)	6
4	Cömert Kılıç <i>et al.</i> [16]	RCT	26 (26)	6

5	Pereira <i>et al.</i> [20]	CS	20 (33)	6
6	Cinar <i>et al.</i> [17]	RCT	20 (20)	6
7	Kraus <i>et al.</i> [18]	RCT	51 (51)	6
8	Kolerman <i>et al.</i> [19]	CS	13 (26)	9

RCT: randomized clinical trial, and CS: cohort study

### Quality assessment

The risk of bias assessment using the RoB 2 tool revealed that 4 out of the 6 randomized studies were classified as having a low risk of bias, while 2 studies raised some concerns [13-18]. The findings of the risk of bias evaluation for the randomized studies are illustrated in Figure 2.

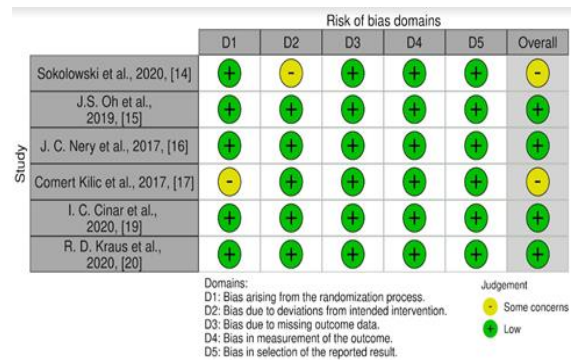


Figure 2. Risk of bias assessment using RoB 2 tool.

The evaluation of bias risk in the included non-randomized studies using the ROBINS-I tool is presented in Figure 3. Both studies were identified as having a moderate risk of bias [19, 20].

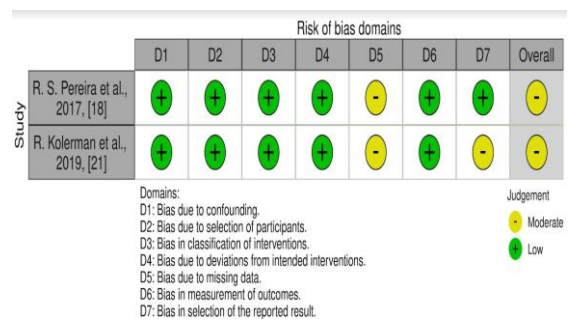


Figure 3. Risk of bias assessment using ROBINS-I tool.

### Histology

5 studies included in the review provided histological insights into new bone formation [14-17, 19]. The newly formed bone was closely attached to the partially resorbed graft particles, though a clear separation was seen between the native bone and grafted areas. The new bone tissue consisted of lamellar and woven bone with osteocytes in their lacunae [14-17]. Osteoblasts were observed near the edges of the newly formed bone

[16]. Inflammatory cells, including lymphocytes, macrophages, and multinucleated giant cells, were noted in a few studies, but there were no signs of acute inflammation [15-17, 19]. The clinical trial by Cömert Kılıç *et al.* [16] showed adequate angiogenesis around the new bone, with a denser capillary network present in areas grafted with  $\beta$ -TCP and P-PRP, compared to  $\beta$ -TCP alone or mixed with PRF. Additionally, this

study reported a lower density of osteoprogenitor cells and a higher density of inflammatory cells in the  $\beta$ -TCP with PRF group ( $P < 0.05$ ) [16].

#### Histomorphometry

Bone biopsy samples were collected 6 to 9 months following the sinus lift procedure [13-20]. The findings are summarized in **Table 2**.

**Table 2.** Studies results.

Reference	Interventions	Treatment group	Outcomes		
			Mean ( $\pm$ SD) percentage (%) new bone formed	P-value*	Mean ( $\pm$ SD) percentage (%) residual bone graft
Sokolowski <i>et al.</i> [13]	HA or BCP (HA/ $\beta$ -TCP 20:80)	HA	From 14.0 ( $\pm$ 16.9) to 16.4 ( $\pm$ 7.31)	$P < 0.011$	From 36.4 ( $\pm$ 15.1) to 40.0 ( $\pm$ 11.4)
		BCP	From 23.0 ( $\pm$ 8.80) to 34.0 ( $\pm$ 16.9)		From 16.4 ( $\pm$ 11.4) to 32.9 ( $\pm$ 15.6)
Oh [14]	BCP (HA/ $\beta$ -TCP 60:40) or deproteinized bovine bone mineral	BCP	28.84 ( $\pm$ 7.94)	$P = 0.286$	-
		Deproteinized bovine bone mineral	25.13 ( $\pm$ 9.56)		-
Nery <i>et al.</i> [15]	BCP mixed with EMD (BC + EMD) or BCP (HA/ $\beta$ -TCP 60:40)	BCP + EMD	Mean bone area 43.0 ( $\pm$ 9.0)	$P = 0.94$	-
		BCP	Mean bone area 43.4 ( $\pm$ 6.1)		-
Comert Kilic <i>et al.</i> [16]	P-PRP or PRF mixed $\beta$ -TCP	$\beta$ -TCP	33.40 ( $\pm$ 10.43)	$P > 0.05$	30.39 ( $\pm$ 10.29)
		P-PRP-mixed $\beta$ -TCP	34.83 ( $\pm$ 10.12)		28.98 ( $\pm$ 7.94)
		PRF mixed $\beta$ -TCP	32.03 ( $\pm$ 6.34)		32.66 ( $\pm$ 7.46)
Pereira <i>et al.</i> [20]	$\beta$ -TCP or $\beta$ -TCP + autogenous bone graft/ autogenous bone grafts alone	$\beta$ -TCP	From 44.8 ( $\pm$ 22.1) to 47.6 ( $\pm$ 9.9)	$P = 0.03$	-
		$\beta$ -TCP mixed autogenous bone graft	From 32.5 ( $\pm$ 13.7) to 35.0 ( $\pm$ 15.8)		-
		autogenous bone graft	From 31.0 ( $\pm$ 13.0) to 46.1 ( $\pm$ 16.3)		-
Cinar <i>et al.</i> [17]	$\beta$ -TCP/ MPM (comprised of $\beta$ -TCP+PRF)	$\beta$ -TCP	26.92 ( $\pm$ 7.26)	$P = 0.003$	32.25 ( $\pm$ 8.48)
		$\beta$ -TCP mixed PRF	35.40 ( $\pm$ 9.09)		23.13 ( $\pm$ 6.16)
Kraus <i>et al.</i> [18]	BCP (HA/TCP 10:90) or DBBM	BCP	35.9	$P > 0.05$	25.3
		DBBM	35.4		45.9
Kolerman <i>et al.</i> [19]	BCP (HA/ $\beta$ -TCP 60:40) or freeze-dried bone allografts	BCP	From 23.5 ( $\pm$ 9.9) to 30.0 ( $\pm$ 11.0)	$P < 0.01$	From 21.9 ( $\pm$ 9.9) to 27.7 ( $\pm$ 6.6)
		Freeze-dried bone allograft	From 27.7 ( $\pm$ 11.2) to 31.0 ( $\pm$ 9.5)		From 7.1 ( $\pm$ 6.6) to 9.1 ( $\pm$ 10.3)

HA: hydroxyapatite;  $\beta$ -TCP:  $\beta$ -tricalcium phosphate, BCP: biphasic calcium phosphate, EMD: enamel matrix proteins, P-PRP: platelet-rich plasma, PRF: platelet-rich fibrin, MPM: mineralized plasmatic matrix, and DBBM: deproteinized bovine bone mineral.

In studies examining sinuses augmented with  $\beta$ -TCP, the newly formed bone volume ranged from 26.92%  $\pm$

7.26% to 47.6%  $\pm$  9.9%, while the residual graft volume ranged from 30.39%  $\pm$  10.29% to 32.25%  $\pm$

8.48% [16, 17, 20]. For sites augmented with BCP (composed of  $\beta$ -TCP and hydroxyapatite), the new bone volume varied from  $23.0\% \pm 8.80\%$  to  $43.4\% \pm 6.1\%$ , and the remaining graft material volume ranged from  $16.4\% \pm 11.4\%$  to  $32.9\% \pm 15.6\%$  [13-15, 18, 19].

The addition of autologous platelet concentrates to  $\beta$ -TCP grafts produced inconsistent outcomes (**Table 3**). In a study by Cömert Kılıç *et al.* [16], which involved 26 patients, no significant differences were observed between  $\beta$ -TCP,  $\beta$ -TCP combined with P-PRP, and  $\beta$ -TCP combined with PRF regarding bone regeneration,

residual graft material, or soft tissue area ( $P > 0.05$ ). On the other hand, Cinar *et al.* [17] reported significant differences in the amount of new bone and remaining graft material between the  $\beta$ -TCP and  $\beta$ -TCP mixed with PRF groups ( $P < 0.05$ ), although no difference was noted in the soft tissue area between these 2 groups ( $P > 0.05$ ). Regarding the use of enamel matrix derivatives (EMD) with BCP, no significant effect was found on bone regeneration, residual grafting material, or soft tissue formation after six months of sinus augmentation ( $P > 0.05$ ) [15]

**Table 3.** Results in studies with additional biomaterials.

Reference	Patients (n)	Measurement	$\beta$ -TCP	$\beta$ -TCP + PRP	$\beta$ -TCP + PRF	$\beta$ -TCP + EMD	P
Nery <i>et al.</i> [15]	10	New bone (%)	$43.4\% \pm 6.1\%$	-	-	$43.0\% \pm 9.0\%$	0.94
		Other materials (%)	$35.3\% \pm 9.0\%$	-	-	$35.5\% \pm 8.2\%$	0.97
		Soft tissue (%)	$21.3\% \pm 6.8\%$	-	-	$21.5\% \pm 5.3\%$	0.96
Cömert Kılıç [16]	26	New bone (%)	$33.40\% \pm 10.43\%$	$34.83\% \pm 10.12\%$	$32.03\% \pm 6.34\%$	-	0.825
		Residual graft (%)	$30.39\% \pm 10.29\%$	$28.98\% \pm 7.94\%$	$32.66\% \pm 7.46\%$	-	0.686
		Soft tissue (%)	$36.21\% \pm 10.59\%$	$36.19\% \pm 13.94\%$	$35.31\% \pm 10.81\%$	-	0.985
Cinar <i>et al.</i> [17]	20	New bone (%)	$26.92\% \pm 7.26\%$	-	$35.40\% \pm 9.09\%$	-	<b>0.003</b>
		Residual graft (%)	$32.25\% \pm 8.48\%$	-	$23.13\% \pm 6.16\%$	-	<b>&lt; 0.001</b>
		Soft tissue (%)	$40.83\% \pm 8.86\%$	-	$41.48\% \pm 8.41\%$	-	0.817

Two studies evaluated maxillary sinus augmentation using BCP and deproteinized bovine bone minerals and compared their histomorphometric results [14, 18]. While both studies found a higher amount of new bone formation in the BCP group, the differences weren't statistically important ( $P > 0.05$ ) [14, 18]. However, Kraus *et al.* [18] reported a significantly lower amount of residual graft material and more non-mineralized tissue in the BCP group compared to the deproteinized bovine bone mineral group six months after the sinus lift ( $P < 0.001$ ).

In another study, BCP,  $\beta$ -TCP combined with autogenous bone graft, and autogenous bone graft alone were compared [20]. The  $\beta$ -TCP group showed a statistically significant higher level of new bone formation compared to the  $\beta$ -TCP with autogenous bone graft group ( $P = 0.03$ ) [20]. No other significant differences were noted in this study.

Kolerman *et al.* [19] also analyzed allograft and alloplastic materials in terms of new bone formation. While the new bone formation was similar in both the freeze-dried bone allograft and BCP groups, the BCP

group retained significantly more residual graft material ( $P < 0.01$ ).

Research by Sokolowski *et al.* [13] comparing HA and BCP found a statistically significant increase in new bone formation when BCP was used as the bone substitute for maxillary sinus augmentation ( $P < 0.011$ ). Furthermore, the residual BCP volume was significantly lower than HA after six months ( $P = 0.006$ ) [13].

This systematic review indicates that sinuses augmented with  $\beta$ -TCP exhibited a mean new bone volume ranging from  $26.92\% \pm 7.26\%$  to  $47.6\% \pm 9.9\%$ , with residual graft volumes ranging from  $30.39\% \pm 10.29\%$  to  $32.25\% \pm 8.48\%$  [16, 17, 20]. Similarly, sites treated with BCP (containing both  $\beta$ -TCP and hydroxyapatite) showed an average new bone volume between  $23.0\% \pm 8.80\%$  and  $43.4\% \pm 6.1\%$ , while the remaining graft material ranged from  $16.4\% \pm 11.4\%$  to  $32.9\% \pm 15.6\%$  across the studies [13-15, 18, 19].

A randomized clinical trial examining the effect of xenograft on new bone formation 6-8 months after a sinus lift found that the formation of vital bone ranged



from  $18.77\% \pm 4.74\%$  to  $38.5\% \pm 17\%$ , with larger graft particles yielding more favorable outcomes [21, 22]. The remaining graft material in the study by Stacchi *et al.* [22] was reported to be  $22.3\% \pm 12\%$ . When compared to the results from calcium phosphate ceramics, xenograft exhibited a lower level of new bone formation and a greater degree of graft material resorption.

In a histomorphometric study conducted by Xavier SP [23], the proportion of remaining native bone and graft particles was assessed six months following sinus augmentation. The findings revealed that autogenous bone and frozen allograft bone contained 36.09% and 34.93% residual graft particles, with newly formed bone accounting for 8.27% and 8.26%, respectively [23].

In their systematic review, Pesce *et al.* [24] analyzed the volumetric changes of various biomaterials. Six months post-treatment, the xenograft exhibited a volumetric reduction of  $7.30\% \pm 15.49\%$ , while the alloplastic showed a contraction of  $27.82\% \pm 15.58\%$ , and the allograft had a decrease of  $30.23\% \pm 1.61\%$ . The combination of autogenous and alloplastic grafts showed a reduction of  $26.68\% \pm 11.03\%$ , with the autogenous graft experiencing the highest resorption at  $41.71\% \pm 12.63\%$ . It was noted that xenografts serve as effective space maintainers with a very slow rate of resorption [25, 26]. Alloplastic materials are also considered adequate for maintaining bone volume. Additionally, Stumbras *et al.* [27] observed that the greatest amount of new bone formation occurred in sinuses augmented with autologous bone.

Platelet concentrates have been shown to improve the osteoinductive properties of bone by promoting the formation of new bone. Wiltfang *et al.* [28] compared sinus augmentation with a mixture of  $\beta$ -TCP and PRP versus  $\beta$ -TCP alone, finding that the combination of  $\beta$ -TCP and PRP resulted in an average of 38% new bone formation, compared to 29% with  $\beta$ -TCP alone. In another study, Zhang *et al.* [29] evaluated the effects of PRF mixed with deproteinized bovine bone and deproteinized bovine bone alone in sinus augmentation. Six months after the procedure, the new bone formation was  $18.35\% \pm 5.62\%$  with PRF and deproteinized bovine bone, and  $12.95\% \pm 5.33\%$  with deproteinized bovine bone alone. The residual bone substitute in the deproteinized bovine bone group was  $28.54\% \pm 12.01\%$ , while in the PRF and deproteinized bovine bone group, it was  $19.16\% \pm 6.89\%$  [29]. These findings indicate that autologous platelet concentrates contribute to better bone formation. Despite varying results regarding the impact of platelet concentrates on new bone formation, there is consensus that the growth

factors released by platelets help reduce inflammation, lower the risk of complications, and enhance bone vascularization. Additionally, alternative plasma rich in growth factors (PRGF) can be used to promote bone regeneration, increase new bone formation, and support vascularization [30].

A study on sinus floor elevation by Kim *et al.* [31], comparing allograft and xenograft, revealed similar outcomes. The bovine bone evaluation showed 34.9% new bone, 19.8% residual graft, and 45.3% connective tissue. The allografts resulted in 40.3% new bone, 2.7% residual graft, and 57.0% connective tissue. In an in vivo study by Harel *et al.* [32], the effect of different  $\beta$ -TCP and HA ratios on osteoconductivity was explored. The 20:80 ratio led to more new bone formation than other ratios (80:20, 70:30, and 30:70). However, the 60:40 HA to  $\beta$ -TCP ratio produced the highest amount of new bone, with less connective tissue and fewer remaining graft particles after six months compared to the other ratios [33]. Further research into the impact of different proportions is recommended.

In research by Koch *et al.* [34], the impact of recombinant human growth and differentiation factor-5 (rhGDF-5) on  $\beta$ -TCP in supporting bone formation after sinus augmentation was examined. The findings indicated that bone regeneration was similar with and without rhGDF-5, showing no significant increase in newly formed bone.

The studies included in the review were diverse, consisting of six randomized clinical trials and 2 cohort studies. A limitation of these studies was the small sample sizes, with sinus augmentations ranging from 20 to 51, which affects the ability to make precise comparisons and weakens the reliability of the results. Although biphasic calcium phosphate and  $\beta$ -tricalcium phosphate have shown promising results, further clinical research that individually assesses and compares various grafting materials histomorphometrically is necessary to improve the understanding of their effectiveness in sinus floor augmentation.

## Conclusion

Biphasic calcium phosphate and  $\beta$ -tricalcium phosphate may yield positive results in sinus floor elevation procedures. Alloplasts appear to promote adequate new bone formation and maintain a stable amount of residual graft material compared to other types of grafts.

**Acknowledgments:** We thank the Lithuanian University of Health Sciences for their support.

**Conflict of Interest:** None

**Financial Support:** None

**Ethics Statement:** This research complies with the ethical standards of the Lithuanian University of Health Sciences.

## References

1. Tasoulis G, Yao SG, Fine JB. The maxillary sinus: challenges and treatments for implant placement. *Compend Contin Educ Dent*. 2011;32(1):10-9.
2. Bathla SC, Fry RR, Majumdar K. Maxillary sinus augmentation. *J Indian Soc Periodontol*. 2018;22(6):468-73. doi:10.4103/jisp.jisp\_236\_18
3. Tsai CF, Pan WL, Pan YP, Chan CP, Ju YR, Wang YM, et al. Comparison of 4 sinus augmentation techniques for implant placement with residual alveolar bone height  $\leq 3$  mm. *Medicine*. 2020;99(46):e23180. doi:10.1097/MD.00000000000023180
4. Wagner J. A clinical and histological case study using resorbable hydroxylapatite for the repair of osseous defects prior to endosseous implant. *J Oral Implantol*. 1989;15(3):485-509.
5. Zhao R, Yang R, Cooper PR, Khurshid Z, Shavandi A, Ratnayake J. Bone grafts and substitutes in dentistry: a review of current trends and developments. *Molecules*. 2021;26(10):3007. doi:10.3390/molecules26103007
6. Roberts TT, Rosenbaum AJ. Bone grafts, bone substitutes and orthobiologics: the bridge between basic science and clinical advancements in fracture healing. *Organogenesis*. 2012;8(4):114-24. doi:10.4161/org.23306
7. Haugen HJ, Lyngstadaas SP, Rossi F, Perale G. Bone grafts: which is the ideal biomaterial? *J Clin Periodontol*. 2019;46(S21):92-102. doi:10.1111/jcpe.13058
8. Moore WR, Graves SE, Bain GI. Synthetic bone graft substitutes. *ANZ J Surg*. 2001;71(6):354-61. doi:10.1046/j.1440-1622.2001.02128.x
9. Kolk A, Handschel J, Drescher W, Rothamel D, Kloss F, Blessmann M, et al. Current trends and future perspectives of bone substitute materials—from space holders to innovative biomaterials. *J Cranio-Maxillofac Surg*. 2012;40(8):706-18. doi:10.1016/j.jcms.2012.01.002
10. Kunert-Keil C, Scholz F, Gedrange T, Gredes T. Comparative study of biphasic calcium phosphate with beta-tricalcium phosphate in rat cranial defects—a molecular-biological and histological study. *Ann Anat-Anat Anz*. 2015;199(Suppl. 5):79-84. doi:10.1016/j.aanat.2013.12.001
11. Sterne JAC, Savović J, Page MJ, Elbers RG, Blencowe NS, Boutron I, et al. RoB 2: a revised tool for assessing risk of bias in randomised trials. *BMJ*. 2019;366:l4898.
12. Sterne JA, Hernán MA, Reeves BC, Savović J, Berkman ND, Viswanathan M, et al. ROBINS-I: a tool for assessing risk of bias in non-randomised studies of interventions. *BMJ*. 2016;355:i4919.
13. Sokolowski A, Sokolowski A, Schwarze U, Theisen K, Payer M, Lorenzoni M, et al. Phycogenic bone substitutes for sinus floor augmentation: histomorphometric comparison of hydroxyapatite and biphasic calcium phosphate in a randomised clinical pilot study. *Int J Oral Implantol (Berl)*. 2020;13(4):387-99.
14. Oh JS, Seo YS, Lee GJ, You JS, Kim SG. A comparative study with biphasic calcium phosphate to deproteinized bovine bone in maxillary sinus augmentation: a prospective randomized and controlled clinical trial. *Int J Oral Maxillofac Implants*. 2019;34(1):233-42. doi:10.11607/jomi.7116
15. Nery JC, Pereira LAVD, Guimarães GF, Scardueli CR, França FMG, Spin-Neto R, et al.  $\beta$ -TCP/HA with or without enamel matrix proteins for maxillary sinus floor augmentation: a histomorphometric analysis of human biopsies. *Int J Implant Dent*. 2017;3(1):18. doi:10.1186/s40729-017-0080-8
16. Cömert Kılıç S, Güngörmüş M, Parlak SN. Histologic and histomorphometric assessment of sinus-floor augmentation with beta-tricalcium phosphate alone or in combination with pure-platelet-rich plasma or platelet-rich fibrin: a randomized clinical trial. *Clin Implant Dent Relat Res*. 2017;19(5):959-67. doi:10.1111/cid.12522
17. Cinar IC, Gultekin BA, Saglanmak A, Yalcin S, Olgac V, Mijiritsky E. Histologic, histomorphometric, and clinical analysis of the effects of growth factors in a fibrin network used in maxillary sinus augmentation. *Int J Environ Res Public Health*. 2020;17(6):1918. doi:10.3390/ijerph17061918
18. Kraus RD, Stricker A, Thoma DS, Jung RE. Sinus floor elevation with biphasic calcium phosphate or deproteinized bovine bone mineral: clinical and histomorphometric outcomes of a randomized controlled clinical trial. *Int J Oral Maxillofac Implants*. 2020;35(5):1005-12. doi:10.11607/jomi.8211

19. Kolerman R, Nissan J, Rahmanov M, Calvo-Guirado JL, Green NT, Tal H. Sinus augmentation analysis of the gradient of graft consolidation: a split-mouth histomorphometric study. *Clin Oral Investig.* 2019;23(8):3397-406. doi:10.1007/s00784-018-2793-3
20. Pereira RS, Gorla LF, Boos FBJD, Okamoto R, Garcia Júnior IR, Hochuli-Vieira E. Use of autogenous bone and beta-tricalcium phosphate in maxillary sinus lifting: histomorphometric study and immunohistochemical assessment of RUNX2 and VEGF. *Int J Oral Maxillofac Surg.* 2017;46(4):503-10. doi:10.1016/j.ijom.2017.01.002
21. Testori T, Wallace SS, Trisi P, Capelli M, Zuffetti F, Del Fabbro M. Effect of xenograft (ABBM) particle size on vital bone formation following maxillary sinus augmentation: a multicenter, randomized, controlled, clinical histomorphometric trial. *Int J Periodontics Restorative Dent.* 2013;33(4):467-75. doi:10.11607/prd.1423
22. Stacchi C, Lombardi T, Oreglia F, Alberghini Maltoni A, Traini T. Histologic and histomorphometric comparison between sintered nanohydroxyapatite and anorganic bovine xenograft in maxillary sinus grafting: a split-mouth randomized controlled clinical trial. *Biomed Res Int.* 2017;2017(1):9489825. doi:10.1155/2017/9489825
23. Xavier SP, Dias RR, Sehn FP, Kahn A, Chaushu L, Chaushu G. Maxillary sinus grafting with autograft vs. fresh frozen allograft: a split-mouth histomorphometric study. *Clin Oral Implants Res.* 2015;26(9):1080-5. doi:10.1111/clr.12404
24. Pesce P, Menini M, Canullo L, Khijmatgar S, Modenese L, Gallifante G, et al. Radiographic and histomorphometric evaluation of biomaterials used for lateral sinus augmentation: a systematic review on the effect of residual bone height and vertical graft size on new bone formation and graft shrinkage. *J Clin Med.* 2021;10(21):4996. doi:10.3390/jcm10214996
25. Hallman M, Lundgren S, Sennerby L. Histologic analysis of clinical biopsies taken 6 months and 3 years after maxillary sinus floor augmentation with 80% bovine hydroxyapatite and 20% autogenous bone mixed with fibrin glue. *Clin Implant Dent Relat Res.* 2001;3(2):87-96. doi:10.1111/j.1708-8208.2001.tb00236.x
26. Mordenfeld A, Hallman M, Johansson CB, Albrektsson T. Histological and histomorphometrical analyses of biopsies harvested 11 years after maxillary sinus floor augmentation with deproteinized bovine and autogenous bone. *Clin Oral Implants Res.* 2010;21(9):961-70. doi:10.1111/j.1600-0501.2010.01939.x
27. Stumbras A, Krukis MM, Januzis G, Juodzbaly G. Regenerative bone potential after sinus floor elevation using various bone graft materials: a systematic review. *Quintessence Int.* 2019;50(7):548-58. doi:10.3290/j.qi.a42482
28. Wiltfang J, Schlegel KA, Schultze-Mosgau S, Nkenke E, Zimmermann R, Kessler P. Sinus floor augmentation with beta-tricalciumphosphate (beta-TCP): does platelet-rich plasma promote its osseous integration and degradation? *Clin Oral Implants Res.* 2003;14(2):213-8. doi:10.1034/j.1600-0501.2003.140212.x
29. Zhang Y, Tangl S, Huber CD, Lin Y, Qiu L, Rausch-Fan X. Effects of Choukroun's platelet-rich fibrin on bone regeneration in combination with deproteinized bovine bone mineral in maxillary sinus augmentation: a histological and histomorphometric study. *J Craniomaxillofac Surg.* 2012;40(4):321-8. doi:10.1016/j.jcms.2011.04.020
30. Stumbras A, Januzis G, Gervickas A, Kubilius R, Juodzbaly G. Randomized and controlled clinical trial of bone healing after alveolar ridge preservation using xenografts and allografts versus plasma rich in growth factors. *J Oral Implantol.* 2020;46(5):515-25. doi:10.1563/aaid-joi-d-19-00179
31. Kim HW, Lim KO, Lee WP, Seo YS, Shin HI, Choi SH, et al. Sinus floor augmentation using mixture of mineralized cortical bone and cancellous bone allografts: radiographic and histomorphometric evaluation. *J Dent Sci.* 2020;15(3):257-64.
32. Harel N, Moses O, Palti A, Ormianer Z. Long-term results of implants immediately placed into extraction sockets grafted with  $\beta$ -tricalcium phosphate: a retrospective study. *J Oral Maxillofac Surg.* 2013;71(2):e63-8. doi:10.1016/j.joms.2012.09.022
33. Uzeda MJ, de Brito Resende RF, Sartoretto SC, Alves ATNN, Granjeiro JM, Calasans-Maia MD. Randomized clinical trial for the biological evaluation of two nanostructured biphasic calcium phosphate biomaterials as a bone substitute. *Clin Implant Dent Relat Res.* 2017;19(5):802-11. doi:10.1111/cid.12516
34. Koch FP, Becker J, Terheyden H, Capsius B, Wagner W. A prospective, randomized pilot study



on the safety and efficacy of recombinant human growth and differentiation factor-5 coated onto  $\beta$ -tricalcium phosphate for sinus lift augmentation:

prospective, randomized clinical trial on rhGDF-5 for sinus lift augmentation. Clin Oral Implants Res. 2010;21(11):1301-8.