

Original Article

## A Systematic Review of the Implant Success Rate Following Immediate Implant Placement in Infected Sockets

Ignas Mickevičius<sup>1\*</sup>, Erika Astramskaitė<sup>1</sup>, Gintaras Janužis<sup>2</sup>

<sup>1</sup> Odontology, Medical Academy, Lithuanian University of Health Sciences, Kaunas, Lithuania.

<sup>2</sup> Department of Maxillofacial Surgery, Lithuanian University of Health Sciences, Kaunas, Lithuania.

\*E-mail ✉ [mrignasmickevicius@gmail.com](mailto:mrignasmickevicius@gmail.com)

Received: 04 March 2024; Revised: 26 May 2024; Accepted: 29 May 2024

### ABSTRACT

This systematic review aimed to assess the survival rate of immediate implants placed in sites with chronic periapical lesions, following different disinfection protocols. A comprehensive literature search was performed according to the PRISMA guidelines. Clinical trials published in English between 2012 and 2023 were considered. Eligible studies included randomized clinical trials (RCTs) and cohort human clinical trials that evaluated the survival rate of implants in infected sockets, with a control group and a minimum follow-up period of 3 months. In vitro studies, animal research, pilot studies, case reports, and case series were excluded. The Newcastle-Ottawa scale was used for cohort studies, while the Cochrane Risk of Bias assessment tool (version 2) was used for RCTs. Seven studies met the inclusion criteria: five cohort studies and two RCTs. Due to data heterogeneity, none of the studies were suitable for quantitative meta-analysis. A total of 259 patients and 663 implants were evaluated, with implant survival rates ranging from 94.4% to 100%. All studies used curettage as the primary debridement method in the test groups for infected sockets. No statistically important differences ( $P < 0.05$ ) were observed in implant survival when additional disinfection methods such as chlorhexidine rinsing or sequestrectomy using Er, Cr: YSGG laser were applied. The findings suggest that while various measures can increase the likelihood of implant integration, additional disinfection techniques are ineffective unless thorough curettage of the alveolus is performed.

**Keywords:** Decontamination, Infected sockets, Immediate implantation, Survival rate.

**How to Cite This Article:** Mickevičius I, Astramskaitė E, Janužis G. A Systematic Review of the Implant Success Rate Following Immediate Implant Placement in Infected Sockets. J Curr Res Oral Surg. 2024;4:20-31. <https://doi.org/10.51847/PcPJL1v1XF>

### Introduction

Brånemark's traditional protocol suggests that a dental implant must only be placed once the alveolar bone has completely healed [1]. Complete healing of extraction sockets can take up to 12 months [2]. Unfortunately, after a tooth is removed, the alveolar ridge often undergoes resorption, which can lead to a significant reduction in bone volume, limiting the potential for ideal implant placement and restoration outcomes [3]. To overcome this issue, the immediate implant

placement approach was developed to achieve better results [4].

In the last eleven years, immediate implant placement has gained substantial attention. This technique involves placing an implant in the same location as a compromised tooth on the day of extraction [5]. Key benefits of immediate implant placement include the ability to load the implant immediately, fewer surgical procedures, reduced alveolar bone resorption, and the potential to place the implant in a more favorable axial position [6]. When considering patient-centered benefits, including reduced morbidity, positive

psychological effects, and significantly shorter time to dental restoration, immediate implant placement becomes a favorable option [7]. Several clinical reports and animal studies have demonstrated that implants placed immediately in freshly extracted sockets often lead to satisfactory outcomes [8-10]. However, the success of immediate implantation may be compromised by an active infection at the extraction site, which could lead to the spread of infection to surrounding tissues, resulting in retrograde peri-implantitis or implant failure [11].

To prevent bacterial contamination and implant failure caused by bacterial strains, preventive antibiotics (PAs) are commonly prescribed [12, 13]. The American Heart Association (AHA) recommends the use of antibiotics before complex surgical procedures, including immediate implant placement. The AHA specifically suggests antibiotics like amoxicillin due to their higher absorption rates and prolonged serum levels [14]. As a result, the use of prophylactic antibiotics in dental implant surgeries remains a topic of debate [15]. The European Association for Osseointegration acknowledges that PAs may be beneficial in challenging cases, including immediate implant placement, although there are currently no established guidelines for their administration in these situations [16]. It is well-established that successful immediate implant placement requires thorough debridement and disinfection of infected sockets [17]. In 1995, Novaes Jr. and Novaes documented the first successful case of immediate implant placement in an infected socket. Their recommended approach includes careful removal and debridement of the socket (including excision of a thin layer of bone from the periapical lesion site), followed by extensive saline irrigation, guided bone regeneration, primary closure, and a regimen of systemic antibiotics [18].

The success of the procedure is largely contingent on the mechanical curettage of contaminated tissues [19]. Several decontamination methods and drug protocols have been reported for immediate implantation [20, 21]. Del Fabbro *et al.* [20] applied PRGF liquid to the implant body, promoting bioactivation of the implant surface. Garcés Villalá *et al.* [21] emphasized that the crucial factor to successful immediate implant placement lies in cleaning the sockets with sterile saline and 3% hydrogen peroxide to remove tissue debris from the alveolus which was vital for the protocol's success.

Understanding the disinfection of the socket before immediate implantation is crucial for achieving a favorable outcome [22]. Furthermore, data on healing dynamics and bone regeneration specific to each

protocol are necessary to compare different options and determine the most effective approach.

#### *Aim*

The objective was to assess the survival rate of immediate implants placed in sites with chronic periapical lesions following the application of various disinfection techniques.

#### **Materials and Methods**

The systematic review was carried out following the Preferred Reporting Items for Systematic Reviews and Meta-Analyses (PRISMA) guidelines. The protocol for this review was formally registered with PROSPERO, hosted by the University of York's Centre for Reviews and Dissemination. The study's registration number is CRD42023392878.

#### *Focus question*

The focus question for this research was developed using the participant, intervention, comparison, outcome (PICO) framework [23]. It aimed to assess the implant survival rate (O) following immediate implantation (I) in patients with periapical lesions in the socket (P) compared to those receiving immediate implantation in non-infected sockets (C).

#### *Inclusion and exclusion criteria*

##### *Inclusion Criteria*

- Studies published in English.
- Research conducted within the last 11 years.
- Cohort studies or randomized clinical trials (RCTs) assessing the survival rate of implants placed in infected sockets.
- A minimum follow-up period of 3 months.
- A clearly stated disinfection protocol.
- Participants in the control group must have a healthy periapical region where implants were placed.
- The test group must include patients who underwent immediate implantation in sites with periapical lesions.
- Studies report the implant survival rate.

##### *Exclusion Criteria*

- Participants with systemic conditions.
- Individuals with chronic illnesses.
- Studies involving incompatible medication or conditions.
- Smokers consume more than 10 cigarettes per day.
- Lack of follow-up data.

- Studies of in vitro, animal, pilot studies, case reports, and case series.

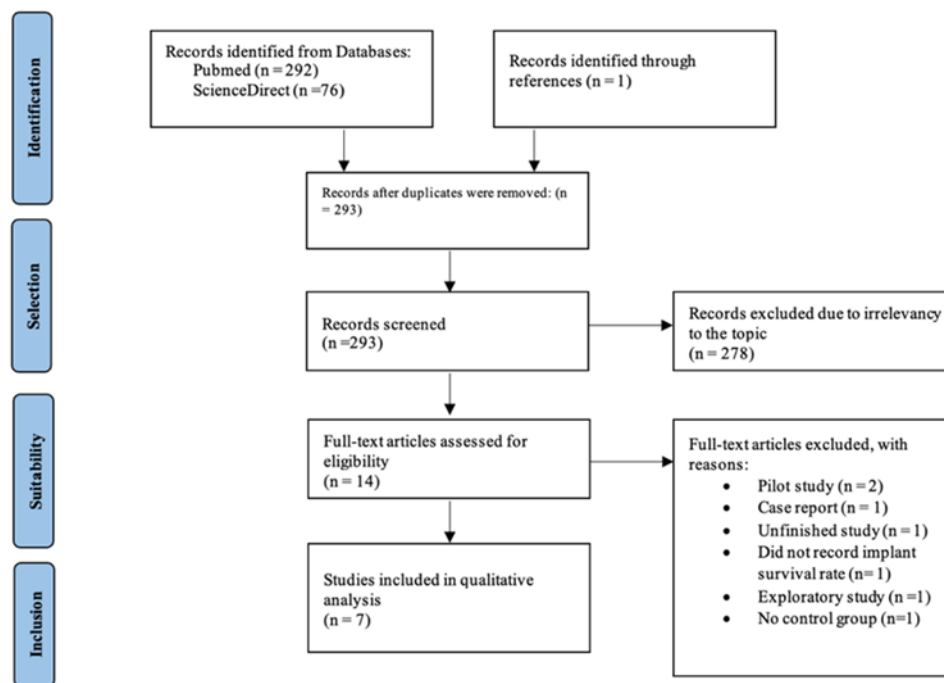
researchers reviewed the results and discussed any discrepancies to reach a consensus.

### Search strategy and study selection

A comprehensive literature search was carried out following PRISMA guidelines. Clinical trials published in English from 2012 to 2023 were included in the review. Each author independently performed electronic searches in the Medline (PubMed) and Embase (ScienceDirect) databases. Various combinations of the following keywords were used: (immediate implantation), (infection), (infected socket), (periapical lesion), (socket decontamination), (periodontitis), and (survival rate). After screening the titles and abstracts, full-text articles were selected for in-depth evaluation based on the inclusion criteria. The

### Risk of bias tools

The Newcastle-Ottawa scale was employed to assess both prospective and retrospective cohort studies. For the selected randomized controlled trials (RCTs), the Cochrane Risk of Bias Assessment Tool version 2 (RoB 2) was utilized. Using this standardized tool, potential systematic errors in the included studies were evaluated, considering factors such as random sequence generation, group allocation, deviations from the intended intervention, missing data, outcome measurement bias, selective reporting, and other possible sources of bias.



**Figure 1.** Prisma flow diagram

## Results and Discussion

### Study selection

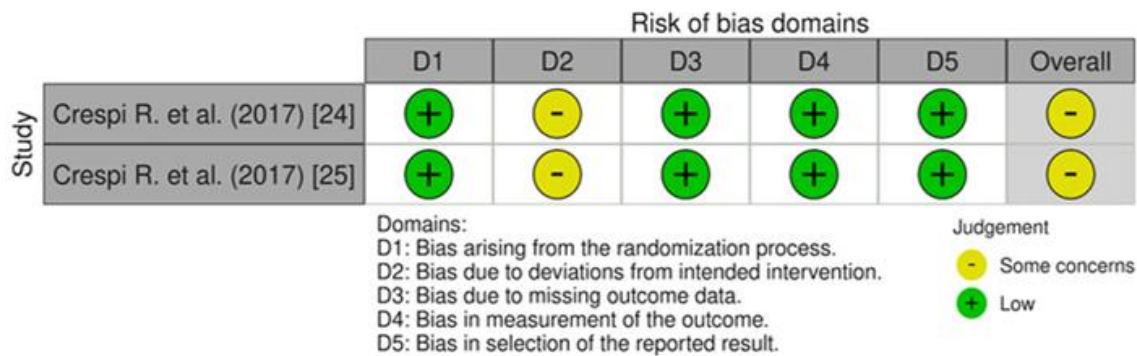
A PRISMA flow diagram (**Figure 1**) illustrates the process of reviewing articles, abstracts, and full-text publications. The initial search, using various keyword combinations, resulted in 368 titles. After removing duplicates, 292 records remained. From these, 278 were excluded based on the inclusion criteria (such as meta-analyses, systematic reviews, insufficient data, case reports, animal studies, and publications older than 12 years), leaving 14 publications for full-text review. Ultimately, 7 studies were included in the analysis. Of these, 5 were cohort studies, and 2 were

randomized clinical trials. Due to significant data heterogeneity, none of the studies were suitable for quantitative meta-analysis.

### Patient's data

The ages of patients in the studies ranged from 41.9 to 56.3 years. A total of 259 patients and 663 implants were assessed across the 7 studies included in this review. In the test groups, all patients had teeth with one of the following conditions: periapical pathology, asymptomatic periodontitis, granulation tissue, or infection in the apical area of the socket following extractions. The control groups in all studies consisted of patients with teeth extracted due to fractures, trauma,

or advanced caries, with no periapical pathology present.



**Figure 2.** Randomized clinical studies quality evaluation (RoB 2 tool).

### Quality evaluation

The results of the risk of bias assessment for the RCT and cohort studies are presented in **Figure 2** and **Table**

1, respectively. The randomization process in the two RCTs [24, 25] included in this review did not show a significant risk of bias. All 5 cohort studies [26-30] demonstrated high analytical quality.

**Table 1.** Quality assessment using the Newcastle-Ottawa scale of included cohort studies in a systematic review

Study	Selection				Comparability (**)	Outcomes			Total score out of 9
	Representativeness of the exposed cohort(*)	Selection of the non-exposed cohort (*)	Ascertainment of exposure(*)	Outcome not present at the start of the study (*)		Assessment of outcome (*)	Length of follow-up (*)	Adequacy of follow-up (*)	
Montoya-Salazar <i>et al.</i> [26]	*		*	*	*	*	*	*	7
Katyayan <i>et al.</i> [27]	*		*	*	*	*	*	*	7
Al Nashar <i>et al.</i> [28]	*		*	*	**	*	*	*	8
Fugazzotto <i>et al.</i> [29]	*		*	*	*	*	*	*	7
Jung <i>et al.</i> [30]	*		*	*	**	*	*	*	8

### Treatment outcomes

The findings from the evaluated studies are summarized in **Table 2**. The implant survival rates in the included trials ranged from 94.4% to 100%. Both clinical and radiographic assessments were conducted to verify the absence of infection.

In the randomized controlled trial by Crespi *et al.* [24], following tooth extraction, the sockets were randomly assigned to two groups: the test group (TG), where granulomatous tissue was removed and rinsed with a physiological solution, and the control group (CG), where granulomatous tissue was left in place. Follow-up appointments were scheduled by the surgeon and dental hygienist at 2 months and every six months after implant placement. Immediate implant placement occurred in 372 cases following tooth extraction. After 2 months of follow-up, 2 implants in the TG and 3 in the CG were removed. The overall implant survival

rate was 98.66% (98.92% for TG and 98.39% for the control group). This rate remained consistent after 3 years, with no statistically important differences in clinical outcomes or marginal bone level changes between the two groups ( $P > 0.05$ ). Additionally, no significant intragroup changes were observed over time ( $P > 0.05$ ).

In terms of other outcomes, 3 patients in the control group experienced pain, and two had edema at the implant site during the first three months. No statistically important differences were found between the TG and CG regarding bleeding index ( $P > 0.05$ ;  $P = 0.37$  at 36 months) and plaque accumulation ( $P > 0.05$ ;  $P = 0.54$  at 36 months).

Montoya-Salazar *et al.* incorporated laser treatment into their disinfection protocol. A total of 36 implants were placed, with 18 in non-infected sockets (control group) and 18 in infected alveoli (test group), all of which underwent debridement, mechanical cleaning,

hydrogen peroxide rinsing (90%), yttrium-scandium-gallium-garnet (Er, Cr: YSGG) laser irradiation, and a final wash with a sterile solution. 3 months post-operation, all implants had successfully osseointegrated. The 3-year implant survival rate was 100% for TG, compared to 94.44% for CG.

In the study by Fugazzotto *et al.* [29], 64 implants were placed in the TG after debridement. Similarly, 64 implants were immediately inserted in the CG following the extraction of a maxillary incisor, with no

periapical pathology present. Molt and Gracey's curettes were used to remove the remaining soft tissue and periapical tumor. The survival rates for implants placed in sites with periapical pathology and those placed in sites without periapical pathology were 98.1% and 98.2%, respectively.

Four studies—by Crespi *et al.* [25], Katyayan *et al.* [27], Al Nashar *et al.* [28], and Jung *et al.* [30]—reported a 100% implant survival rate in both the control and test groups.

**Table 2.** Evaluated studies and implant survival rate

Name	Type	Number of patients, males (M), females (F)	Mean age (years)	Age range (years)	Number of implants	Follow-up (months)	Reason for extraction	Disinfection protocol in test groups	Survival rate	Drug therapy	Post-operative regime
Crespi <i>et al.</i> [24]	RCT	60 22 M 38 F	-	35-72	372	3 6 12 24 36	Periodontitis without symptoms	Curettage Rinsed with PSS Sequestrectomy (Er, Cr: YSGG laser)	98.66%	Amoxicillin 1000 mg an hour before surgery and x2 per day for 7 days	Chlorhexidine mouthwash x 2 per day for 15 days
Montoya-Salazar <i>et al.</i> [26]	Cohort	18 - -	-	18-50	36	12 24 36	Long-standing periapical lesions resulting from endodontic or endoperiodontal causes	Curettage 90% hydrogen peroxide Sequestrectomy (Er, Cr: YSGG laser)	94.44% for TG 100% for CG	Amoxicillin 1500 mg x3 per day for ten days/ Clindamycin 900 mg x3 per day for ten days (four days before surgery, six days after)	Chlorhexidine 0.12% mouthwash x2 per day for 14 days
Crespi <i>et al.</i> [25]	RCT	60 22 M 38 F	56.3 ± 12.1	32-67	60	6 12	Asymptomatic apical periodontitis	Curettage	100%	Amoxicillin 1000 mg an hour before surgery and x2 per day for seven days	-

Fugazzotto <i>et al.</i> [29]	Jung <i>et al.</i> [30]	Al Nashar <i>et al.</i> [28]	Khan Katayyan <i>et al.</i> [27]
Cohort 64 23 M 41 F 46.0 21-71 148 3 7	Cohort 27 - 53.0 test group 60.0 control group 28-87 27 12 60	Cohort 15 7 M 8 F - 30-55 30 3 6 12	Cohort 15 11 M 4 F 41.9 28-54 20 12 24
Periapical pathology Granulation tissue in the apical area of the tooth	Periapical pathologies periapical Radiolucencies > 1 mm Suppuration	Chronic periodontitis	Chronic periapical lesions Root caries Root fracture
Curettage 98.1% TG 98.2% CG Amoxicillin 500 mg x 3 per day for 10 days/Clindamycin 300 mg x 2 per day for 10 days Etodolac 400 mg x 3 per day for 5 days Oxycodone/ acetaminophen 1 tab every 4 to 6 h. according to the need	Curettage 100% Amoxicillin 750 mg x3 per day for 5 days	Curettage 100% Clindamycin 600 mg hour before surgery Clindamycin 300 mg x4 per day for five days Ibuprofen 600 mg x2 per day for 7 to 10 days Extraoral ice packs for 2 h; warm chlorhexidine 0.2% HCl mouthwash x2 per day for 7 days; soft brush	Curettage Rinsed with 0.2% CHX, PSS 100% Amoxicillin 1000 mg an hour before surgery Amoxicillin 500 mg x3 per day for five days Chlorhexidine 0.2% mouthwash x2 per day for 15 days

In a double-blind, randomized clinical trial, Crespi *et al.* assigned participants to two groups: group A,

consisting of thirty teeth, received soft tissue debridement before implant placement; group B, also



with 30 teeth, had soft tissue debridement with the reactive tissue left in the apical lesion. Although no statistically significant differences were found in basal bone levels or between the groups, all fresh sockets in both groups experienced buccal-palatal bone loss after 1 year [31]. In group B, a 100% survival rate and a mean implant stability quotient of 65 were observed, with no significant differences between groups ( $P > 0.05$ ). Three participants in group B reported edema and 3 noted discomfort at the implant site, while no issues such as soreness or discomfort were reported in group A.

Katyayan *et al.* followed a disinfection protocol that included rinsing with 0.2% chlorhexidine, curettage of infected sockets, and rinsing with a physiological solution. During follow-up, no pain, implant mobility, flap dehiscence, suppuration, or radiolucency around the implants was observed.

In the study by Al Nashar *et al.* [28], each participant received 2 implants near their lateral mandibular incisors. One implant was treated with platelet-rich growth factors (PRGFs) (group I), while the other served as a placebo (group II). Each cohort received 15 immediate implants. After carefully removing granulation and fibrous tissue from the extraction sites, both groups were irrigated with sterile saline. PRGFs were gently and slowly injected into the drilled sites at the test locations before implant placement, and the PRGFs were also applied directly to the implant before seating.

Before implant placement, Jung *et al.* [30] ensured the removal of all granulation tissues. The study included 27 patients, with 15 in the control group, who had no periapical diseases, and twelve in the test group, who had periapical pathologies. All participants underwent guided bone regeneration (GBR).

The primary aim of this extensive review was to assess the impact of various disinfection protocols on the survival rate of implants placed immediately. The objective of immediate implantation surgery is to maintain the integrity of both the hard and soft tissues to ensure optimal implant stability and precise three-dimensional positioning. To achieve this, various surgical protocols are employed. Eini *et al.* [32] emphasize the strict requirements for immediate loading to prevent failure of osseointegration, such as applying the correct insertion force for primary stability, selecting the appropriate implant length, and ensuring there are no local or systemic contraindications.

Crespi *et al.* [33] suggest that both the endo-periodontal origin of infection and its association with anaerobic bacteria typically found in infected root

canals (including *Fusobacterium*, *Porphyromonas*, *Prevotella*, *Streptococcus*, *Actinomyces*, and *Peptostreptococcus*) may play a role in the high success rates of immediate implants placed in sockets affected by chronic conditions [33, 34]. The modifications in the anaerobic environment following socket extraction and curettage are thought to help eliminate the bacteria linked to the endo-periodontal infection [33]. Nevertheless, similar to other studies [17, 18, 21], our findings indicate that immediate implants can be successfully placed into debrided infected dentoalveolar sockets when performed under controlled conditions. Based on the findings of this systematic review, the most critical factor for successful integration of an implant in an infected site is thorough curettage.

Some researchers incorporate additional strategies to enhance disinfection and improve implantation outcomes. Kakar *et al.* utilized a hardening bone graft replacement to address peri-implant defects in all participants. The socket was also treated and decontaminated using an Er, Cr: YSGG laser (Waterlase MD, Biolase Technology, Irvine, CA) equipped with an MZ-4 (14 millimeters) radial-firing point. The implant survival rate reached 95.45%, with only five implants removed and recorded as failures [17]. Chrcanovic *et al.* [35] acknowledged that although laser therapy can be effective in debriding infected sockets before implantation, as evidenced by the reduction in bacteria reported by Kusek [36], the number of patients involved ( $n = 10$ ) in studies is limited. In contrast, Kakar *et al.* [17] supported the efficacy of laser treatment after carrying out a larger-scale study ( $n = 68$ ). Montoya-Salazar *et al.* also incorporated laser treatment as an additional measure. In their protocol, infected sites in the TG were irradiated with an Er, Cr: YSGG laser. No significant difference in survival rates was observed between the two groups ( $P = 0.720$ ). 1 implant failure in the test group was attributed to the patient's poor hygiene and lack of cooperation [26]. The selection of the Er, Cr: YSGG laser, with a wavelength of 2780 nanometers, was due to its ability to remove compromised tissues with minimal thermal side effects and little to no damage to surrounding areas [37, 38]. This laser is highly effective in decontaminating, reducing harmful bacteria by 98%, which shortens healing time and reduces the risk of post-operative infection [39]. The water/air mist emitted by the Er, Cr: YSGG laser also cools and alleviates pain, reducing the sensation of tissue burning or charring [40, 41]. The outcomes of laser therapy are comparable to the established success

rates for immediate implantation in non-infected sites [17, 42].

It is essential to highlight that PRGF was applied in only one study [28]. When used in conjunction with immediate implantation, PRGF can help treat extracted sockets and reduce the risk of infection. PRGF, when integrated with the bone, serves as an osteoconductive, autologous bone graft filling the space between the implant surface and the socket walls [43, 44]. In immediate implant placements, platelet-derived growth factors might effectively promote soft tissue regeneration and reduce inflammation and pain [45, 46]. The study by Al Nashar *et al.* [28] showed a 100% survival rate in both groups, with group I receiving implants treated with PRGFs and group II not receiving treatment. Osseointegration was achieved for all implants, and there was no significant difference between the treated and untreated groups [28]. On the other hand, Pal *et al.* [47] concluded that using 2 doses of PRGF for immediate implants in compromised sockets results in superior outcomes and a successful rehabilitation method. Furthermore, Del Fabbro *et al.* [20] examined the impact of immediate implants in fresh extraction sockets of teeth affected by periapical lesions and found PRGF to be an effective and safe adjunct to the rehabilitation process.

Several researchers have incorporated guided bone regeneration (GBR) with autologous bone or allograft that may enhance the chances of successful osteointegration of implants [29, 30]. AlKudmani *et al.* [48] found that combining buccal gap bone grafting with immediate implantation helps maintain the proportions of both hard and soft tissues, contributing to the implant's long-term stability. This approach offers significant advantages in ensuring the implant's durability. Jung *et al.* [49] discovered that implants placed simultaneously with GBR, whether using resorbable or non-resorbable membranes, achieve high survival rates ranging from 91.9% to 92.6%, thus confirming the procedure's safety and predictability. However, bone regeneration primarily aids in reducing the likelihood of resorption and does not address the presence of residual bacteria in post-extraction sites, though it can still be applied to infected sockets. According to Said [50], in cases of chronic periapical lesions in the posterior maxilla with a history of endodontic failure, immediate implant insertion combined with guided bone regeneration may be an appropriate solution for replacing missing teeth.

It is crucial to consider that various medications used for prevention or treatment post-surgery can influence the success of implant procedures. Prophylactic antibiotic therapy was employed in five out of seven of

the studies included in this review, while all studies prescribed post-operative antibiotics. However, none of the studies mentioned the use of local antibiotics during the surgical procedure. In the research by Passarelli *et al.* [51], a thorough analysis found no significant advantage of local/topical antibiotics over mechanical debridement, scaling, root planning, or a placebo ointment. To avoid overstating the effectiveness of local antibiotics, only randomized controlled trials (RCTs) were included in this review. Romandini *et al.*'s [52] meta-analysis concluded that all prophylactic antibiotic regimens had a more substantial effect in reducing implant failures compared to a placebo or no antibiotics. Nonetheless, when used alone, antibiotic prophylaxis did not show a statistically important positive outcome, and the results must be interpreted with caution in this meta-analysis. For individuals without penicillin allergies, amoxicillin was the most commonly recommended antibiotic, although clindamycin was used by one researcher [28]. A 2-3g dose of amoxicillin administered orally 1 hour before surgery significantly reduces the likelihood of implant failure [53]. According to Momand *et al.* [15], antibiotic prophylaxis appears to offer minimal benefit when combined with implantation. Zhurakivska *et al.* [54] noted that antibiotic prophylaxis could improve implant success and short-term survival rates. However, a sub-analysis of major trials indicates that antibiotic prophylaxis provided little to no benefit in uncomplicated implantation in healthy individuals [55]. In contrast, studies that did not use pre-operative antibiotics still reported success rates of 98.1-98.2% [29] and 100% [30]. Post-operative antibiotics are valuable for preventing infections after implant placement [56].

In 5 out of 7 studies, a 0.12-0.2% chlorhexidine mouthwash was included as part of the post-operative care. Following a surgical procedure like immediate implant placement, the ability to control plaque mechanically is limited, so antimicrobial methods are frequently employed. Chlorhexidine has been shown to penetrate biofilms, disrupt biofilm formation, and exhibit a direct bactericidal effect [57, 58]. However, chlorhexidine can alter the surface structure of dental implants and induce cytotoxicity in cells, which may hinder re-osseointegration and even lead to implant failure. Therefore, its use during implant placement remains a subject of debate [59, 60].

## Conclusion

The analysis of the studies indicates that various strategies can enhance the likelihood of successful implant integration. However, without thorough



curettage of the alveolar socket, additional disinfection techniques are ineffective. Both pre-operative and post-operative antibiotic treatments are critical for achieving predictable implant survival rates in immediate implant placements. In contrast, the use of local antibiotics is neither necessary nor beneficial in improving implant survival. An effective alternative includes the use of the Er, Cr: YSGG laser, which, with its water/air mist, effectively cleans infected sockets while minimizing the risk of bone overheating due to its cooling features. PRGF, with its osteoconductive properties, accelerates the healing of the alveolar socket and aids in implant integration, making it an excellent tool for improving survival rates in immediate implantations of compromised sockets. However, a reliable comparison between disinfection methods is not possible due to the lack of sufficient data and variability in the existing studies. To determine the most effective protocol for immediate implant placement in infected sockets, more rigorous and standardized clinical studies are necessary.

**Acknowledgments:** The authors acknowledge the statistical support provided by the Lithuanian University of Health Sciences.

**Conflict of Interest:** None

**Financial Support:** None

**Ethics Statement:** None

## References

1. Brånemark PI, Hansson BO, Adell R, Breine U, Lindström J, Hallen O, et al. Osseointegrated implants in the treatment of the edentulous jaw. Experience from 10 years. *Scand J Plast Reconstr Surg Suppl.* 1977;16:1-132.
2. Bertl K, Kukla EB, Albugami R, Beck F, Gahleitner A, Stavropoulos A. Timeframe of socket cortication after tooth extraction: A retrospective radiographic study. *Clin Oral Implants Res.* 2018;29(1):130-8. doi:10.1111/clr.13081
3. Avila-Ortiz G, Chambrone L, Vignoletti F. Effect of alveolar ridge preservation interventions following tooth extraction: A systematic review and meta-analysis. *J Clin Periodontol.* 2019;46(Suppl. 21):195- 223.
4. Bassir SH, El Kholy K, Chen CY, Lee KH, Intini G. Outcome of early dental implant placement versus other dental implant placement protocols: A systematic review and meta-analysis. *J Periodontol.* 2019;90(5):493-506. doi:10.1002/JPER.18-0338
5. Cosyn J, De Lat L, Seyssens L, Doornewaard R, Deschepper E, Vervaeke S. The effectiveness of immediate implant placement for single tooth replacement compared to delayed implant placement: A systematic review and meta-analysis. *J Clin Periodontol.* 2019;46(Suppl. 21):224-41. doi:10.1111/jcpe.13054
6. dos Santos Canellas JV, Medeiros PJ, da Silva Figueredo CM, Fischer RG, Ritto FG. Which is the best choice after tooth extraction, immediate implant placement or delayed placement with alveolar ridge preservation? A systematic review and meta-analysis. *J Cranio-Maxillofac Surg.* 2019;47(11):1793-802. doi:10.1016/j.jcms.2019.08.004
7. Saijeva A, Juodzbalsys G. Immediate Implant Placement in Non-Infected Sockets versus Infected Sockets: a Systematic Review and Meta-Analysis. *J Oral Maxillofac Res.* 2020;11(2):e1. doi:10.5037/jomr.2020.11201
8. Lee J, Kim S, Koo KT, Seol YJ, Cho HJ, Lee YM. Histologic Analyses of Immediate Implant Placement in Infected and Noninfected Sockets: An Experimental Pilot Study in Beagle Dogs. *Int J Oral Maxillofac Implants.* 2019;34(3):575-84. doi:10.11607/jomi.7075
9. Salomó-Coll O, de Maté-Sánchez JV, Ramírez-Fernandez MP, Hernández-Alfaro F, Gargallo-Albiol J, Calvo-Guirado JL. Osseointductive elements around immediate implants for better osteointegration: a pilot study in foxhound dogs. *Clin Oral Implants Res.* 2018;29(11):1061-9.
10. Hadaya D, Pi-Anfruns J, Bellon B, Pippenger BE, Aghaloo TL. Immediate loading of a fully tapered implant with deep apical threads placed in healed alveolar ridges vs. immediate extraction sockets. *Clin Oral Implants Res.* 2022;33(5):501-10. doi:10.1111/clr.13910
11. Blanco J, Carral C, Argibay O, Liñares A. Implant placement in fresh extraction sockets. *Periodontol* 2000. 2019;79(1):151-67. doi:10.1111/prd.12253
12. Salgado-Peralvo AO, Peña-Cardelles JF, Kewalramani N, Mateos-Moreno MV, Jiménez-Guerra Á, Velasco-Ortega E, et al. Preventive antibiotic therapy in the placement of immediate implants: A systematic review. *Antibiotics.* 2021;11(1):5. doi:10.3390/antibiotics11010005
13. Jain A, Rai A, Singh A, Taneja S. Efficacy of preoperative antibiotics in prevention of dental implant failure: a Meta-analysis of randomized controlled trials. *Oral Maxillofac Surg.*

- 2020;24:469-75. doi:10.1007/s10006-020-00872-5
14. Hollingshead CM, Brizuela M. Antibiotic Prophylaxis In Dental and Oral Surgery Practice. [Updated 2023 Mar 19]. In: StatPearls [Internet]. Treasure Island (FL): StatPearls Publishing; 2023 Jan-.
15. Momand P, Becktor JP, Naimi-Akbar A, Tobin G, Götrick B. Effect of antibiotic prophylaxis in dental implant surgery: A multicenter placebo-controlled double-blinded randomized clinical trial. *Clin Implant Dent Relat Res.* 2022;24(1):116-24. doi:10.1111/cid.13068
16. Klinge B, Flemming T, Cosyn J, De Bruyn H, Eisner BM, Hultin M, et al. The patient undergoing implant therapy. Summary and consensus statements. The 4th EAO Consensus Conference 2015. *Clin Oral Implants Res.* 2015;26 Suppl 11:64-7. doi:10.1111/clr.12675
17. Kakar A, Kakar K, Leventis MD, Jain G. Immediate Implant Placement in Infected Sockets: A Consecutive Cohort Study. *J Lasers Med Sci.* 2020;11(2):167-73. doi:10.34172/jlms.2020.28
18. Novaes AB Jr, Novaes AB. Immediate implants placed into infected sites: a clinical report. *Int J Oral Maxillofac Implants.* 1995;10(5):609.
19. Alrakkad IA, Alrakkad RA, Altamimi MS, Alshammari NM, Alghuraymil AA, John MA, et al. Review on Dental Implant and Infection Management Approach. *Arch Pharm Pract.* 2022;13(1):37-9.
20. Del Fabbro M, Boggian C, Taschieri S. Immediate implant placement into fresh extraction sites with chronic periapical pathologic features combined with plasma rich in growth factors: preliminary results of a single-cohort study. *J Oral Maxillofac Surg.* 2009;67(11):2476-84.
21. Garcés Villalá MA, Rico Jordán SD, Calvo Guirado JL. Immediate Implant Placement in Infected Sockets: Curettage Protocol Plus Disinfection with Hydrogen Peroxide and Rifamycin. Retrospective Analysis at 6 years of Follow-up. *Open Access J Dent Oral Surg.* 2022;3:1035.
22. Yamany IA. The Employment of CBCT in Assessing Bone Loss around Dental Implants in Patients Receiving Mandibular Implant Supported over dentures. *Int J Pharm Res Allied Sci.* 2019;8(3):9-16.
23. Methley AM, Campbell S, Chew-Graham C, McNally R, Cheraghi-Sohi S. PICO, PICOS and SPIDER: a comparison study of specificity and sensitivity in three search tools for qualitative systematic reviews. *BMC Health Serv Res.* 2014;14(1):579. doi:10.1186/s12913-014-0579-0
24. Crespi R, Capparé P, Crespi G, Lo Giudice G, Gastaldi G, Gherlone E. Dental Implants Placed in Periodontally Infected Sites in Humans. *Clin Implant Dent Relat Res.* 2017;19(1):131-9. doi:10.1111/cid.12425
25. Crespi R, Capparé P, Crespi G, Lo Giudice G, Gastaldi G, Gherlone E. Immediate Implant Placement in Sockets with Asymptomatic Apical Periodontitis. *Clin Implant Dent Relat Res.* 2017;19(1):20-7. doi:10.1111/cid.12422
26. Montoya-Salazar V, Castillo-Oyagüe R, Torres-Sánchez C, Lynch CD, Gutiérrez-Pérez JL, Torres-Lagares D. Outcome of single immediate implants placed in post-extraction infected and non-infected sites, restored with cemented crowns: a 3-year prospective study. *J Dent.* 2014;42(6):645-52. doi:10.1016/j.jdent.2014.03.008
27. Katyayan MK, Katyayan PA, Reddy PS, Kumar YB. A comparison of outcome of the immediate implant placement of implants when used in the replacement of teeth with and without chronic periapical lesions: outcome of the immediate implant placement of implants in case with and without chronic periapical lesions. *Natl J Integr Res Med.* 2018;8(2):133-9. Available from: <http://nicpd.ac.in/ojs-/index.php/njirm/article/view/1221>
28. Al Nashar A, Yakoob H. Evaluation of the use of plasma rich in growth factors with immediate implant placement in periodontally compromised extraction sites: a controlled prospective study. *Int J Oral Maxillofac Surg.* 2015;44(4):507-12. doi:10.1016/j.ijom.2014.12.001
29. Fugazzotto PA. A retrospective analysis of implants immediately placed in sites with and without periapical pathology in sixty-four patients. *J Periodontol.* 2012;83(2):182-6. doi:10.1902/jop.2011.110016
30. Jung RE, Zaugg B, Philipp AO, Truninger TC, Siegenthaler DW, Hämmerle CH. A prospective, controlled clinical trial evaluating the clinical radiological and aesthetic outcome after 5 years of immediately placed implants in sockets exhibiting periapical pathology. *Clin Oral Implants Res.* 2013;24(8):839-46. doi:10.1111/j.1600-0501.2012.02491.x
31. Ashurko I, Esayan A, Magdalyanova M, Tarasenko S. Current concepts of surgical methods to increase mucosal thickness during dental

- implantation. *J Adv Pharm Educ Res.* 2021;11(3):37-41.
32. Eini E, Yousefimanesh H, Ashtiani AH, Saki-Malehi A, Olapour A, Rahim F. Comparing success of immediate versus delay loading of implants in fresh sockets: a systematic review and meta-analysis. *Oral Maxillofac Surg.* 2022;26:185-94. doi:10.1007/s10006-021-00983-7
33. Crespi R, Capparè P, Gherlone E. Fresh-socket implants in periapical infected sites in humans. *J Periodontol.* 2010;81(3):378-83. doi:10.1902/jop.2009.0905052-
34. Siqueira Jr JF, Rôças IN. Present status and future directions: Microbiology of endodontic infections. *Int Endod J.* 2022;55(Suppl. 3):512-30. doi:10.1111/iej.13677
35. Chrcanovic BR, Martins MD, Wennerberg A. Immediate placement of implants into infected sites: a systematic review. *Clin Implant Dent Relat Res.* 2015;17(Suppl 1):e1-e16. doi:10.1111/cid.12098
36. Kusek ER. Immediate implant placement into infected sites: bacterial studies of the Hydroacoustic effects of the YSGG laser. *J Oral Implantol.* 2011;37(sp1):205-11. doi:10.1563/AAID-JOI-D-10-00014
37. Alhaidary D, Franzen R, Hilgers RD, Gutknecht N. First Investigation of Dual-Wavelength Lasers (2780 nm Er, Cr: YSGG and 940 nm Diode) on Implants in a Simulating Peri-Implantitis Situation Regarding Temperature Changes in an In Vitro Pocket Model. *Photobiomodul Photomed Laser Surg.* 2019;37(8):508-14. doi:10.1089/photob.2019.4650
38. Chegeni E, España-Tost A, Figueiredo R, Valmaseda-Castellón E, Arnabat-Domínguez J. Effect of an Er,Cr:YSGG Laser on the Surface of Implants: A Descriptive Comparative Study of 3 Different Tips and Pulse Energies. *Dent J (Basel).* 2020;8(4):109. doi:10.3390/dj8040109
39. Crippa R, Aiuto R, Dioguardi M, Nieri M, Peñarrocha-Diago M, Peñarrocha-Diago M, et al. Immediate dental implant placement in post-extraction-infected sites decontaminated with Er, Cr: YSGG laser: a retrospective cohort study. *Odontology.* 2023;111(1):255-62. doi:10.1007/s10266-022-00734-4
40. Crippa R, Aiuto R, Guardincerri M, Peñarrocha Diago M, Angiero F. Effect of laser radiation on infected sites for the immediate placement of dental implants. *Photobiomodul Photomed Laser Surg.* 2020;38(3):186-92. doi:10.1089/photob.2019.4636
41. Pourshahidi S, Ebrahimi H, Mansourian A, Mousavi Y, Kharazifard M. Comparison of Er,Cr:YSGG and diode laser effects on dentin hypersensitivity: a split-mouth randomized clinical trial. *Clin Oral Investig.* 2019;23(11):4051-8. doi:10.1007/s00784-019-02841-z
42. Crippa R, Aiuto R, Dioguardi M, Peñarrocha-Diago M, Peñarrocha-Diago M, Angiero F. Laser Therapy for Infected Sites and Immediate Dental Implants in the Esthetic Zone: A Case Report and Review of Literature. *Case Rep Dent.* 2020;2020:2328398. doi:10.1155/2020/2328398
43. Stumbras A, Kuliesius P, Januzis G, Juodzbals G. Alveolar Ridge Preservation after Tooth Extraction Using Different Bone Graft Materials and Autologous Platelet Concentrates: a Systematic Review. *J Oral Maxillofac Res.* 2019;10(1):e2. doi:10.5037/jomr.2019.10102
44. Xu JL, Xia R. Efficacy of plasma rich in growth factor used for dry socket management: a systematic review. *Med Oral Patol Oral Cir Bucal.* 2019;24(6):e704-e11. doi:10.4317/medoral.23015
45. Dragonas P, Schiavo JH, Avila-Ortiz G, Palaiologou A, Katsaros T. Plasma rich in growth factors (PRGF) in intraoral bone grafting procedures: a systematic review. *J Cranio-Maxillofac Surg.* 2019;47(3):443-53. doi:10.1016/j.jcms.2019.01.012
46. Solakoglu Ö, Heydecke G, Amiri N, Anitua E. The use of plasma rich in growth factors (PRGF) in guided tissue regeneration and guided bone regeneration. A review of histological, immunohistochemical, histomorphometrical, radiological and clinical results in humans. *Ann Anat-Anat Anz.* 2020;231:151528. doi:10.1016/j.aanat.2020.151528
47. Pal US, Daga D, Singh RK, Kumar L, Singh M. Comparison of stability with two-time use of platelet-rich growth factor versus one-time use of platelet-rich growth factor in immediate placement of dental implant in infected socket. *Natl J Maxillofac Surg.* 2018;9(2):209-14. doi:10.4103/njms.NJMS\_1\_18
48. AlKudmani H, Jasser RA, Andreana S. Is bone graft or guided bone regeneration needed when placing immediate dental implants? A systematic review. *Implant Dent.* 2017;26(6):936-44. doi:10.1097/ID.0000000000000689
49. Jung RE, Fenner N, Hämmerle CH, Zitzmann NU. Long-term outcome of implants placed with

- guided bone regeneration (GBR) using resorbable and non-resorbable membranes after 12-14 years. Clin Oral Implants Res. 2013;24(10):1065-73. doi:10.1111/j.1600-0501.2012.02522.x
50. Said H. Post extraction immediate implant placement in infected extraction sockets of maxillary posterior teeth combined with guided bone regeneration. Two-year prospective clinical and radiographic outcomes. Egypt J Oral Maxillofac Surg. 2021;12(2):128-36. doi:10.21608/omx.2021.93989.1135
51. Passarelli PC, Netti A, Lopez MA, Giaquinto EF, De Rosa G, Aureli G, et al. Local/Topical Antibiotics for Peri-Implantitis Treatment: A Systematic Review. Antibiotics (Basel). 2021;10(11):1298. doi:10.3390/antibiotics10111298
52. Romandini M, De Tullio I, Congedi F, Kalemaj Z, D'Ambrosio M, Lafori A, et al. Antibiotic prophylaxis at dental implant placement: Which is the best protocol? A systematic review and network meta-analysis. J Clin Periodontol. 2019;46(3):382-95. doi:10.1111/jcpe.13080
53. Tan LW, Ng YE, Giok KC, Veettil SK, Menon RK. Comparative Efficacy of Different Amoxicillin Dosing Regimens in Preventing Early Implant Failure-A Systematic Review with Network Meta-Analysis. Antibiotics (Basel). 2023;12(3):512. doi:10.3390/antibiotics12030512
54. Zhurakivska K, Russo LL, Muzio LL, Caponio VCA, Laino L, Arena C, et al. Antibiotic prophylaxis at the time of dental implant placement: a cost-effectiveness analysis. BMC Health Serv Res. 2022;22(1):1073. doi:10.1186/s12913-022-08452-x
55. Park J, Tennant M, Walsh LJ, Kruger E. Is there a consensus on antibiotic usage for dental implant placement in healthy patients? Aust Dent J. 2018;63(1):25-33. doi:10.1111/adj.12535
56. Gross AE, Hanna D, Rowan SA, Bleasdale SC, Suda KJ. Successful Implementation of an Antibiotic Stewardship Program in an Academic Dental Practice. Open Forum Infect Dis. 2019;6(3):ofz067. doi:10.1093/ofid/ofz067
57. Solderer A, Kaufmann M, Hofer D, Wiedemeier D, Attin T, Schmidlin PR. Efficacy of chlorhexidine rinses after periodontal or implant surgery: a systematic review. Clin Oral Investig. 2019;23(1):21-32. doi:10.1007/s00784-
58. Brookes ZLS, Bescos R, Belfield LA, Ali K, Roberts A. Current uses of chlorhexidine for management of oral disease: a narrative review. J Dent. 2020;103:103497. doi:10.1016/j.jdent.2020.103497
59. Krishnamoorthy G, Narayana A, Balkrishnan D. Chlorhexidine for the Treatment of Peri-Implantitis: Is it a Benison? J Long Term Eff Med Implants. 2022;32(1):19-23. doi:10.1615/JLongTermEffMedImplants.2021039510
60. Liu S, Li M, Yu J. Does chlorhexidine improve outcomes in non-surgical management of peri-implant mucositis or peri-implantitis?: a systematic review and meta-analysis. Med Oral Patol Oral Cir Bucal. 2020;25(5):e608-e15. doi:10.4317/medoral.23633